

# Recurrent thoracic duplication cyst with associated mediastinal gas

Hammad Al-Sadoon MD, Nathan Wiseman MD, Victor Chernick MD  
*Department of Pediatrics, Health Sciences Centre and The University of Manitoba,  
Winnipeg, Manitoba*

H Al-Sadoon, N Wiseman, V Chernick. Recurrent thoracic duplication cyst with associated mediastinal gas. *Can Respir J* 1998;5(2):149-151.

Mediastinal cysts are not uncommon in the pediatric age group. Presentation varies from an abnormality found on routine chest radiograph to severe respiratory distress and even respiratory failure. Presentation depends on the age of the patient, the location of the lesion, the extent and the size of the mass, and what structures are involved. The case of a six-year-old boy who presented with recurrence of a mediastinal mass associated with gas two years after surgical removal of an infected esophageal duplication cyst is described. No connection between the cyst and the esophagus to explain the presence of gas was documented. This appears to be the first reported case of esophageal duplication cyst associated with mediastinal gas.

**Key Words:** *Children, Mediastinal cysts*

## Kyste de duplication thoracique récidivant associé à la présence d'air dans le médiastin

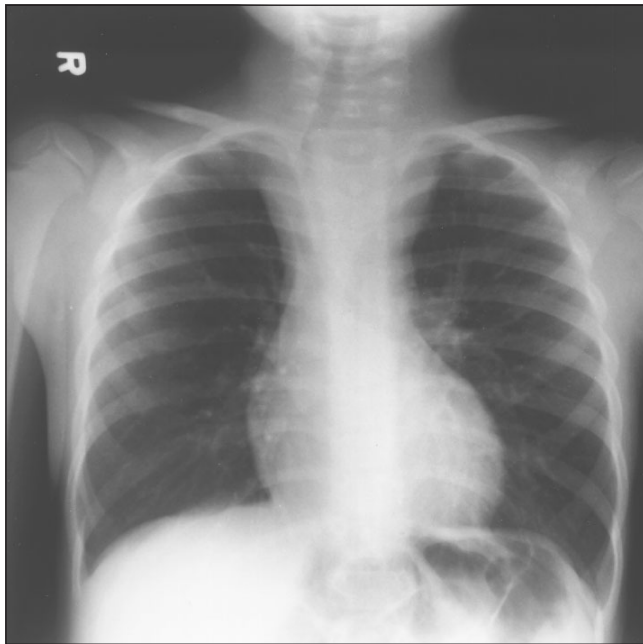
**RÉSUMÉ :** Les kystes médiastinaux ne sont pas rares chez l'enfant. Ils sont découverts lors d'une radiographie thoracique systématique mais aussi à cause d'une grave détresse respiratoire voire d'une insuffisance respiratoire. Leur mode de présentation dépend de l'âge du patient, du site de la lésion, de l'étendue et de la taille de la masse, et des structures qui sont touchées. Le cas d'un garçon de six ans qui s'est présenté avec une masse médiastinale récidivante avec présence d'air deux ans après une excision chirurgicale d'un kyste de duplication œsophagien infecté est décrit. Aucun lien entre le kyste et l'œsophage n'a été documenté pour expliquer la présence d'air. Ce cas semble être le premier cas rapporté de kyste de duplication œsophagien associé à la présence d'air dans le médiastin.

Duplication cysts usually occur in the posterior mediastinum, and may be associated with anomalies of the lower cervical and upper thoracic vertebrae, such as hemivertebrae, spina bifida and scoliosis (1,2). Symptoms are usually related to bronchial compression, and the patient may present with persistent cough, respiratory distress, wheeze or stridor (1). Occasionally presenting symptoms may be related to compression of the esophagus, which causes dysphagia (3). The age at time of diagnosis ranges from the neonatal period up to age 10 years (1,3,4). The preferred treatment is complete surgical excision through a thoracotomy (1). We report a novel case of esophageal duplication cyst associated with persistent gas inside the cyst and hemiparesis of unknown etiology.

## CASE PRESENTATION

A four-year-old boy developed cough and fever followed by respiratory distress, which progressed over few days to severe respiratory failure requiring admission to the pediatric intensive care unit of the Winnipeg Children's Hospital in June 1994. He was found to have a mediastinal mass on chest radiograph (Figure 1) that was further delineated by an esophagogram and chest computed tomography (CT) scan (Figure 2). The mass was compressing the trachea and accounted for the severe respiratory distress and carbon dioxide retention. He was operated on within three days of admission and found to have an infected duplication cyst that was drained and excised. Microscopic examination of the cyst showed

Correspondence and reprints: Dr Victor Chernick, Professor of Pediatrics, Winnipeg Children's Hospital, Room CS 514, 840 Sherbrook Street, Winnipeg, Manitoba R3A 1S1. Telephone 204-787-1380, fax 204-787-1944



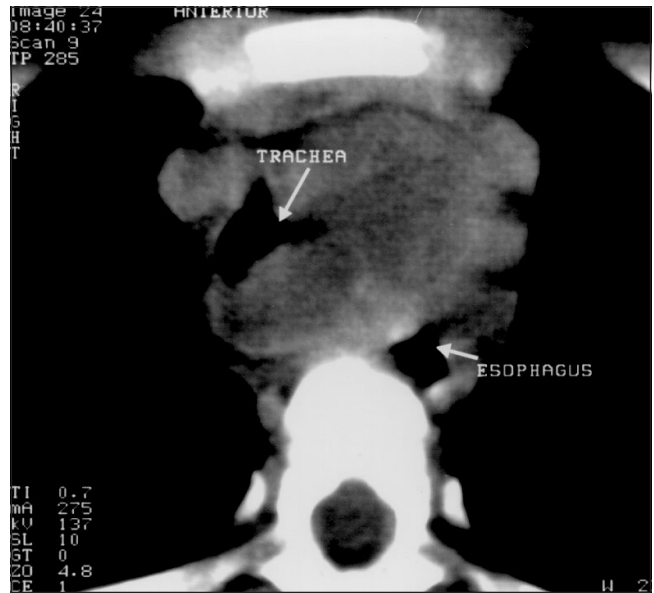
**Figure 1)** Chest radiograph on initial presentation of the patient. Note the large mediastinal mass, with deviation of the trachea to the right as well as deviation of the esophagus to the left

stratified squamous epithelium, and the lumen contained a large number of polymorphonuclear cells. Culture from the purulent cyst fluid grew *Bacteroides fragilis*. Postoperatively he was treated with cefoxitin and gentamycin. He recovered uneventfully from the surgery and was discharged home after five days.

Before this presentation there was a history of noisy breathing with colds. He also had a mild right hemiparesis that was noted at about age one year when he started walking, but which had remained stable since that time with no progression. The etiology of the hemiparesis remained obscure, and no further investigations, such as imaging of the brain or spinal cord, were completed. Intellectual function was normal. There was no history of foreign body aspiration or ingestion, and no history of trauma to the chest. He was born at full term with normal spontaneous vaginal delivery, and Apgar score was three and nine at 1 and 5 mins, respectively. He had jitteriness noted after birth, which was attributed to withdrawal symptoms secondary to the anticonvulsive medication that the mother was taking during pregnancy; blood glucose concentration was normal.

Two years later (June 1996) at age six years he again presented at the Winnipeg Children's Hospital with a six-month history of shortness of breath with exercise, resolving without treatment after 30 mins of rest. There was no history of wheeze or nocturnal cough. Physical examination was normal except for mild right-sided weakness.

Pulmonary function tests were completed and were normal, with no evidence of airway obstruction: forced vital capacity (FVC) 1.56 L (89% predicted), forced expiratory volume in 1 s (FEV<sub>1</sub>) 1.41 L (89% predicted), FEV<sub>1</sub>/FVC 90%, forced expiratory flow 25% to 75% 1.73 L/s (87% predicted). Because of the history of the excised mediastinal du-



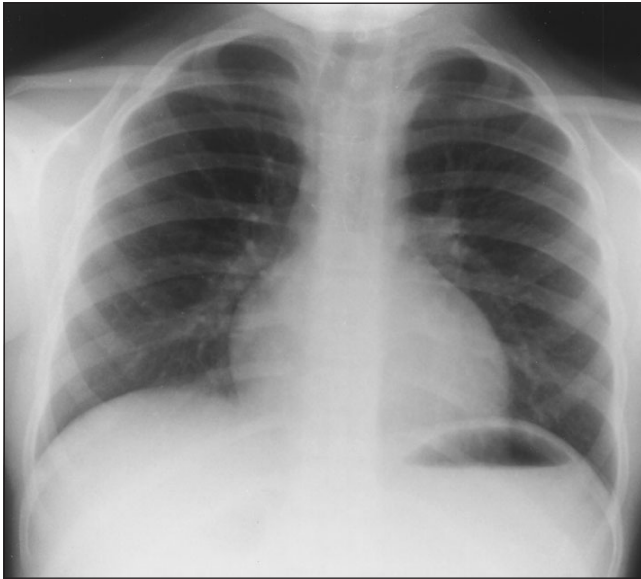
**Figure 2)** Computed tomography scan of the chest on the initial presentation. There is a large mass located in the superior mediastinum, anterior to the spine, which crosses the midline. The trachea is displaced to the right and compressed. The esophagus is displaced to the left

plication cyst two years previously, a chest radiograph was completed that showed a superior mediastinal mass with lateral deviation and compression of the trachea to the right (Figure 3). A chest CT scan showed a soft tissue density situated between the esophagus and trachea at the thoracic inlet, similar to that noted two years earlier. In addition, a small amount of gas was seen in the mediastinum that had not been present on the earlier CT scans (Figure 4). A gastrografin swallow followed by a barium swallow in the supine position did not demonstrate any leak from the esophagus into the cyst.

A 6 min run at 6 km/h was completed at a grade of 12°, and no fall in FEV<sub>1</sub> dyspnea, wheeze or stridor was detected. Because he was now asymptomatic, no further therapy was undertaken. At follow-up five months later (October 1996), he denied any further symptoms, and chest radiograph revealed slight deviation of the trachea to the right and minimal soft tissue density in the superior mediastinum but no gas evident. The patient has remained asymptomatic, and no further clinical or radiological studies have been completed.

## DISCUSSION

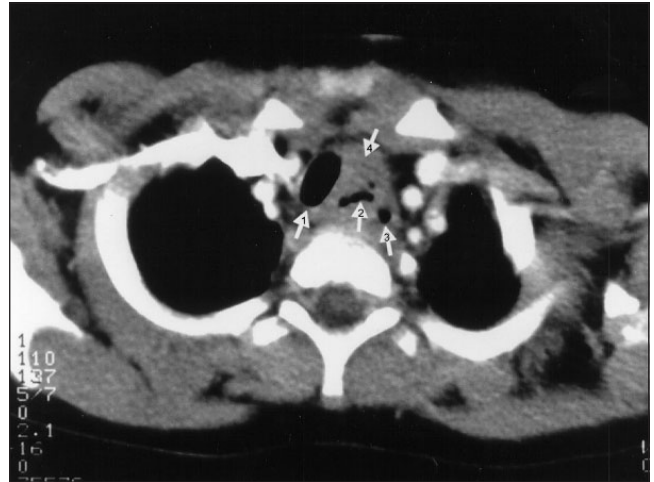
The nomenclature of duplication cysts of the gastrointestinal tract remain confusing with various terms used, such as enteric, enterogenous, and gastroenteric cyst or enterocystoma (2). In studying mediastinal cysts Pokorny and Sherman (6) and Snyder et al (7) reported that bronchogenic cysts were more common than esophageal duplication cysts. In contrast, Haller et al (8) found that esophageal duplication cysts were more common than bronchogenic cysts. In any case, the appropriate management of these benign cysts is surgical excision. Symptomatology depends on the degree of compression of neighbouring structures by the mass and can



**Figure 3)** Chest radiograph two years postoperation. Notice the reduction in the size of the mass. The trachea is still deviated to the right

range from no symptoms to severe respiratory distress, stridor, wheezing, dysphagia, vomiting and regurgitation. Chest pain may be reported by older children. Age at the time of presentation varies. Symptoms may start as early as the newborn period (3,4,7) or may be delayed until adulthood (5,9), but most esophageal duplication cysts are discovered in childhood. Vertebral anomalies may be associated with duplication cysts, especially those in the posterior mediastinum (1,2,10). Mediastinal masses may also present as diagnostic dilemmas, and operation may be delayed (7) unless there is high index of suspicion.

In our case a four-year-old child presented with severe respiratory distress secondary to an esophageal duplication cyst. What is puzzling and novel is the recurrence of the mass and the presence of mediastinal gas two years after surgical excision. Radiological studies did not demonstrate an esophageal leak that would explain the presence of gas. Stringel et al (11) reported esophageal duplication cyst containing a



**Figure 4)** Computed tomography scan of the chest two years post-operation. Trachea is displaced but less so than on the previous examination, and there is no significant tracheal compression. Notice the persisting abnormal soft tissue density situated between the esophagus and trachea at the thoracic inlet. Small amount of air is noticeable just outside the lumen of the esophagus. 1 Trachea, 2 Mediastinal air, 3 Esophagus, 4 Mediastinal mass

foreign body, demonstrated by CT scan of the chest, and found the foreign body to be a bingo chip at time of operation. They could not demonstrate a communication between the cyst and the esophagus by barium esophagography or at time of surgery. Obviously, a communication between the esophagus and the cyst must have existed at some stage and presumably closed spontaneously. In our case, although there was no foreign body, the situation may be similar in that gas entered the cyst. Another possible explanation is that the gas was introduced at the time of the initial surgery.

Although thought to have been completely excised during the original operation, some remnant of the cyst may have remained, and this could explain the recurrence of the mediastinal mass. To our knowledge, this is the first reported case of recurrent esophageal duplication cyst in association with mediastinal gas.

## REFERENCES

1. Simpson I, Campbell PE. Mediastinal masses in childhood: A review from a pediatric pathologist's point of view. *Prog Pediatr Surg* 1991;27:92-126.
2. Fallon M, Gordon ARG, Lendrum AC. Mediastinal cysts of fore-gut origin associated with vertebral abnormalities. *Br J Surg* 1953;41:520-32.
3. Stewart RJ, Bruce J, Beasley SW. Oesophageal duplication cysts: Another cause of neonatal respiratory distress. *J Paediatr Child Health* 1993;29:391-2.
4. Burgner DP, Carachir R, Beattie TJ. Foregut duplication cyst presenting as neonatal respiratory distress and hemoptysis. *Thorax* 1994;49:287-8.
5. Mikaelian DO, O'Keefe JJ, Simonian S. Duplication of the esophagus. *Ann Otol* 1981;90:392-5.
6. Pokorny WJ, Sherman JO. Mediastinal masses in infants and children. *J Thorac Cardiovasc Surg* 1974;13:161-8.
7. Snyder ME, Luck SR, Hernandez R, Sherman JO, Raffensperger JG. Diagnostic dilemmas of mediastinal cysts. *J Pediatr Surg* 1985;20:810-5.
8. Haller JA, Mazur DO, Morgan WW. Diagnosis and management of mediastinal masses in children. *J Thorac Cardiovasc Surg* 1969;58:385-93.
9. Whitaker JA, Deffenbaugh LD, Cooke AR. Esophageal duplication cyst. *Am J Gastroenterol* 1980;73:329-32.
10. Le Roux BT. Intrathoracic duplication of the foregut. *Thorax* 1962;17:357-62.
11. Stringel G, Mercer S, Briggs V. Esophageal duplication cyst containing a foreign body. *Can Med Assoc J* 1985;132:529-31.