

Canadian-acquired hydatid disease: A case report

Mohammed Al Saghier MD¹, Mark C Taylor MD MSc¹, Howard M Greenberg MD²

M Al Saghier, MC Taylor, HM Greenberg. Canadian-acquired hydatid disease: A case report. *Can J Infect Dis* 2001;12(3):178-182.

Echinococcal cysts are unusual in Canada, and most cases seen are in immigrants. In northern Canadian communities, *Echinococcus granulosus* infection occasionally is acquired from dogs that feed on the entrails of caribou or moose. Seventeen patients with Canadian-acquired hydatid cysts were seen over an 11-year period. One challenging case is described in detail. An 18-year-old aboriginal woman presented with jaundice, pain, lower extremity edema and coagulopathy from a 26 cm echinococcal hepatic cyst. She was successfully treated with a combination of oral albendazole, percutaneous drainage and surgery. One-year follow-up showed no recurrence of disease. The management options for echinococcal cysts are extensively reviewed.

Key Words: *Echinococcus*; Hepatic cyst; Hydatid; Jaundice

Hydatidose acquise au Canada : Rapport de cas

RÉSUMÉ : Les kystes échinococciques sont inhabituels au Canada et la plupart des cas s'observent chez des immigrants. Dans les communautés du Grand Nord canadien, l'infection à *Echinococcus granulosus* est parfois transmise par des chiens qui se nourrissent des entrailles de caribous ou d'originaux. Dix-sept patients présentant une hydatidose acquise au Canada ont été vus au cours d'une période de onze ans. On décrit ici plus en détail un cas complexe. Une femme d'origine aborigène de 18 ans s'est présentée avec ictère, douleur, œdème des membres inférieurs et coagulopathie associés à un kyste hépatique échinococcique de 26 cm. Elle a été traitée avec succès au moyen d'un traitement associant l'albendazole oral, un drainage percutané et une chirurgie. Une année de suivi n'a révélé aucune récurrence de la maladie. Les options thérapeutiques pour le traitement des kystes échinococciques sont passées en revue en détail.

Echinococcal disease is occasionally seen in immigrants and among the indigenous population of northern Canadian communities. Both *Echinococcus granulosus* and *Echinococcus multilocularis* infections are seen in Canada; however, the present paper does not address *E multilocularis*. In most endemic countries, the definitive host for *E granulosus* is the dog, and the intermediate host is the sheep. However, in Alaska and northern Canada, the definitive host may be the wolf, dog or possibly fox, and the intermediate host may be the caribou or moose. It has been suggested by some authors that the sylvatic variant of the disease seen in North America is more benign than the pastoral variant seen in countries traditionally considered to be sources of hydatid disease (1-3).

CASE PRESENTATIONS

A retrospective search of hospital records for all patients treated for hydatid disease at two Winnipeg teaching hospitals from January 1987 to December 1997 revealed 17 patients who were treated for symptomatic infections apparently acquired in Manitoba or northwestern Ontario. Patients with echinococcal disease who had immigrated to Canada or who had lived in other countries were excluded from consideration. The 17 patients ranged in age from six to 70 years, with a mean age of 32.1 years. Six patients were from northwestern Ontario, while 11 patients were from Manitoba. Fourteen (82%) of the 17 patients were male. Hydatid cysts were seen in the livers of seven patients (41%), while seven patients (41%) had pulmonary involvement,

Departments of¹Surgery and²Radiology, University of Manitoba, Winnipeg, Manitoba
Correspondence: Dr MC Taylor, Department of Surgery, St Boniface General Hospital, Room Z3031, 409 Tache Avenue, Winnipeg, Manitoba R2H 2A6. Telephone 204-237-2568, fax 204-237-3429, e-mail mtaylor@sbgh.mb.ca
Received for publication January 6, 2000. Accepted May 14, 2000

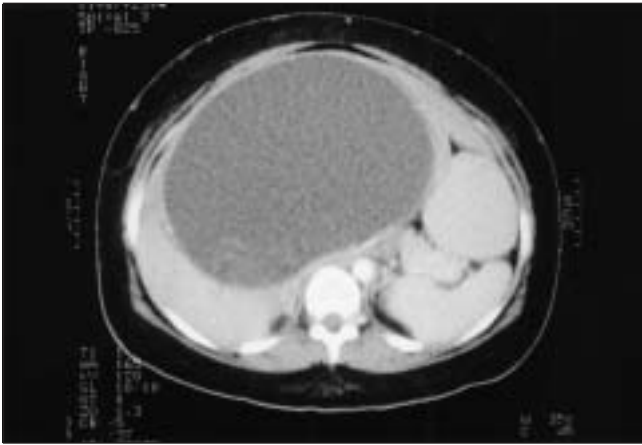


Figure 1) Computed tomography scan showing a large, well circumscribed, low density, 26 cm mass arising from the medial segment of the left lobe of the liver. There was considerable dense debris within the dependent portion of this mass. The mass produced mild dilation of the left intrahepatic biliary radicles

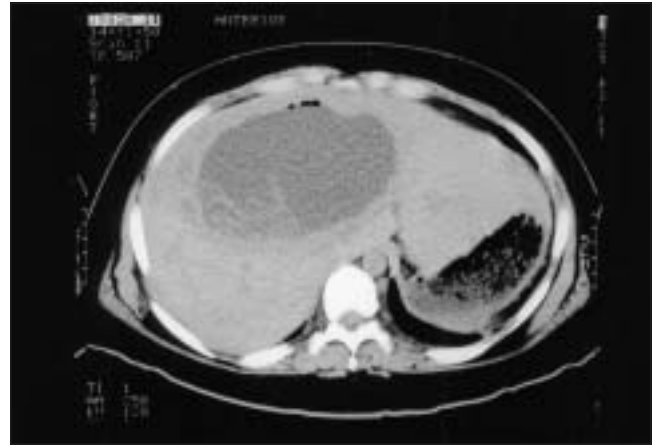

Figure 2) After two weeks of percutaneous drainage, the cyst had decreased in size. A daughter cyst and the endocyst wall were noted in the dependent portion of the cyst. The cyst measured approximately 8 cm in diameter

one patient had cysts in both the lungs and liver, and two patients (12%) had cysts in the spleen. The diagnosis was confirmed pathologically or with a combination of positive serology and characteristic appearance on imaging studies. Twelve patients (71%) were treated with surgery alone, two patients (12%) were treated with surgery and percutaneous drainage, and three patients (18%) received no curative treatment. One of the no treatment patients suffered spontaneous rupture of a hepatic hydatid cyst and was treated with paracentesis, which led to complete recovery. The other two patients were lost to follow-up. Eight patients received oral albendazole in addition to surgical treatment.

One of the above 17 patients was an 18-year-old aboriginal woman who presented to the emergency room with a one-month history of right upper quadrant abdominal pain, increasing abdominal distension, anorexia and weight loss. One week before admission, her abdominal pain and anorexia had become progressively worse, and she had developed jaundice, pruritis and bilateral leg edema.

The patient was born in Sioux Lookout, Ontario, but had spent most of her life in Winnipeg, Manitoba. She had no history of travel outside northern Ontario and Manitoba. Past medical history was not significant, with no history of biliary or hepatic disease. Physical examination revealed jaundice and a tender right upper quadrant abdominal mass approximately 14 cm in diameter.

Initial laboratory investigations revealed the following concentrations: total bilirubin 335 $\mu\text{mol/L}$ (direct 317 $\mu\text{mol/L}$), aspartate aminotransferase 101 U/L, alanine aminotransferase 48 U/L and alkaline phosphatase 423 U/L. The coagulation profile showed a prothrombin time of 13.9 s, a partial thromboplastin time of 39.1 s and an international normalized ratio of 1.36. Serum echinococcal serology was positive at 1:128. Ultrasound of the abdomen revealed a 26 cm cystic mass in the left lobe of the liver. A computed tomography (CT) scan revealed a hypodense, cystic mass compressing the

inferior vena cava and portal vein, and a dilated biliary tree. The right hepatic lobe parenchyma was compressed posteriorly (Figure 1). Hepatoscintigraphy demonstrated that the cyst communicated with the biliary tree, and biliary excretion was markedly delayed.

The patient was started on oral albendazole 400 mg bid. On her fourth hospital day, CT-directed percutaneous drainage was performed. A 7F catheter was advanced into the cyst across normal-appearing hepatic parenchyma. Initially, 1000 mL of viscous, bile-coloured fluid drained from the cyst. The fluid aspirated from the cyst showed a hooklet suggestive of *E. granulosus*. Within 14 days, 14,700 mL of fluid was drained from the lesion. The pruritis and pain resolved. After two weeks of drainage, laboratory results were as follows: total bilirubin 70 $\mu\text{mol/L}$ (direct 55 $\mu\text{mol/L}$), alkaline phosphatase 179 U/L, prothrombin time 12 s and partial thromboplastin time 31 s. A follow-up CT scan showed reduction of the size of the cyst to 8 cm (Figure 2).

At the time of surgery, a large cystic lesion occupied most of the left lobe of the liver. The contents were carefully aspirated through a 10 mm laparoscopic trocar after placing hypertonic, saline-soaked sponges around the lesion. The cyst was then opened, and the pericyst was excised from normal hepatic parenchyma. A bile duct draining into the cyst was identified and oversewn. At the end of surgery, omentum was used to fill the cyst. The postoperative course was unremarkable. The concentrations changed as follows: serum total bilirubin 29 $\mu\text{mol/L}$ (direct 19 $\mu\text{mol/L}$), alkaline phosphatase 117 U/L, aspartate aminotransferase 29 U/L and alanine aminotransferase 27 U/L. On the 14th postoperative day, she was discharged and was advised to continue albendazole for a total course of three months. Follow-up until the end of one year revealed no recurrence of symptoms, and aspartate aminotransferase, alanine aminotransferase, alkaline phosphatase and bilirubin levels, and prothrombin time were all normal. A CT scan showed no evidence of recurrence.

DISCUSSION

In North America, human hydatid disease exists in two distinct forms. Cystic hydatid disease is the most common, and is caused by *E granulosus*, a canine cestode that inhabits the small intestine of dogs, wolves and possibly foxes (4). Alveolar hydatid disease is less common and is caused by *E multilocularis* (4,5). Cystic hydatid disease is endemic in many parts of the world, especially in sheep-raising areas. In this pastoral form of the disease, sheep serve as intermediate hosts, and the infection is spread to dogs when they are fed sheep viscera. Humans are accidental intermediate hosts, acquiring the disease through contact with canine feces (5). The disease is common in the Mediterranean, the Baltics, South America, Australia and the Middle East (4). In the sylvatic form of the disease seen in Alaska and northern Canada, the intermediate hosts are caribou and moose.

The adult worm produces eggs in the small bowel of the definitive host. The eggs are released to the environment, and the intermediate host acquires the infection by ingesting eggs. Under the action of gastric and intestinal enzymes, the oncosphere is released and penetrates the intestinal wall. It reaches other organs via the portal vein or lymphatics and develops into the larval stage (hydatid cyst) (1,6). The mature cyst wall consists of three layers: an outer adventitial layer that represents the host's dense fibrous response, a laminated membrane and a germinal epithelium containing protoscolices. The liver is the most common organ in which hydatid cysts develop (50% to 70%), followed by the spleen and lungs (20% to 30%) (5). In the sylvatic variety, lung cysts may be more common (2). Most cysts are asymptomatic and are only discovered during investigations for other complaints. However, they may cause considerable pain, become infected and lead to anaphylactic shock, although rarely (4). Obstructive jaundice secondary to a mass effect on bile ducts or the portal vein, or rupture into the biliary tree, may be seen (1). Hepatic veins and/or the inferior vena cava may be compressed (5). Biliary complications have been reported in less than 8% of patients with hepatic hydatid cysts (5). The disease must be differentiated from other cysts of the liver, such as simple cysts and biliary cystadenomas (4). In most cases, there is a history of significant exposure to dogs that had been fed infected viscera, coupled with suspicious findings on imaging studies. Characteristic findings on ultrasound include anechoic areas, septations and daughter cysts. On CT scan, the pericyst and/or the endocyst may be readily visible. The presence of daughter cysts is diagnostic, while a calcified cyst wall is suggestive of an inactive cyst (4,6). There are no definitive laboratory tests for echinococcal infection. ELISA tests for echinococcal antigen are highly specific, but may be negative in up to one-third of patients with proven infections (7). Serological tests may also be negative in infected patients with inactive cysts.

There are few reports of hydatid disease acquired in North America (2,3,6,8-11). The sylvatic form of the disease has been described in aboriginal communities, in which wolves, dogs and possibly foxes are the primary hosts for tapeworms, while the moose and caribou are the intermediate hosts (1,6,10). Meltzer et al (8) and Cameron (9) suggested that the

majority of the patients with this form of the disease have asymptomatic lung or liver hydatid cysts, which tend to be less severe than the pastoral form. Asymptomatic cysts may not require treatment. Unlike the pastoral form, rupture of sylvatic cysts has not been associated with anaphylaxis or dissemination. Complications such as biliary obstruction have not been described (1,7-9). Most cases have been diagnosed in aboriginal communities in northern Canada, although there are a few reports of the disease in the southwestern United States (2,8,12). Langer et al (13) reported a 15-year Canadian experience with 40 patients. Most of the patients in this series were immigrants with the pastoral form of the disease, and only three patients were from rural areas of Canada.

The conventional treatment of symptomatic hydatid liver disease has been primarily surgical (12-14). An early Canadian series described cyst evacuation followed by instillation of a scolicedal agent and cyst closure (15). Reported surgical approaches include simple cyst closure without drainage, cyst excision, marsupialization, liver resection, external drainage, cystopericystectomy, omentoplasty and various combinations of procedures (12,14,16,17). Surgery should be carried out in such a manner that spilling cyst contents into the peritoneum is prevented to avoid spilling viable protoscolices into the peritoneal cavity. The cyst contents should be aspirated, the remaining cavity sterilized and the germinal epithelium removed entirely. Biliary communications should be oversewn, after which the cavity may be filled with omentum (4).

Langer et al (13) has emphasized that the critical aspects of surgery are the protection of the peritoneum during surgery, and the complete removal of the cyst fluid, daughter cysts and the germinal membrane. Magistrelli et al (17) recommended pericystectomy over the simple removal of the endocyst and cyst contents. This nonrandomized case series concluded that pericystectomy was associated with a lower risk of recurrent disease. Morel et al (18) performed pericystectomy or liver resection in 45 patients and partial cyst resection, diversion or drainage in 11 patients. The likelihood of recurrence was much higher in the conservatively treated group. However, only those patients felt to be unfit for major resections had conservative treatment. Dawson et al (16) treated 48 patients with cyst aspiration and instillation of a scolicedal agent, followed by removal of the laminated membrane and omentoplasty. No attempt was made to excise the pericyst. Of the 32 patients with uncomplicated cysts, only one developed recurrent disease. Decompression of hydatid cysts with laparoscopic surgiports during open surgery has been described by Rogiers et al (19). There are several recent case reports using laparoscopic approaches to surgical treatment of small hepatic hydatid cysts (20).

Recently, nonsurgical approaches to these lesions have been advocated (21). In the past, percutaneous aspiration of hydatid cysts was believed to be contraindicated because of the risk of anaphylaxis and spillage of scolices, resulting in peritoneal seeding and dissemination (2,5,8,17,18). Von Sinner et al (22) suggested the use of fine needle aspiration biopsy to evaluate suspected hydatid cysts having nonspecific signs in medical imaging and negative serology. Salama et al (23) reported the use of percutaneous cyst puncture followed by in-

stillation of hypertonic saline in the treatment of 45 patients with hepatic hydatid disease. Forty-three patients had no clinical or ultrasound recurrence of the disease after three years of follow-up. In a series from Turkey, Achan et al (24) reported successful long term results with 30 of 31 patients treated with percutaneous drainage. Khuroo et al (25) found that percutaneous drainage and albendazole therapy for eight weeks were superior to percutaneous drainage alone or albendazole therapy alone. Twenty-two patients were treated with percutaneous drainage (10 of whom also received albendazole), while 11 patients received albendazole alone. All 22 patients who underwent percutaneous drainage experienced a significant reduction in symptoms and cyst diameter, as well as a change in echopattern on ultrasound, compared with only two of 11 patients treated with albendazole alone. Those patients who received albendazole in addition to percutaneous drainage had a significantly greater reduction in cyst diameter. Anaphylaxis following percutaneous drainage has not been reported, but there are reports of urticaria (8,18,25). Anaphylaxis from spontaneous rupture of hydatid cysts has been reported as a rare event (8). In an experimental study in animals, anaphylactic reactions were not seen, and percutaneous treatment was found to be safe and effective (18).

A prospective, randomized study compared percutaneous drainage and albendazole therapy with surgery in the treatment of 50 patients with uncomplicated hydatid cysts (5). The surgery involved cyst aspiration followed by the removal of cyst contents and the laminated membrane. Percutaneous drainage was followed by the instillation of hypertonic saline and eight weeks of therapy with oral albendazole. Over a mean follow-up period of 17 months, there was no difference in mean cyst diameter, probability of total cyst disappearance or echinococcal seronegativity. Procedure-related complications were significantly more common in the surgical group.

Advocates of percutaneous drainage favour filling the cyst with hypertonic saline after draining the fluid. However, this is contraindicated in patients with biliary communication because of the possibility of biliary tree injury (2,5,8,18). In addition, only surgical treatment of the hydatid cyst allows for the possibility of completely evacuating the cyst, inactivating the parasites, removing the germinal layer,

obliterating the residual cavity and oversewing any biliary communication.

Medical therapy with albendazole alone is controversial, but many recommend it in the perioperative period. As a sole treatment modality, it has not been proven to be equivalent to surgery or percutaneous drainage (26). There is evidence that albendazole 10 mg/kg/day for three months is superior than one month of therapy (27). A recent trial showed degenerative changes in 82% of albendazole-treated cysts at the end of treatment, but 25% showed regeneration during follow-up (28). An accompanying editorial stated that surgery remains the first choice for treatment, but alternatives employing percutaneous techniques and chemotherapy are safe and effective (29). One randomized trial showed that in 94% of cysts removed from patients treated for three months before surgical removal, there was no viability of the cyst contents (26). Albendazole therapy alone may be indicated in those patients who decline surgery or in whom surgery is contraindicated (26). Morris (27) found that the use of one month of preoperative albendazole therapy prevented recurrence in 14 of 16 patients.

In the present case, it was felt that the patient was too ill to withstand a major operative procedure at the time of presentation. The large size and position of the cyst had resulted in obstructive jaundice with hepatocellular dysfunction and coagulopathy. Percutaneous drainage under CT direction was used to decompress the cyst, eliminating pressure on the biliary tree and the inferior vena cava. It does not seem that the use of percutaneous drainage as a temporizing measure to decompress large complicated cysts and relieve biliary obstruction has been described previously.

CONCLUSION

Cystic hydatid disease is an uncommon infection in northern North America, but is similar in clinical manifestations to disease acquired in sheep-raising areas. Seventeen patients were seen over an 11-year period. One unusually severe case of hydatid hepatic disease was treated successfully with a combination of oral albendazole, percutaneous drainage and surgical removal. Percutaneous drainage was useful as a preoperative temporizing measure in this deeply jaundiced patient. Follow-up at one-year showed no evidence of recurrent disease.

REFERENCES

1. Abou-Khalil S, Smith BM, MacLean JD, et al. Acute cholecystitis and cholangitis caused by *Echinococcus granulosus*. *Am J Gastroenterol* 1996;91:805-7.
2. Finlay JC, Speert DP. Sylvatic hydatid disease in children: case reports and review of endemic *Echinococcus granulosus* infection in Canada and Alaska. *Pediatr Infect Dis J* 1992;11:322-6.
3. Wilson JF, Diddams AC, Rausch RL. Cystic hydatid disease in Alaska. *Am Rev Respir Dis* 1968;98:1-15.
4. Doty JE, Tompkins RK. Management of cystic disease of the liver. *Surg Clin North Am* 1989;69:285-95.
5. Khuroo MS, Wani ON, Javid G, et al. Percutaneous drainage compared with surgery for hepatic hydatid cysts. *N Engl J Med* 1997;337:881-7.
6. Magath TB. Hydatid disease in North America. *Pa Med J* 1941;44:813-9.
7. Coltorti EA. Standardization and evaluation of an enzyme immunoassay as a screening test for the seroepidemiology of human hydatidosis. *Am J Trop Med Hyg* 1986;35:1000.
8. Meltzer H, Kovacs L, Orford T, Matas M. Echinococcosis in North American Indians and eskimos. *CMAJ* 1956;75:121-7.
9. Cameron TWM. The incidence and diagnosis of hydatid cysts in Canada. *Echinococcus granulosus* var *canadensis*. *Parassitologia* 1960;2:381-90.
10. Miller MJ. Hydatid infection in Canada. *CMAJ* 1953;68:423-34.
11. Moore RD, Urschel JD, Fraser RE, Nakal SS, Geeraert AJ. Cystic hydatid lung disease in northwest Canada. *Can J Surg* 1994;37:20-2.
12. Katz R, Murphy S, Kosloske A. Pulmonary echinococcosis: A pediatric disease of the southwestern United States. *Pediatrics* 1980;65:1003-6.
13. Langer JC, Rose DB, Keystone JS, Taylor BR, Langer B. Diagnosis and management of hydatid disease of the liver: A 15-year North American experience. *Ann Surg* 1984;199:412-7.
14. Saffioleas M, Misiakos E, Manti C, et al. Diagnostic evaluation and surgical management of hydatid disease of the liver. *World J Surg* 1994;18:859-65.

15. Cohen Z, Stone RM, Langer B. Surgical treatment of hydatid disease of the liver. *Can J Surg* 1976;19:416-20.
 16. Dawson JL, Stamatakis JD, Stringer MD, Williams R. Surgical treatment of hepatic hydatid disease. *Br J Surg* 1988;75:946-50.
 17. Magistrelli P, Masetti R, Coppola R, et al. Surgical treatment of hydatid disease of the liver. *Arch Surg* 1991;126:518-23.
 18. Morel P, Robert J, Rohner A. Surgical treatment of hydatid disease of the liver: A survey of 69 patients. *Surgery* 1988;104:859-62.
 19. Rogiers X, Bloechle C, Broelsch CE. Safe decompression of hepatic hydatid cysts with a laparoscopic surgiport. *Br J Surg* 1995;82:1111.
 20. Sever M, Skapin S. Laparoscopic pericystectomy of liver hydatid cyst. *Surg Endosc* 1995;9:1125-6.
 21. Pinch LW, Wilson JF. Non-surgical management of cystic hydatid disease in Alaska: A review of 30 cases of *Echinococcus granulosus* infection treated without operation. *Ann Surg* 1973;178:45-8.
 22. Von Sinner WN, Nyman R, Linjawi T, Ali AM. Fine needle aspiration biopsy of hydatid cysts. *Acta Radiol* 1993;36:168-72.
 23. Salama H, Abdel-Wahab MF, Stricklard T. Diagnosis and treatment of hepatic hydatid cysts with aid of echo-guided percutaneous cyst puncture. *Clin Infect Dis* 1995;21:1372-6.
 24. Akhan O, Ozmen M, Dincer A, et al. Liver hydatid disease: Long-term results of percutaneous treatment. *Radiology* 1996;98:259-64.
 25. Khuroo MS, Dar MY, Yattoo GN, et al. Percutaneous drainage versus albendazole therapy in hepatic hydatidosis: A prospective, randomized study. *Gastroenterology* 1993;104:1452-9.
 26. Gil-Grande A, Rodrigues-Caabeiro F, Prieto JG, et al. Randomised controlled trial of efficacy of albendazole in intra-abdominal hydatid disease. *Lancet* 1993;342:1269-72.
 27. Morris DL. Preoperative albendazole therapy for hydatid cyst. *Br J Surg* 1987;74:805--6.
 28. Franchi C, Di Vico B, Teggi A. Long-term evaluation of patients with hydatidosis treated with benzimidazole carbamates. *Clin Infect Dis* 1999;29:304-9.
 29. Schantz PM. Editorial reponse: Treatment of cystic echinococcosis – Improving but still limited. *Clin Infect Dis* 1999;29:310-1.
-