

***Vibrio vulnificus* septicemia after handling *Tilapia* species fish: A Canadian case report and review**

Donald C Vinh MD^{1,3}, Samira Mubareka MD^{1,3}, Bunmi Fatoye MD², Pierre Plourde MD^{2,3,4}, Pamela Orr MD^{1,2,3}

DC Vinh, S Mubareka, B Fatoye, P Plourde, P Orr. *Vibrio vulnificus* septicemia after handling *Tilapia* species fish: A Canadian case report and review. *Can J Infect Dis Med Microbiol* 2006;17(2):129-132.

BACKGROUND: *Vibrio vulnificus* can cause a necrotizing soft tissue infection or primary septicemia; these infections are collectively known as vibriosis. This bacterium is commonly found within molluscan shellfish. Primary septicemia is often fatal, principally affecting persons with chronic liver disease.

CASE PRESENTATION: A fatal case of *V vulnificus* sepsis that developed in a patient with chronic hepatitis B and chronic renal failure is reported. Diagnosis was made by isolation of the pathogen by blood culture. Upon further questioning, the patient's family recounted that the patient had handled and ingested *Tilapia* species fish in the hours preceding the patient's presentation. Despite treatment with doxycycline and cefotaxime, in conjunction with supportive care in the intensive care unit, the patient died on day 7 from multiple organ dysfunction.

CONCLUSION: The present case highlights the need to consider *V vulnificus* in the microbiological differential diagnosis when a person presents with sepsis and bullous cutaneous lesions. The importance of educating patients with liver disease (and certain other chronic diseases) about the need to be cautious when handling or consuming seafood is underscored.

Key Words: Bullae; Canada; Fish; Liver; Sepsis; *Vibrio vulnificus*

CASE PRESENTATION

A 58-year-old man presented to his local community hospital 4 h after onset of fever and a painful, swollen left arm. His medical history included chronic hepatitis B virus infection, end-stage hypertensive nephropathy requiring hemodialysis and coronary artery disease. The patient had no history of travel or animal exposure. Initial examination revealed erythema of the left arm and thrombosis of the left arteriovenous fistula. Blood cultures were drawn, and the patient was admitted. Treatment with cefazolin 2 g intravenously (IV) was initiated. Within 12 h, the patient developed bullous lesions on the distal aspect of both upper extremities, predominantly on the left arm. Intravenous fluids, vasopressors and mechanical

Septicémie à *Vibrio vulnificus* après manipulation d'un *Tilapia* : Rapport de cas et revue de la littérature

HISTORIQUE : *Vibrio vulnificus* peut causer une infection nécrosante des tissus mous, ou septicémie primaire. Ces infections sont regroupées sous le terme vibrioses. Cette bactérie est souvent présente dans les mollusques. La septicémie primaire est souvent fatale, surtout chez les personnes qui souffrent de maladie hépatique chronique.

PRÉSENTATION DU CAS : On présente ici un cas fatal d'infection à *V vulnificus* qui s'est développé chez un patient atteint d'hépatite B et d'insuffisance rénale chroniques. Le diagnostic a été posé après que l'on ait isolé l'agent pathogène à l'hémoculture. À l'interrogatoire, la famille du patient a révélé que celui-ci avait manipulé et mangé du *Tilapia* quelques heures avant de se présenter. Malgré le traitement par doxycycline et céfotaxime et les mesures de maintien des fonctions vitales à l'unité de soins intensifs, le patient est décédé le septième jour par suite d'une insuffisance pluriorganique.

CONCLUSION : Ce cas rappelle la nécessité de tenir compte de *V vulnificus* lors du diagnostic microbiologique différentiel quand une personne se présente avec une septicémie et des lésions cutanées bulleuses. Il est important d'aviser les patients qui souffrent de maladie hépatique (et de certaines autres maladies chroniques) de la nécessité d'être prudents lorsqu'ils manipulent ou consomment des poissons et fruits de mer.

ventilation were required over the subsequent 6 h for progressive shock and respiratory failure. The patient was then transferred to a tertiary care hospital.

On admission to the tertiary care hospital, physical examination findings were remarkable for a temperature of 38.3°C, pulse of 111 beats/min, blood pressure of 104/58 mmHg (on vasopressin and neosynephrine), as well as hemorrhagic bullae and serous, fluid-filled, flaccid bullae on the distal arms (Figure 1). No breaks in the skin were identified on his hands. The initial laboratory data were notable for a white blood cell count of 4.9×10^9 leukocytes/L (3.7×10^9 bands/L), myonecrosis (creatinine kinase 1437 U/L, myoglobin 3843 µg/L) and disseminated intravascular coagulation (platelet count 24×10^9 /L,

¹Department of Medicine, Section of Infectious Diseases; ²Department of Community Health Sciences; ³Department of Medical Microbiology, University of Manitoba; ⁴Population and Public Health Program, Winnipeg Regional Health Authority, Winnipeg, Manitoba

Correspondence: Dr Donald C Vinh, Room 543, Basic Medical Sciences Building, 730 William Avenue, Winnipeg, Manitoba R3E 0W3.

Telephone 204-789-3308, fax 204-789-3926, e-mail don_vinh@yahoo.com

Received and accepted for publication October 24, 2005

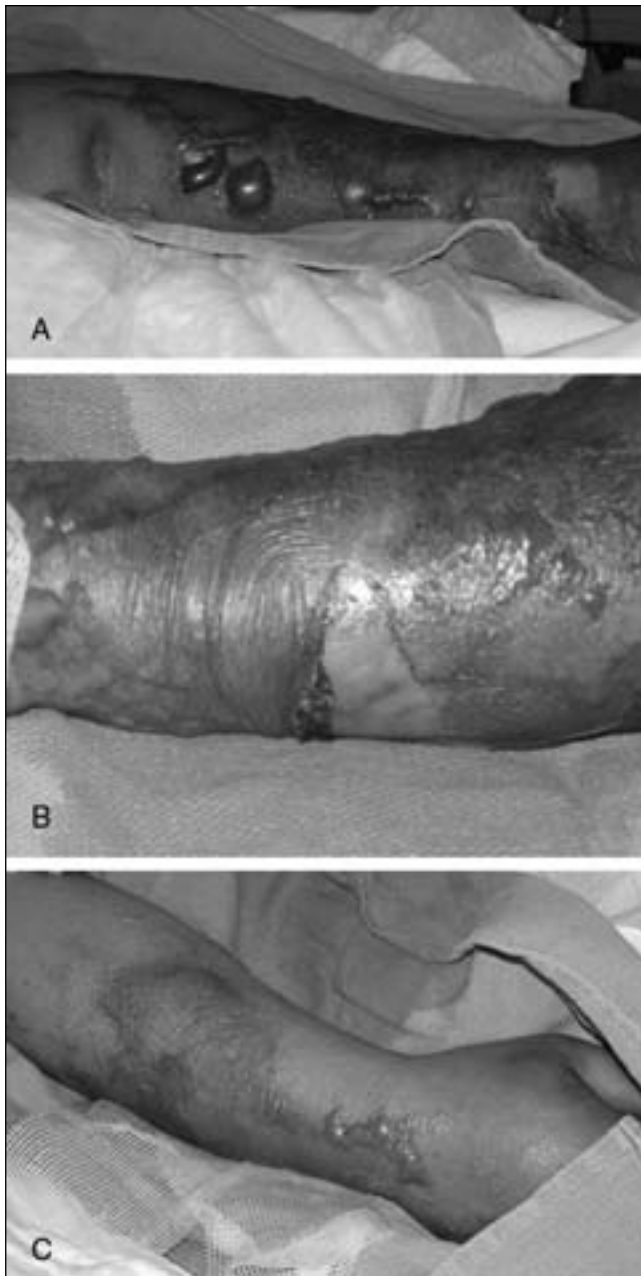


Figure 1) Characteristic bullous skin lesions of *Vibrio vulnificus* sepsis. **A** Hemorrhagic, fluid-filled bullae of the left forearm, with evidence of desquamation in the wrist area; **B** Massive denudation of the epithelium in the previous area of the bullae; **C** Serous, fluid-filled blisters and collapse of bullae (which eventually desquamated) on the right forearm

international normalized ratio 5.9 and prolonged activated partial thromboplastin time 48.8 s). Gram stain of fluid aspirated from bullae revealed heavy (4+) polymorphonuclear leukocytes but no organisms. The patient was started empirically on vancomycin (one dose of 1 g IV) and meropenem (500 mg IV every 24 h, adjusted for his dialysis status). Within 24 h of presentation to the original hospital, a Gram-negative bacillus was isolated from the initial peripheral blood cultures. Computed tomodensitometry imaging of the abdomen and pelvis revealed no intra-abdominal source of infection.

Initial identification of the isolate by the VITEK 2 automated system (bioMérieux, USA) revealed *Vibrio vulnificus*.

The antimicrobial regimen was therefore changed to doxycycline (100 mg IV every 12 h) and cefotaxime (2 g IV every 24 h) on day 2 of hospitalization at the tertiary hospital. Confirmation of the isolate was performed by an alternate phenotypic method (API 20E system, bioMérieux), by demonstration of green-pigmented colonies on thiosulfate-citrate bile salts-sucrose agar, and by 16S ribosomal RNA sequencing (accession number gi | 27360771 | gb | AE016801.1, *V vulnificus* CMCP6 chromosome 1).

Upon further questioning of the family, it was discovered that the patient had purchased and prepared fresh *Tilapia* species fish for supper the evening he presented to the primary hospital. The remaining *Tilapia* fish (which, at this point, had been cooked and refrigerated) was obtained and sent to the Canadian Department of Fisheries, where bacterial cultures were negative for *Vibrio* species. The Canadian Food Inspection Agency confirmed that the fish had been imported from a fish farm in North Dakota. Investigations held in conjunction with the United States Food and Drug Administration revealed no metachronous cases reported to Canadian or American public health authorities in the four-week time frame before and after onset of illness of the index case.

Despite appropriate antibiotics and supportive management, the patient died on day 7 from multiple organ dysfunction.

DISCUSSION

V vulnificus is a halophilic, Gram-negative bacillus with a worldwide distribution. It is characteristically found in marine animals that inhabit warm bodies of water with intermediate salinities, such as the coastal waters along the Gulf of Mexico (1,2). It can also be found in Canada. A review of the environmental distribution of *V vulnificus* in Canada (3) demonstrated its presence in the waters and domestically harvested shellfish along the western and eastern coasts. However, this low-level, seasonal presence does not seem to be an important reservoir for disease in Canada, as no food-related cases have been reported (3). However, because noncholerae vibrios are not reportable to public health authorities, the true incidence of disease in Canada remains unknown.

Typical organisms that can harbour *V vulnificus* are uncooked molluscan shellfish (particularly oysters), clams and crabs (1,2,4). In Canada, *V vulnificus* has been identified in oysters in British Columbia, as well as in mussels and clams from New Brunswick and Prince Edward Island (3). In addition to these aquatic wildlife, *V vulnificus* has also been isolated from plankton and certain types of fish (5,6). The predominant season for microbial proliferation are the warm summer months, where virtually 100% of oysters carry *V vulnificus* and/or *Vibrio parahaemolyticus* (1).

The most likely source of vibriosis in this case is the *Tilapia* fin-fish handled by the patient in the hours preceding the acute onset of symptoms. Although *V vulnificus* was not isolated from the fish remnants, this putative link is supported by the temporal relationship between exposure and disease, with concomitant absence of travel and other potential exposures within the incubation period for *V vulnificus*.

Vibrio species cause three major forms of infection: gastroenteritis, wound infection and primary septicemia (particularly involving *V vulnificus*), which is defined as bacteremia without an obvious focus of infection.

A primary necrotizing wound infection may account for the patient's clinical presentation, as the distribution of the bullae

was suggestive of a handling-related source. Wound infections with *V vulnificus* have been reported in fishermen and other individuals while handling certain types of fish, including *Tilapia* species (7,8). Pond-cultivated *Tilapia* species fish was the point source responsible for 61 of 62 (98%) cases of an outbreak of *V vulnificus* wound infection and bacteremia in Israel (9); the other case was related to exposure to carp. Two fatalities related to that outbreak have been reported (10). The present patient, however, had no apparent evidence of a cutaneous portal of entry.

More likely, the patient's presentation was that of *V vulnificus* primary septicemia. This condition typically presents with fever, hypotension and cutaneous manifestations, most commonly hemorrhagic bullae on the extremities (1,11). Clinical criteria have been formulated to allow for a presumptive diagnosis of *V vulnificus* sepsis (Table 1) (12). Retrospectively, this patient fulfilled all four of these criteria. Primary septicemia occurs after the consumption of raw or improperly cooked foods containing *V vulnificus*, in persons with certain predisposing conditions. Although the *Tilapia* species fish was the most plausible source in this case, the fish remnants yielded no organisms, arguing against inadequate cooking as the point of transmission. Microbiological recovery, however, may have been limited by the refrigeration of these remnants before they were brought in by the patient's family. A compromised yield occurs when ambient temperatures are below 10°C; under this condition, changes in fatty acid metabolism allow the organism to enter a viable but nonculturable state, particularly if initial levels of the organism were low (13). Alternatively, accidental ingestion may have occurred during handling of the raw fish. The median time between exposure and onset of symptoms is 18 h (14), similar to the chronology of events in the present case. Patients with shock on initial presentation or who develop shock within 12 h of hospitalization have the highest mortality (over 90%) (1).

Reports of serious infections with *V vulnificus* are rare, with an incidence of approximately 0.5 cases/100,000 population per year in the United States (1). However, the case-fatality rate is high in immunocompromised individuals, exceeding 50% (1,4). The classical comorbidity predisposing to primary septicemia is chronic liver disease or cirrhosis (1,15), typically from alcoholism or hemochromatosis. Chronic hepatitis B or C virus infection-related hepatic diseases (liver cirrhosis and hepatoma) are well-known risk factors in Asian countries (16,17). Although our patient had a history of chronic hepatitis B virus infection (surface antigen-positive, hepatitis B virus-DNA-positive by polymerase chain reaction, with presence of precore mutant sequence), he had no evidence in previous assessments or on the current computed tomodensitometry of a precirrhotic/cirrhotic state or a hepatoma. Other underlying illnesses that are potential risk factors for *V vulnificus* sepsis include chronic renal disease/hemodialysis and intravenous iron therapy (18,19). The increased susceptibility to virulent disease under these conditions may relate to the organism's ability to grow rapidly in the presence of iron. The survival of *V vulnificus* in human whole blood or tissue is higher with elevated serum transferrin iron saturation levels and with greater serum ferritin concentrations (20). Other conditions associated with defects in host defenses (eg, diabetes mellitus [21], long-term administration of corticosteroids [22] and HIV [23]) have also been reported as possible risk factors for severe disease.

TABLE 1
Criteria for the presumptive clinical diagnosis of *Vibrio vulnificus* sepsis*

1. Hypotension, shock or other evidence of sepsis (eg, for wound infections, presence of rapidly progressive cellulitis or myonecrosis).
2. A history of chronic liver disease/cirrhosis (eg, alcoholism, hemochromatosis or chronic hepatitis B) or immunosuppression (eg, HIV). Although not proposed in the original criteria, chronic renal disease/hemodialysis may be considered a risk factor (18).
3. A history of recent consumption of raw or improperly cooked shellfish (including foods that have been contaminated by them), or exposure of wounds to estuarine water.
4. Presence of characteristic bullous skin lesions (eg, hemorrhagic fluid-filled bullae).

*Adapted from reference 12

Early antimicrobial therapy directed against *V vulnificus* is essential for successful management. Currently, the Clinical and Laboratory Standards Institute (formerly National Committee for Clinical Laboratory Standards) has no interpretive standards for antimicrobial susceptibility testing for *V vulnificus*. However, based on an early murine model (24), and subsequently supported by a clinical case series from Florida (1,4), first-line therapy should include a tetracycline (eg, doxycycline 100 mg IV every 12 h). In time-kill studies, a regimen of minocycline (100 mg IV every 12 h) and cefotaxime (2 g IV every 8 h) has been shown to have a synergistic inhibitory effect on the growth curves of *V vulnificus* (25). In an experimental mouse model of *V vulnificus* soft tissue infection, this combination therapy was associated with better survival when compared with monotherapy (26). Ciprofloxacin (400 mg IV every 12 h) has been used successfully for the treatment of wound infections, and the newer fluoroquinolones appear to be as effective as the minocycline-cefotaxime combination both in vitro and in vivo (17). A previous murine model failed to demonstrate in vivo efficacy for cefazolin (24), the antimicrobial administered in the present case on initial presentation. Empirical treatment upon transfer to the tertiary hospital included vancomycin and meropenem. The in vitro efficacy of meropenem against *Vibrio* species has been previously demonstrated (27).

Surgical intervention (incision and drainage, debridement, fasciotomy and amputation) may be considered as an adjunct to medical management for primary necrotizing soft tissue infection due to *V vulnificus* (28). Convincing studies demonstrating a beneficial effect on survival, however, are lacking.

Although *V vulnificus* was isolated in the present case, other bacteria associated with exposure to aquatic environments or marine flora may also cause severe soft tissue infections and/or septicemia in humans. A similar presentation of cellulitis, myonecrosis or septicemia in patients with pre-existing liver disease can occur with *Edwardsiella tarda* after ingestion of raw fish (29). As well, infections due to *Plesiomonas shigelloides* (30,31), *Aeromonas hydrophila* (32,33), *Erysipelothrix rhusiopathiae* (34,35), *Mycobacterium marinum* (36) and *Streptococcus iniae* (37,38) have occurred after the handling of fish. The latter pathogen was responsible for a cluster of four cases in the greater Toronto area in 1995/1996, in association with *Tilapia* species fish as well. None of these pathogens were identified in the present study.

CONCLUSIONS

To our knowledge, this is the first case of *V. vulnificus* primary septicemia described in Canada. The present case highlights the need to consider *V. vulnificus* as a cause of sepsis associated with bullous cutaneous lesions, even in areas where the pathogen is not endemic because patients may still be exposed via imported shellfish and seafood. It also underscores the importance of educating patients with certain chronic diseases,

such as liver disease or chronic renal failure, about the need to be cautious when handling such foods (eg, abstinence, wearing protective gloves), as well as about the hazards associated with the consumption of improperly cooked foods.

ACKNOWLEDGEMENTS: The authors recognize the expertise of the Health Sciences Centre Clinical Microbiology Laboratory (Winnipeg, Manitoba) in the identification of the organism.

REFERENCES

- Morris JG Jr. Cholera and other types of vibriosis: A story of human pandemics and oysters on the half shell. *Clin Infect Dis* 2003;37:272-80.
- Shapiro RL, Altekruze S, Hutwagner L, et al. The role of Gulf Coast oysters harvested in warmer months in *Vibrio vulnificus* infections in the United States, 1988-1996. *Vibrio Working Group. J Infect Dis* 1998;178:752-9.
- Stavric S, Buchanan B. Does *Vibrio vulnificus* present a health threat to Canadians? *Can J Infect Dis* 1997;8:279-85.
- Hlady WG, Klontz KC. The epidemiology of *Vibrio* infections in Florida, 1981-1993. *J Infect Dis* 1996;173:1176-83.
- Oliver JD, Warner RA, Cleland DR. Distribution and ecology of *Vibrio vulnificus* and other lactose-fermenting marine vibrios in coastal waters of the southeastern United States. *Appl Environ Microbiol* 1982;44:1404-14.
- DePaola A, Capers GM, Alexander D. Densities of *Vibrio vulnificus* in the intestines of fish from the U.S. Gulf Coast. *Appl Environ Microbiol* 1994;60:984-8.
- Calif E, Kaufman B, Stahl S. *Vibrio vulnificus* infection of the lower limb after fish spine injuries. *Clin Orthop Relat Res* 2003;411:274-9.
- Said R, Volpin G, Grimberg B, Friedenstrom SR, Lefler E, Stahl S. Hand infections due to non-cholera *Vibrio* after injuries from St Peter's fish (*Tilapia zillii*). *J Hand Surg [Br]* 1998;23:808-10.
- Bishara N, Agmon V, Finkelstein R, et al. Clinical, epidemiological, and microbiological features of *Vibrio vulnificus* biogroup 3 causing outbreaks of wound infection and bacteraemia in Israel. *Israel Vibrio Study Group. Lancet* 1999;354:1421-4.
- Finkelstein R, Edelstein S, Mahamid G. Fulminant wound infections due to *Vibrio vulnificus*. *Isr Med Assoc J* 2002;4:654-5.
- Borenstein M, Kerdel F. Infections with *Vibrio vulnificus*. *Dermatol Clin* 2003;21:245-8.
- Morris JG. "Non-cholera" *Vibrio* species. In: Blaser MJ, Smith PD, Ravdin JI, Greenberg HB, Guerrant RL, eds. *Infections of the Gastrointestinal Tract*, 2nd edn. Philadelphia: Lippincott, Williams & Wilkins, 2002:167-9.
- Day AP, Oliver JD. Changes in membrane fatty acid composition during entry of *Vibrio vulnificus* into the viable but nonculturable state. *J Microbiol* 2004;42:69-73.
- Klontz KC, Lieb S, Schreiber M, Janowski HT, Baldy LM, Gunn RA. Syndromes of *Vibrio vulnificus* infections. Clinical and epidemiologic features in Florida cases, 1981-1987. *Ann Intern Med* 1988;109:318-23.
- Chiang SR, Chuang YC. *Vibrio vulnificus* infection: Clinical manifestations, pathogenesis, and antimicrobial therapy. *J Microbiol Immunol Infect* 2003;36:81-8.
- Hsueh PR, Lin CY, Tang HJ, et al. *Vibrio vulnificus* in Taiwan. *Emerg Infect Dis* 2004;10:1363-8.
- Tang HJ, Chang MC, Ko WC, Huang KY, Lee CL, Chuang YC. In vitro and in vivo activities of newer fluoroquinolones against *Vibrio vulnificus*. *Antimicrob Agents Chemother* 2002;46:3580-4.
- Barton JC, Coghlan ME, Reymann MT, Ozbirn TW, Acton RT. *Vibrio vulnificus* infection in a hemodialysis patient receiving intravenous iron therapy. *Clin Infect Dis* 2003;37:e63-7.
- Stabellini N, Camerani A, Lambertini D, et al. Fatal sepsis from *Vibrio vulnificus* in a hemodialyzed patient. *Nephron* 1998;78:221-4.
- Hor LI, Chang TT, Wang ST. Survival of *Vibrio vulnificus* in whole blood from patients with chronic liver diseases: Association with phagocytosis by neutrophils and serum ferritin levels. *J Infect Dis* 1999;179:275-8.
- Torres L, Escobar S, Lopez AI, Marco ML, Pobo V. Wound infection due to *Vibrio vulnificus* in Spain. *Eur J Clin Microbiol Infect Dis* 2002;21:537-8.
- Devi SJ, Hayat U, Frasch CE, Kreger AS, Morris JG Jr. Capsular polysaccharide-protein conjugate vaccines of carbo type 1 *Vibrio vulnificus*: Construction, immunogenicity, and protective efficacy in a murine model. *Infect Immun* 1995;63:2906-11.
- Food and Drug Administration. FDA warning on raw oysters. *AIDS Treat News* 1995;229:6.
- Bowdre JH, Hull JH, Cocchetto DM. Antibiotic efficacy against *Vibrio vulnificus* in the mouse: Superiority of tetracycline. *J Pharmacol Exp Ther* 1983;225:595-8.
- Chuang YC, Liu JW, Ko WC, Lin KY, Wu JJ, Huang KY. In vitro synergism between cefotaxime and minocycline against *Vibrio vulnificus*. *Antimicrob Agents Chemother* 1997;41:2214-7.
- Chuang YC, Ko WC, Wang ST, et al. Minocycline and cefotaxime in the treatment of experimental murine *Vibrio vulnificus* infection. *Antimicrob Agents Chemother* 1998;42:1319-22.
- Clark RB. Antibiotic susceptibilities of the *Vibrionaceae* to meropenem and other antimicrobial agents. *Diagn Microbiol Infect Dis* 1992;15:453-5. (Erratum in 1993;16:352).
- Halow KD, Harner RC, Fontenelle LJ. Primary skin infections secondary to *Vibrio vulnificus*: The role of operative intervention. *J Am Coll Surg* 1996;183:329-34.
- Janda JM, Abbott SL. Infections associated with the genus *Edwardsiella*: The role of *Edwardsiella tarda* in human disease. *Clin Infect Dis* 1993;17:742-8.
- Jonsson I, Monsen T, Wistrom J. A case of *Plesiomonas shigelloides* cellulitis and bacteraemia from northern Europe. *Scand J Infect Dis* 1997;29:631-2.
- Gopal V, Burns FE. Cellulitis and compartment syndrome due to *Plesiomonas shigelloides*: A case report. *Mil Med* 1991;156:43.
- Heckerling PS, Stine TM, Pottage JC Jr, Levin S, Harris AA. *Aeromonas hydrophila* myonecrosis and gas gangrene in a nonimmunocompromised host. *Arch Intern Med* 1983;143:2005-7.
- Wolff RL, Wiseman SL, Kitchens CS. *Aeromonas hydrophila* bacteremia in ambulatory immunocompromised hosts. *Am J Med* 1980;68:238-42.
- Rocha MP, Fontoura PR, Azevedo SN, Fontoura AM. *Erysipelothrix* endocarditis with previous cutaneous lesion: Report of a case and review of the literature. *Rev Inst Med Trop Sao Paulo* 1989;31:286-9.
- Brooke CJ, Riley TV. *Erysipelothrix rhusiopathiae*: Bacteriology, epidemiology and clinical manifestations of an occupational pathogen. *J Med Microbiol* 1999;48:789-99.
- Jernigan JA, Farr BM. Incubation period and sources of exposure for cutaneous *Mycobacterium marinum* infection: Case report and review of the literature. *Clin Infect Dis* 2000;31:439-43.
- Weinstein MR, Litt M, Kertesz DA, et al. Invasive infections due to a fish pathogen, *Streptococcus iniae*. *S. iniae* Study Group. *N Engl J Med* 1997;337:589-94.
- Lau SK, Woo PC, Tse H, Leung KW, Wong SS, Yuen KY. Invasive *Streptococcus iniae* infections outside North America. *J Clin Microbiol* 2003;41:1004-9.