

THE EFFECT OF ROGUE OVARIOLES ON PARITY DIAGNOSIS IN *CULISETA INORNATA*
AND *CULEX TARSALIS* (DIPTERA: CULICIDAE)

A Thesis

Submitted to the Faculty

of

Graduate Studies

by

Andrew Swinburne Oram Fox

In Partial Fulfilment of the

Requirements for the Degree

of

Master of Science

Department of Entomology

University of Manitoba

December 1992



National Library
of Canada

Acquisitions and
Bibliographic Services Branch

395 Wellington Street
Ottawa, Ontario
K1A 0N4

Bibliothèque nationale
du Canada

Direction des acquisitions et
des services bibliographiques

395, rue Wellington
Ottawa (Ontario)
K1A 0N4

Your file *Votre référence*

Our file *Notre référence*

The author has granted an irrevocable non-exclusive licence allowing the National Library of Canada to reproduce, loan, distribute or sell copies of his/her thesis by any means and in any form or format, making this thesis available to interested persons.

L'auteur a accordé une licence irrévocable et non exclusive permettant à la Bibliothèque nationale du Canada de reproduire, prêter, distribuer ou vendre des copies de sa thèse de quelque manière et sous quelque forme que ce soit pour mettre des exemplaires de cette thèse à la disposition des personnes intéressées.

The author retains ownership of the copyright in his/her thesis. Neither the thesis nor substantial extracts from it may be printed or otherwise reproduced without his/her permission.

L'auteur conserve la propriété du droit d'auteur qui protège sa thèse. Ni la thèse ni des extraits substantiels de celle-ci ne doivent être imprimés ou autrement reproduits sans son autorisation.

ISBN 0-315-81704-6

Canada

THE EFFECT OF ROGUE OVARIOLES ON PARITY DIAGNOSIS
IN CULISETA INORNATA AND CULEX TARSALIS (DIPTERA: CULICIDAE)

BY

ANDREW SWINBURNE ORAM FOX

A Thesis submitted to the Faculty of Graduate Studies of the University of Manitoba in
partial fulfillment of the requirements for the degree of

MASTER OF SCIENCE

© 1992

Permission has been granted to the LIBRARY OF THE UNIVERSITY OF MANITOBA to
lend or sell copies of this thesis, to the NATIONAL LIBRARY OF CANADA to microfilm
this thesis and to lend or sell copies of the film, and UNIVERSITY MICROFILMS to
publish an abstract of this thesis.

The author reserves other publication rights, and neither the thesis nor extensive extracts
from it may be printed or otherwise reproduced without the author's permission.

To Lise-Marie

ACKNOWLEDGEMENTS

The members of the examining committee, my advisor Dr. Reinhart Brust, Dr. Terry Galloway and Dr. Erwin Huebner, have inspired me throughout the development of this thesis by their enthusiasm for their respective disciplines, and by their kindness and generosity. Thank you Dr. Brust for your guidance and for your great patience, which is invaluable.

Andrew Mackay and Daryl Wright provided technical assistance throughout this project. Other people who made significant contributions both directly and indirectly include, Allen Patterson, Photographic Services (U. of M.), staff at the Interlibrary Loans Office (U. of M.), Edna and Arcadius Perron, Joy Fox, Page and John Porter, and many others who provided assistance, encouragement and friendship.

To my wife Lise-Marie, thank you for your selfless and unfailing support.

I am indebted to Dr. M.T. Gillies for the loan of his translations of the Russian literature, which provided the backbone for much of the discussion and interpretation of results. Financial support was provided by Research Council of Canada grant no. 311 1119 03 awarded to Dr. R.A. Brust, and by a Graduate Student Fellowship (U. of M., 1991-1992).

ABSTRACT

Polovodova equated the maximum number of dilatations in any ovariole with the total number of gonotrophic cycles (parity status) completed by a mosquito. Two major obstacles to accurate parity diagnosis are the lack of diagnostic ovarioles (which indicate parity status), and the presence of rogue ovarioles (which cause the overestimation of parity status). Ovarioles with more than six pedicel cells and no dilatation, and ovarioles with different numbers of dilatations were counted in nulliparous and known parous *Culiseta inornata* (Williston) and *Culex tarsalis* Coquillett. In *Cs. inornata* 50% of nullipars (≤ 12 days old), 42% of 1-pars and 28% of 2-pars had at least one rogue ovariole. Ten per cent of 2-pars had no diagnostic ovariole. In *Cx. tarsalis* 68% of nullipars (≤ 10 days of age) had at least one rogue ovariole. The ratio and frequency of ovariole types were used to develop parity diagnostic criteria. These criteria accounted for the occurrence of rogue ovarioles which thwart the application of Polovodova's method. The use of diagnostic criteria and separation indicators to separate nullipars and known pars in blind tests, was 95% and 100% effective for *Cs. inornata* and *Cx. tarsalis* respectively.

TABLE OF CONTENTS

CHAPTER I. GENERAL INTRODUCTION	1
CHAPTER II. LITERATURE REVIEW	3
<i>Polovodova's method</i>	3
<i>Anatomy of the mosquito ovary</i>	3
<i>Dynamic events in the mosquito ovary</i>	5
<i>Abortive oogenesis</i>	5
<i>Normal oogenesis and ovulation</i>	7
<i>Follicle resorption in nullipars</i>	10
<i>Ovariole types found in nulliparous and parous</i> <i>mosquitoes</i>	11
<i>The dilatation method and age grading techniques</i>	12
<i>Diagnostic methods</i>	12
<i>Dissection methods</i>	15
<i>The biology of <i>Culiseta inornata</i></i>	16
<i>The biology of <i>Culex tarsalis</i></i>	18
CHAPTER III. THE EFFECT OF ROGUE OVARIOLES ON PARITY DIAGNOSIS IN <i>CULISETA INORNATA</i> (DIPTERA: CULICIDAE)	22
Abstract	22
Introduction	22
Materials and Methods	25
<i>Rearing conditions</i>	25
<i>Dissection method and the blind test</i>	26
Definitions	28
Results	31
<i>Follicle resorption (21°C) in 6-34 day old nullipars</i>	31
<i>Nullipars (≤ 12 days old), and known 1-pars, 2-pars</i> <i>and 3-pars</i>	31
<i>Autogeny and fecundity</i>	32
<i>Ovariole composition: nullipars, 1-pars, 2-pars and 3-</i> <i>pars</i>	33
<i>Diagnostic criteria</i>	34
<i>Separation indicators</i>	34
<i>The blind test</i>	35
Discussion	36
<i>The problem of age underestimation and age</i> <i>overestimation</i>	36
<i>Diagnostic ovarioles and the diagnostic index</i>	37
<i>Development and application of the diagnostic</i> <i>criteria</i>	41
<i>The recognition of rogue ovarioles</i>	43
<i>Ovariole types, terms and definitions</i>	43
<i>The choice of dissection method</i>	46
<i>The mode of ovulation: conflicting hypotheses</i>	47
<i>Natural conditions</i>	49

CHAPTER IV. THE EFFECT OF ROGUE OVARIOLES ON PARITY DIAGNOSIS IN <i>CULEX TARSALIS</i> (DIPTERA: CULICIDAE)	60
Abstract	60
Introduction	60
Materials and methods	62
Results	64
<i>Follicle resorption in 2-34 day old nullipars</i>	64
<i>Nullipars (≤ 10 days old) and known 1-pars and 2-pars</i>	65
<i>Ovariole composition: nullipars, 1-pars and 2-pars</i>	66
<i>Diagnostic criteria</i>	67
<i>The blind test</i>	68
<i>CO₂-light-trap study</i>	69
Discussion	70
CHAPTER V. GENERAL DISCUSSION	83
REFERENCES	86
APPENDICES	93

LIST OF TABLES

CHAPTER III.

- Table 1. Mean number of ovarioles in sucrose-fed nulliparous *Culiseta inornata* (10/day) over a 34 day period ($21\pm 0.2^{\circ}\text{C}$; 16L:8D). 51
- Table 2. Mean number of ovarioles in known nulliparous, 1-parous, 2-parous and 3-parous *Culiseta inornata*. 52
- Table 3. Mean number of eggs laid and number of ovarioles in successive gonotrophic cycles of *Culiseta inornata* ($21\pm 1^{\circ}\text{C}$; 17L:7D). 53
- Table 4. Per cent composition of 1-dilated ovarioles in nulliparous and 1-parous *Culiseta inornata* (21°C). 54
- Table 5. Per cent composition of 2-dilated ovarioles in 1-parous, 2-parous and 3-parous *Culiseta inornata*. 55

CHAPTER IV.

- Table 1. Mean number of ovarioles in sucrose-fed nulliparous *Culex tarsalis* (10/day) over a 34 day period ($21\pm 0.2^{\circ}\text{C}$; 16L:8D). 76
- Table 2. Mean number of ovarioles in known nulliparous, 1-parous and 2-parous *Culex tarsalis*. 77
- Table 3. Per cent composition of 1-dilated ovarioles in nulliparous and 1-parous *Culex tarsalis*. 78
- Table 4. Per cent composition of 2-dilated ovarioles in nulliparous, 1-parous and 2-parous *Culex tarsalis*. 79
- Table 5. Parity status of *Culex tarsalis* CO_2 -light trapped at Glenlea, Manitoba (n=149). 80

LIST OF PLATES

CHAPTER II.	
Plate I.	A comparison of the old and new hypotheses concerning the formation of ovarioles dilatations 20
CHAPTER III.	
Plate II.	Photomicrographs of <i>Culiseta inornata</i> ovarioles 56
Plate III.	Photomicrographs of <i>Culiseta inornata</i> ovarioles 58
CHAPTER IV.	
Plate IV.	Photomicrographs of <i>Culex tarsalis</i> ovarioles 81

LIST OF APPENDICES

Appendix I	
Nulliparous (21°, 24°C) and 1-parous (21°C) <i>Culiseta inornata</i> . . .	93
Table 1. Mean number of ovarioles in sucrose-fed nulliparous <i>Culiseta inornata</i> over a 24 day period (24±0.2°C; 16L:8D).	94
Appendix II	
The separation of 1-parous from 2-parous <i>Culiseta inornata</i>	95
Appendix III	
The effect of random oogenesis on the frequency of diagnostic ovarioles	96
Appendix IV	
Nulliparous <i>Culex restuans</i> (21°C)	97
Table 1. Mean number of ovarioles in sucrose-fed nulliparous <i>Culex restuans</i> (10/day) over a 34 day period (21±0.2°C; 16L:8D). . .	98
Appendix V	
Plate I. Ovarioles in multiparous autogenous-anautogenous <i>Culiseta inornata</i>	99

CHAPTER I

GENERAL INTRODUCTION

Vectorial capacity is an estimate of the daily rate at which vector borne diseases are spread. The parameters used to reach this estimate include the survival rate of the disease vector (Dye 1992). Anautogenous mosquitoes, which require blood to develop eggs, are often potential vectors of disease organisms which they acquire during blood feeding and transmit to other hosts during subsequent meals.

Parous females are females which have completed one or more oviposition cycles, and may be subdivided into 1-parous to n-parous categories (Bertram 1962). These females are important in epidemiology because they provide a measure of blood feeding events and potential infectivity. The proportion of parous to nulliparous females (the parous rate) is an appropriate measure in epidemiology for the estimation of mosquito survival (Dye 1992).

The estimation of vectorial capacity is thwarted by physiological and behavioural factors associated with the vector, and problems with mathematical models (Clements and Paterson 1981, Dye 1992). Problems directly associated with oogenesis include the assumption that each oviposition cycle represents a single blood feeding event (Dye 1992). This assumption is incorrect in autogenous females that develop the first egg batch without blood (Bellamy and Corbet 1973), and in some anopheline species which require more than one blood meal to develop the first egg batch (Gillies 1956).

The current study focuses on the problems associated with Polovodova's (1949) dilatation method which is used to estimate the proportion of parous mosquitoes in a population. Polovodova's (1949) method is based on ovarian changes by which a female may be identified as 1- to n-parous. The degree of parity is useful for the determination of changes in survivorship with gonotrophic age (Gillies and Wilkes 1965).

The primary objective was to test the efficacy of Polovodova's (1949) method for *Culiseta inornata* (Williston) and for *Culex tarsalis* Coquillett. These species are potential vectors of Western Equine Encephalomyelitis virus in Manitoba, and gonotrophic aging of vector mosquitoes is desirable when virus transmission is likely. Counting dilatations in some *Culex* species may result in an overestimation of parity status (the number of oviposition cycles completed), because some nullipars are known to resorb ovarian follicles and form dilatations prior to blood feeding (Knight and Nayar 1982). Therefore the following was undertaken: an evaluation of follicle resorption in nulliparous *Cs. inornata* and *Cx. tarsalis*, a record of ovariole types (including diagnostic ovarioles) in females of known oviposition history, and the appraisal and modification of Polovodova's (1949) method.

CHAPTER II

LITERATURE REVIEW

Polovodova's method

Polovodova (1949) found that the maximum number of dilatations in any ovariole was equivalent to parity status (the number of oviposition cycles completed) in *Anopheles maculipennis* Meigen. Hayashi and Kurihara (1965), Rosay (1969), Samarawickrema (1962), Trueman and McIver (1983), and others, supported Polovodova's findings for a variety of *Culex*, *Anopheles*, *Aedes* and *Mansonia* species with known oviposition history. Polovodova's (1949) method is the only age grading method to date, which can determine the precise parity status of parous mosquitoes. Information on the parity status of mosquitoes is used to estimate adult survival between oviposition events (Dye 1992).

Anatomy of the mosquito ovary

In non-gravid females, the paired ovaries are situated in the region of the fifth abdominal segment. The ovaries of gravid females occupy a large portion of the perivisceral sinus. The ovarioles, which are the egg producing units of the ovary, are arranged around the calyx (central tube of the ovary). The ovary is enclosed by an outer membrane (ovarian sheath), which terminates where the calyx merges with the lateral oviduct. The lateral oviducts of each ovary expand to form the ampullae and then merge to form the common oviduct. The spermathecae and the accessory glands open into the common oviduct. The ovary is supplied with air via two tracheal trunks which are linked to the fifth and sixth

abdominal spiracles. The trunks split a number of times before they merge with the ovary (Bertram 1962, Detinova 1962, Giglioli 1963a, Shalaby 1971).

The number of ovarioles varies between individuals and species, Giglioli (1964) found a range of 48-97 ovarioles per ovary in *Anopheles melas* Theobald, and Clements and Boocock (1984) found 50-60 ovarioles per ovary in *Aedes aegypti* (Linnaeus). Each ovariole has an anterior germarium which produces one ovarian follicle at a time. Follicle production and egg development are dependent on hormonal and nutritional factors (Beckemeyer and Lea 1980, Clements and Boocock 1984) and in anautogenous species, which require blood for egg development, the production of follicles is synchronous throughout the ovary (Bertram 1962). The follicle has a follicular epithelium which encloses a syncytium of seven trophocytes and an oocyte. Mature unfed females have, in each ovariole, at least two follicles arrested at different stages of development. The primary follicle is connected to the calyx by a cellular stalk (the pedicel), and the primary and secondary follicles are separated by a cellular connecting stalk (the primary connecting stalk). In some species the primary connecting stalk is poorly defined prior to blood feeding (personal observation). The germarium, follicles, connecting stalk and pedicel are covered by a thin elastic membrane named the tunica, and each ovariole (follicular tube) is covered by a taut membranous ovariole sheath. The ovariole sheath is interdispersed with nuclei, and is broadly joined to the calyx around the pedicel (Bertram 1962, Giglioli 1964, Nicholson 1921).

Most of the oocytes develop into mature eggs after gonioactive

females imbibe sufficient blood. After oviposition the female is 1-parous as opposed to nulliparous. As the eggs develop, the next follicle in each ovariole develops to a resting stage prior to the subsequent cycle (Bertram 1962).

Dynamic events in the mosquito ovary

Abortive oogenesis

The degeneration of a follicle in one ovariole, while an egg develops simultaneously in another ovariole, is termed abortive oogenesis. This is a common phenomenon in mosquito oogenesis (Detinova 1962). The onset of follicle degeneration is characterized by changes in the follicular epithelium, which becomes columnar and develops cytoplasmic inclusions named luteali (Lange and Khok 1981). Yolk disperses throughout the follicle when the oocyte begins to break down (Watts and Smith 1978). The degenerating follicle eventually forms a dilatation, which Bertram (1962) defines as a localized swelling in the ovariole at the previous site of a follicle. Lange and Khok (1981) described the dilatations formed from abortive oogenesis (Detinova 1962) as gonotrophic dilatations. Dilatations often contain a relic which is a compacted mass of follicular debris that persists after the degeneration and subsequent resorption of most of the follicle (Bertram 1962). Some authors use the term yellow body or corpus luteum to describe the relic. Polovodova (1949) used the terms yellow body and thickening (dilatation) interchangeably. Successive cycles of abortive oogenesis in the same ovariole result in a series of dilatations separated by connecting stalks. There is one dilatation for each cycle of abortive oogenesis.

The first dilatation is the primary dilatation and this is connected to the calyx by the pedicel (Detinova 1962, Hoc and Charlwood 1990).

Sokolova (1981) reported that abortive oogenesis occurred in 0.7-30.0% of ovarioles in *Aedes caspius dorsalis* Meigen, a species that has 72-129 ovarioles per ovary.

Nicholson (1921) speculated that follicle degeneration (autodigestion) may be a response to follicle crowding. Clements and Boocock (1984) believed that extensive degeneration of follicles in anautogenous mosquitoes is related to a nutritional deficiency associated with partial blood meals, and may be compounded by the effects of any nutritional deficiency in larval development. They found that, on average, 27.2% of follicles degenerated in *Ae. aegypti* within 33 hours of blood feeding. The structural integrity of ovarian follicles may be dependent on juvenile hormone. Gwadz and Spielman (1973) reported extensive follicle degeneration in blood-fed *Ae. aegypti* which had been allatectomised shortly after emergence. This did not occur in allatectomised females treated with synthetic juvenile hormone.

Detinova (1962) defined abortive oogenesis as occurring in blood-fed gonoactive females. It would be reasonable to extend the definition to include degenerating follicles in females that were developing eggs autogenously. Extensive follicle degeneration is found in autogenous-anautogenous *Culex tarsalis* Coquillett, when a small batch of eggs is developed without blood in the first gonotrophic cycle (Bellamy and Corbet 1973).

Normal oogenesis and ovulation

Normal oogenesis is the development of an oocyte into a mature egg (Detinova 1962). Christophers (1911) divided oogenesis into five stages of development which were subdivided descriptively but not numerically. Christophers' stages have been redefined by a number of researchers (Clements and Boocock 1984). Watts and Smith (1978) divided normal oogenesis into ten stages. Watts and Smith's (1978) stages are not very different from Christophers' (1911) progressive description of oogenesis, except that the transition from stage 2-3 is modified and precisely defined. This refinement proved useful for consistent classification of females which were in oogenic arrest (personal observation).

Follicles of anautogenous gonotrophic mosquitoes are in developmental (oogenic) arrest between blood meals. Oogenic arrest is governed by the endocrine system (Clements and Boocock 1984). Nicholson (1921) reported that oogenic arrest was characterized by a cessation of mitotic divisions in the follicular epithelium. Mitosis resumes after blood feeding (Laurence and Simpson 1974).

There is no disagreement in the literature concerning the formation of dilatations during abortive oogenesis. This is not the case for dilatations which may result from normal oogenesis. Beklemishev *et al.* (1959), Bertram (1962), Giglioli (1965), Gillies and Wilkes (1965), Rosay (1969), Samarawickrema (1962), among others, believed that serial dilatations form from successive cycles of normal oogenesis (old hypothesis). The relics in such dilatations are composed of degenerated, compacted follicular epithelium. According to the old hypothesis,

ovulation (the passage of the egg from the ovariole to the calyx) occurs via the pedicel in the first cycle, and via the connecting stalk and pedicel in the second cycle etc..

Samarawickrema (1962) reported that ovarioles which have recently ovulated (sacculate ovarioles), have the same appearance in 1-pars as they do in multipars (a point generally agreed upon in the literature). As the sac shrinks, most of the follicular debris as well as relic material from previously formed dilatations, is ejected into the calyx. The dilatations and connecting stalks formed in previous cycles of normal or abortive oogenesis are then reformed. Samarawickrema (1962) reported that the pedicel was the last part of the sac to reform whereas Beklemishev *et al.* (1959) reported that it was the first.

If this description of ovulation was accurate, ovarioles with the same number of dilatations as oviposition cycles would be numerous. However, virtually all studies on dilatations report a scarcity of such ovarioles in gonotrophically older females. This could be the result of a number of ovarioles remaining inactive during each gonotrophic cycle as was suggested by Detinova (1949). However, there are more plausible suggestions to explain the reduction in diagnostic ovarioles.

Lange and Khok (1981) studied *Anopheles*, *Aedes* and *Culex* species. They do not use the term dilatation in association with normal oogenesis, and report that after ovulation each sac shrinks down to the calyx and forms a single terminal sac with a relic. This type of ovariole has the same appearance after any number of cycles of normal oogenesis. If normal oogenesis were to follow abortive oogenesis in the same ovariole, then a single terminal sac would result and not two

distinct dilatations as reported by Beklemishev *et al.* (1959). Giglioli (1965) believed that abortive oogenesis, once it had occurred in an ovariole of *An. melas*, was likely to reoccur in that ovariole in subsequent cycles. Giglioli (1965) gave evidence to support the new hypothesis in *An. melas*, in which terminal sacs are referred to as basal dilatations. However, Giglioli's (1965) study supported the old hypothesis for other species. The new hypothesis is supported by Anufrieva and Artem'ev (1981), Gillies (personal communication), Hoc and Charlwood (1990), Sokolova (1981,1983) and Sokolova and Lange (1989).

A diagrammatic representation of ovarioles after the second gonotrophic cycle, according to the old and the new hypotheses, is given in Fig. 1. After the second cycle the old hypothesis accounts for one basic ovariole type, whereas the new hypothesis accounts for three. The scheme presented in Fig. 1 does not include the effect of ovarioles resting in the first, second, or both cycles, and assumes that normal oogenesis is a random event *i.e.*, each follicle in a given cycle has an equal probability of completing normal oogenesis (Appendix III). After ovulation (old hypothesis) the pedicel would not be cellular whereas a pedicel in an ovariole which had not ovulated, but had completed abortive oogenesis, may contain degenerating cells. The illustrations in the literature are varied in this regard, therefore the pedicels were standardized in Fig. 1 in order to emphasize the difference between the two hypotheses.

The mode of ovulation is inadequately addressed by the new hypothesis. Lange and Khok (1981) simply state that the pedicel disappears during ovulation, and refer to Lehane and Laurence (1978).

Lehane and Laurence (1978) described ovulation in *Ae. aegypti* as a process which does not involve the pedicel. Instead of passing through the pedicel, which was a solid core of cells in nullipars, the primary follicles lengthened and pushed into the calyx. The basement membrane of the follicle and the basement membrane of the calyx became indistinguishable, and breaks appeared through which the eggs protruded. Lehane and Laurence's (1978) ultrastructural study was thorough, but it was limited to one species and may have been limited to a proportion of ovarioles in each female. Hoc (1975) indicated that ovulation occurred via the pedicel, and the pedicel remained expanded as a sac. This possibility was also discussed by Spencer (1979). Giglioli (1965) found that in *An. melas*, the pedicel did not reform after ovulation, and the follicular debris in the shrinking sac was trapped above an ovariole sphincter which closed after ovulation.

Follicle resorption in nullipars

Follicle degeneration is common in older (calendar age) sucrose-fed mosquitoes (Lange and Khok 1981, Sokolova and Lange 1989, and others) and is extensive in *Culex* species (Table 1 in Knight and Nayar 1982). The proportion of ovarioles with dilatations and the number of dilatations per ovariole increases as nullipars age. Clements and Boocock (1984) found that 1% of ovarioles in 3-5 day old *Ae. aegypti* had degenerating follicles. Nayar and Knight (Table 1 in Nayar and Knight 1981a) found that every female in a sample of sucrose-fed, 16 day old F₁ *Culex nigripalpus* Theobald had at least one 2-dilated ovariole.

Lange and Khok (1981) used the term agonotrophic, to describe

dilatations formed from follicles which degenerate before or after the gonotrophic cycle. Sokolova (1981) used the term pregonotrophic to describe dilatations which form during the first day of adult life. Ovarioles with pregonotrophic dilatations do not develop the secondary follicle (Sokolova and Lange 1989). Sokolova and Lange (1989) suggested that agontrophic degeneration could result from genetic defects in later stages of follicle development, or from changes in hormone level associated with female age. It is not known why these ovarioles degenerate and continue to produce new follicles while other follicles are resting.

Sokolova (1981) found that 97% of *Ae. caspius dorsalis* had at least one ovariole with a pregonotrophic dilatation, and older sucrose-fed females had agontrophic dilatations in 0.5-1.0% of their ovarioles.

Ovariole types found in nulliparous and parous mosquitoes

Sokolova (1981) described four basic ovariole types: normal, miniature, aborting and club-shaped ovarioles. Normal and miniature ovarioles differ only in size. Aborting ovarioles are in the process of resorbing a follicle and club-shaped ovarioles have no follicle. Ovarioles may have one or more dilatations (pregonotrophic, agontrophic, gonotrophic), and the germarium may be functional or non-functional.

Hoc and Charlwood (1990) described four ovariole types in parous mosquitoes: ovarioles which have completed abortive oogenesis in every cycle, ovarioles which have ovulated in every cycle, ovarioles which have completed normal oogenesis and abortive oogenesis in different

cycles, and dwarf ovarioles which are smaller than the average ovariole. Hoc and Charlwood (1990) did not use dwarf ovarioles as indicators of parity status, whereas Gillies and Wilkes (1965) found them to be useful.

Detinova (1949) described three ovariole types found in the first gonotrophic cycle: ovarioles committed to normal oogenesis, ovarioles committed to abortive oogenesis, and ovarioles that are quiescent.

Ovarioles with cellular pedicels are a distinguishing feature of the nulliparous ovary (Hoc 1975). Giglioli (1965) found that the pedicels of newly emerged *An. melas* had 10-12 cuboidal cells. Gozhenko (1980) found that the pedicel in *Mansonia richiardii* (Ficalbi) had 8-18 cells and Hoc (1975) found that nulliparous *Culex pipiens molestus* Forskal and *An. maculipennis* had pedicels of between 7-20 cells and 15-22 cells respectively. Sokolova and Lange (1989) reported that ovarioles with pregonotrophic and agonotrophic dilatations have cellular pedicels, whereas ovarioles with gonotrophic dilatations (in pars) have degenerated pedicels.

The dilatation method and age grading techniques

Diagnostic methods

Polovodova's (1949) method for assessing parity status is unaffected by Lange and Khok's (1981) reappraisal of ovarian dynamics. This is expected since Polovodova's (1949) method was based on careful observation rather than hypothetical projection. Liu (1968) used *Culex pipiens pallens* Coquillett of known oviposition history to test the efficacy of Polovodova's (1949) method, and examined 15-30 ovarioles in

1-pars and all the ovarioles in 2- to 7-pars. Liu (1968) found that there was an underestimation of physiological age when females were more than 2-parous. In a similar study of *Aedes albopictus* Skuse, Liu (1968) documented one 2-par with a 3-dilated ovariole. Reports of age underestimation using Polovodova's (1949) method are more frequent than reports of age overestimation. Instances of age overestimation have been reported in *Ae. aegypti* (Rosay 1969) and *Anopheles gambiae* Giles (Gillies and Wilkes 1965).

Lange and Khok (1981) concluded that the only ovariole type which represents the true age of a female, is one which has undergone abortive oogenesis in every cycle and therefore has an intact pedicel. The practical value of this diagnostic ovariole may be questioned in older females if Detinova's (1949) observations, that some ovarioles do not participate in all cycles, is widespread. Lange and Khok (1981) call the proportion of diagnostic ovarioles in each female the index of diagnostic reliability. This index does not quantify the percentage of females which are subject to age underestimation due to a lack of diagnostic ovarioles. Sokolova (1983) reported that the index of diagnostic reliability in 2-parous *Anopheles messeae* Falleroni, *Ae. aegypti* and *Aedes punctor* Kirby, was 3.6%, 8.5% and 14.9% respectively.

Anufrieva and Artem'ev (1981) counted ovarioles with a terminal sac and one less dilatation as well as diagnostic ovarioles. From a practical perspective this was identical to Polovodova's (1949) method. Anufrieva and Artem'ev (1981) calculated finite values for the minima of parity diagnostic ovarioles in 1- to 4-parous *Anopheles pulcherrimus* Theobald and *Anopheles hyrcanus* (Pallas). These minima were extrapolated

from fecundity data and the index of diagnostic reliability.

Photomicrographs of diagnostic ovarioles with a substantial number of clearly separated dilatations, are common in the literature. These include an 8-dilated ovariole in *An. gambiae* (Gillies and Wilkes 1965), a 5-dilated ovariole in *Anopheles coustani* Laveran (Giglioli 1965) and a 7-dilated ovariole in *Anopheles farauti* Laveran (Spencer 1979). Dilatations are variable in appearance, hence their classification is somewhat subjective. The classification of an 8-dilated ovariole of *Culex annulirostris* Skuse photographed by Kay (1979), represents an overestimation of the number of dilatations visible (personal opinion). Proximal dilatations in the form of clusters have been reported by Liu (1968) and Spencer (1979).

Sokolova (1983) proposed the combined (combinative) method for parity diagnosis. The combined method relies on the agreement in diagnosis of ovarioles with different proportions of granulation zones, vestigial dilatations and gonotrophic dilatations. Sokolova (1983) believed that granulation zones were formed from the fusion of sacs during successive ovulation events, and that each granulation zone, in the same ovariole, represented a different gonotrophic cycle. Sokolova (1983) was able to differentiate up to three granulation zones in the same ovariole using the intraovarian oil injection method (see below). Vestigial dilatations were torn from the follicular tube when normal oogenesis followed abortive oogenesis in the same ovariole. Vestigial dilatations were found between the follicular tube and the ovariole sheath (Sokolova 1983). Lumen cells were also found in this region of the ovariole (Sokolova 1981). Theoretically, the ovarioles which are

diagnostic for a 2-parous female using the combined method are: ovarioles with two granulation zones, ovarioles with one granulation zone and one vestigial dilatation, ovarioles with one granulation zone and one gonotrophic dilatation, and ovarioles with two gonotrophic dilatations. Granulation zones and dilatations were used by Spencer (1979) to diagnose wild *An. farauti*.

Dissection methods

Beklemishev *et al.* (1959) used two needles, physiological saline, and a dissecting microscope (40X magnification) to dissect the ovaries of mosquitoes. Once the ovaries were removed, the ovarian sheath was torn to reveal the ovarioles which remained attached to the calyx. The ovarioles were individually straightened by stretching them with one needle while the other needle was used to secure the calyx. The dilatations were then visible and could be counted. Giglioli (1963b) modified this technique by staining with aqueous gentian violet, which highlighted a broad range of ovarian structures. Giglioli (1963b) found that a dissecting medium of saturated sodium chloride permitted the ovariole to be stretched, and then prevented it from contracting. The medium also reduced the spread of yolk from rupturing follicles, however the stain and the saline were immiscible. Giglioli (1963b) developed a knee focusing device which left both hands free to stretch the ovarioles.

Hitchcock (1968) held the apical end of the ovary with tweezers and then flicked the tweezers with a needle until all the ovarioles had dispersed throughout the dissecting medium. If the tweezers and needle

were not sufficiently elastic, the pedicel broke at the follicle rather than the calyx. The preparation was covered with a glass coverslip and viewed using transmitted light.

Spencer (1979) used a dissecting medium of saline, glycerin and formalin. Whole mounts of ovaries were flattened by applying a glass coverslip, and were viewed with phase contrast microscopy.

Lange *et al.* 1981 developed the intraovarian oil injection technique. The ovaries were removed in a solution of 1 part neutral red to 8000 parts of physiological saline. Sunflower oil was injected into the lateral oviduct using a fine pipette with a matchstick plunger. If the common oviduct was large (parous females) then both ovaries were filled at once. Once the ovaries expanded 2-3 times their original length, they were slit lengthways and the ovarioles spread out across the surface of the saline in the escaping oil. The saline was partly drawn off and the preparation was covered with a vaseline-supported coverslip and viewed using transmitted light and a 40X objective. This method enabled the maximum number of ovarioles to be analysed in a relatively undamaged state. Wilkes (Gillies, personal communication) found the method to be excellent for viewing ovarioles but was unable to perform more than ten dissections a day.

The biology of Culiseta inornata

Culiseta inornata (Williston) has only been found in North America. It is common to the prairie provinces and does not occur east of Ontario (Wood *et al.* 1979). *Culiseta inornata* has been implicated in the transmission of Western Equine Encephalomyelitis, but it is not

considered to be an important vector of the virus (McLintock and Iversen 1975).

Anderson and Gallaway (1987) found that *Cs. inornata* preferred to blood feed on large mammals. Hudson (1977a) found nulliparous and parous *Cs. inornata* with crop syrup. The highest percentage of nullipars with crop syrup (79%) occurred in early September.

Culiseta inornata is an autogenous-anautogenous species. Autogeny levels are high (>35%) in California during late December and early January (Meyer and Washino 1978, Meyer *et al.* 1982) but for the rest of the year they are generally low (Reisen *et al.* 1989). Owen (1942) and Hudson (1977a) each reared three autogenous females that laid small egg rafts.

Culiseta inornata hibernate during cold winters and aestivate during hot summers. Hudson (1979) reported that females overwinter in Alberta as unfed nullipars, in a state of reproductive diapause. Dow *et al.* (1976) believe that *Cs. inornata* which blood feed prior to hibernation in Colorado, overwinter as gravid females. Barnard and Mulla (1978) and Reisen *et al.* (1989) reported that the majority of post aestivating females were either gravid or empty parous. The hibernation of blood-fed females is an indication that *Cs. inornata* may have the potential to overwinter arboviruses (Dow *et al.* 1976).

At the end of each gonotrophic cycle *Cs. inornata* lays its eggs in rapid succession to form a free floating raft on the water surface. Owen (1942) reported seven gonotrophic cycles (from seven blood meals) in one laboratory-reared *Cs. inornata*. Gonotrophically older females had decreased fecundity. Meyer *et al.* (1982) and Reisen *et al.* (1989)

reported a maximum of four gonotrophic cycles in wild *Cs. inornata*. The difference between these extremes may be explained by age underestimation, or poor survival in the wild. Buth *et al.* (1990) reported that a maximum of three generations of *Cs. inornata* were possible in southern Manitoba.

The biology of Culex tarsalis

Culex tarsalis is common in the prairie provinces of Canada, where it is the primary epidemic vector of Western Equine Encephalomyelitis (McLintock and Iversen 1975). *Culex tarsalis* is an autogenous-anautogenous species. Brust (1991) determined the relationship between temperature, photoperiod and autogeny in *Cx. tarsalis* from southern Manitoba. Brust (1991) found that increased temperature and day length maximized autogeny. Short days suppressed autogeny at temperatures up to 28°C (but not at higher temperatures). Conversely, a temperature of 16°C suppressed the effect of long days. Brust (1991) reported autogeny levels in the field which ranged from 82% in late July to 6% in early September.

In California, newly emerged females take 2-4 days to mate and seek a host, and the gonotrophic cycle (blood-fed females) takes 4-6 days. The duration of the gonotrophic cycle is affected by temperature, and the availability of hosts and oviposition sites (McHugh 1990, Reisen *et al.* 1983, 1992). Females lay a raft of eggs on the water surface.

Culex tarsalis females overwinter as unfed, inseminated nullipars (Burdick and Kardos 1963, Mitchell 1979). Shemanchuk (1965) found female *Cx. tarsalis* overwintering in mammalian burrows. In Colorado, mark-

release-recapture of females in mines indicated a winter survival of 8.7% (Mitchell 1979). Western Equine Encephalomyelitis is not transmitted transovarially in *Cx. tarsalis* (Henderson and Brust 1977), and consequently the vector is unlikely to play a role in overwintering the virus.

Plate I. A comparison of the old and new hypotheses concerning the formation of ovariole dilatations: a diagrammatic representation of ovarioles after abortive and normal oogenesis in the first and second gonotrophic cycles.

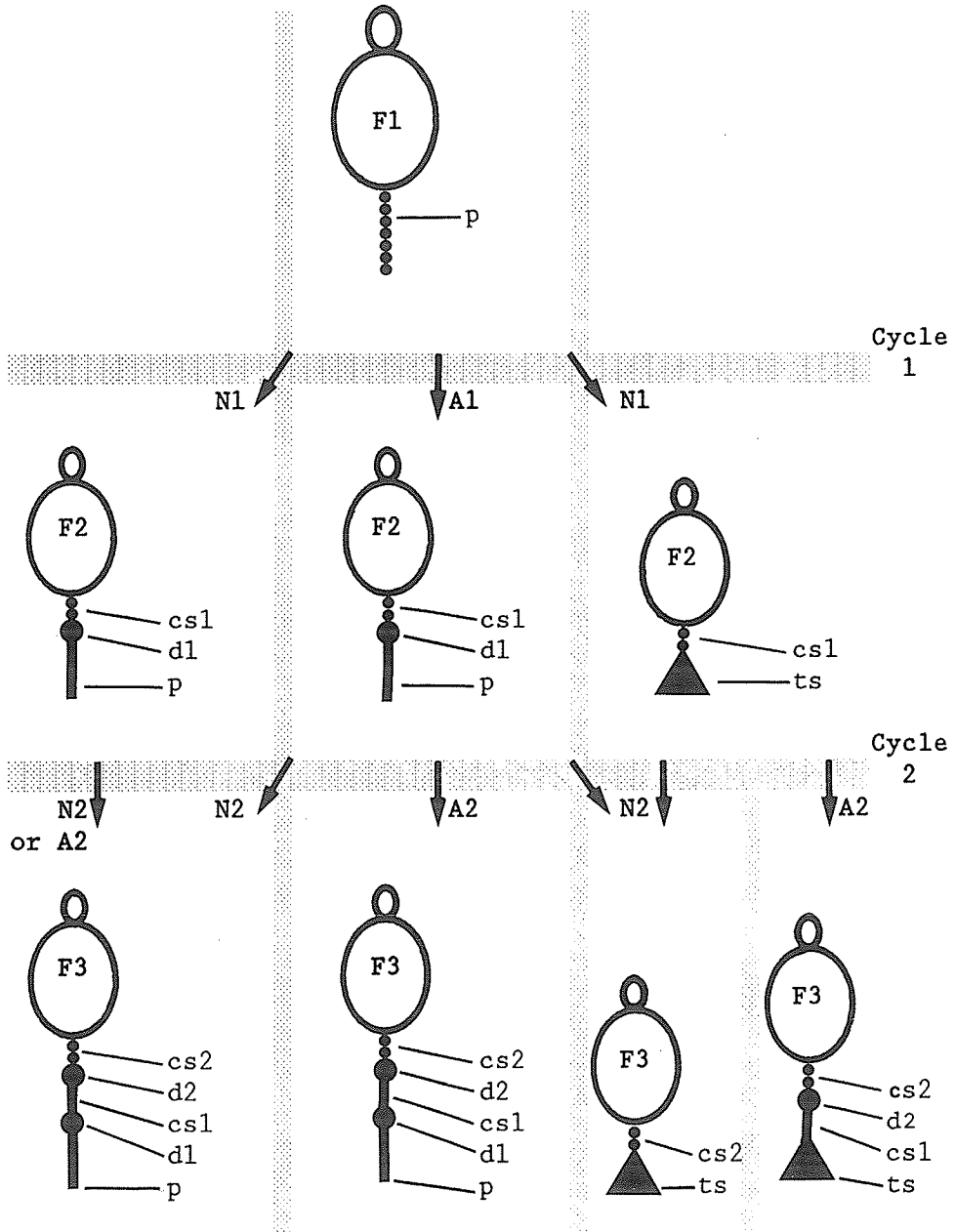
- A1 abortive oogenesis occurred in the first cycle.
- A2 abortive oogenesis occurred in the second cycle.
- cs1 primary connecting stalk.
- cs2 secondary connecting stalk.
- d1 primary dilatation.
- d2 secondary dilatation.
- F1 primary follicle.
- F2 secondary follicle.
- F3 tertiary follicle.
- N1 normal oogenesis occurred in the first cycle.
- N2 normal oogenesis occurred in the second cycle.
- p pedicel.
- ts terminal sac (basal dilatation).

The diagrams of ovarioles have been simplified and standardized from illustrations and descriptions in Beklemishev *et al.* (1959), Giglioli (1965), Samarawickrema (1962) for the old hypothesis, and Giglioli (1965), Hoc and Charlwood (1990), Lange and Khok (1981) and Sokolova (1981) for the new hypothesis. This Fig. does not account for ovarioles which fail to participate in either cycle. Primary follicles give rise to primary dilatations etc..

Old hypothesis

Hypotheses agree

New hypothesis



CHAPTER III
THE EFFECT OF ROGUE OVARIOLES ON PARITY DIAGNOSIS
IN *CULISETA INORNATA* (DIPTERA: CULICIDAE)

Abstract

The two major obstacles to accurate parity diagnosis of mosquitoes are the lack of diagnostic ovarioles (which indicate parity status), and the presence of rogue ovarioles (which cause an overestimation of parity status). Ovarioles with more than six pedicel cells and no dilatation, and ovarioles with different numbers of dilatations, were counted in known nulliparous, 1-parous and 2-parous *Culiseta inornata* (Williston). The ratio and frequency of these ovariole types were used to develop criteria for parity diagnosis. Fifty per cent of nullipars (≤ 12 days old), 42% of 1-pars and 28% of 2-pars had at least one rogue ovariole. Ten per cent of 2-pars had no diagnostic ovariole.

Introduction

Parity status is an important parameter for the estimation of female mosquito survivorship and vectorial capacity (Dye 1992). Parity status is equivalent to oviposition history. A female which has never oviposited is termed nulliparous, and a female which has laid one, or more than one batch of eggs, is termed parous. Parous females are termed 1- to n-parous based on the number of egg batches that they have laid (Bertram 1962). The counting of ovariole dilatations is the only ovarian age grading method (Polovodova 1949) which assigns parity status

within the parous group. Other methods are restricted to the separation of nullipars from pars (Detinova 1962, Hoc and Charlwood 1990).

Polovodova (1949) reported that the maximum number of dilatations (described as thickenings) in any ovariole of *Anopheles maculipennis* Meigen provided an accurate measure of individual parity status. Polovodova's method was tested by a number of researchers on a variety of Anopheline and Culicine species of known oviposition history, and in general, proved to be accurate for gonotrophically younger (1- to 3-parous) females. There was a variable, but significant trend toward underestimation of parity status in gonotrophically older females (Gozhenko 1980, Hayashi and Kurihara 1965, Liu 1968, and others). There are a few reports of age overestimation in known parous females (Gillies and Wilkes 1965, Liu 1968, Rosay 1969) and numerous reports of 1- to 3-dilated ovarioles in older, sucrose-fed nullipars (Knight and Nayar 1982, Oda *et al.* 1978, and others).

Different views are held regarding the formation of ovariole dilatations. One hypothesis (Beklemishev *et al.* 1959, Detinova 1962, Samarawickrema 1962) is that during ovulation, the egg is evacuated via the expanded pedicel. The resulting sacculate ovariole then shrinks to reform the pedicel and a dilatation. When an ovariole completes a second cycle, the sacculate ovariole shrinks to form the second dilatation and reform the primary connecting stalk, the primary dilatation and the pedicel. This pattern is repeated in subsequent gonotrophic cycles, and thus parity status can be measured by the number of dilatations in an ovariole. When abortive oogenesis occurs in place of normal oogenesis, the resulting number of dilatations per ovariole still reflects the

parity status of the female.

Lange and Khok (1981) proposed a very different hypothesis. They believe that a sacculate ovariole shrinks to form a terminal (basal) sac. The ovariole and its single terminal sac has the same appearance after one, or any number of egg producing cycles (normal oogenesis). Dilatations formed in previous cycles by abortive oogenesis, disappear after a subsequent cycle of normal oogenesis in that ovariole, leaving a single terminal sac. They believed that accurate parity assessment depends on finding ovarioles which have completed abortive oogenesis in every cycle. These ovarioles may be recognized by their intact pedicel.

The latter hypothesis explains the rapid reduction in the number of diagnostic ovarioles which regularly occurs with increased parity status. Lange and Khok's (1981) hypothesis is further supported by Anufrieva and Artem'ev (1981), Hoc and Charlwood (1990) and Sokolova (1981, 1983).

The objectives of the current study were to assess the extent of follicle resorption in nulliparous *Cs. inornata* (Williston), and to determine the frequency of diagnostic ovarioles and other ovariole types in nullipars, 1-pars, 2-pars and 3-pars of known oviposition history. The results were used to develop base-line criteria for parity diagnosis, thereby reducing the potential for diagnostic error associated with rogue ovarioles.

Materials and Methods

Rearing conditions

Adults were reared from 136 egg rafts collected from artificial pools at Glenlea, Manitoba, using the methods described by Brust (1990). The study was begun in June 1989 and completed in September 1991.

In the follicle resorption study the larvae were counted as second instar and reared at a density of 400 per 21 X 32 X 7cm polypropylene pan. Larvae and adults were maintained at a photoperiod of 16L:8D and a temperature of $21.0 \pm 0.2^\circ\text{C}$, except in 1989 when adults were maintained at a temperature of $24.0 \pm 0.2^\circ\text{C}$.

In the known oviposition study, larvae were reared at a density of four egg rafts per pan and adults and larvae were maintained at a photoperiod of 17L:7D and a temperature of $21 \pm 1^\circ\text{C}$. Adults emerged and mated in 30 X 30 X 30cm Plexiglas® cages.

Larvae were fed an excess of finely ground bovine liver powder (ICN Biochemicals, Inc.) and adults were provided with 10% sucrose solution. The sucrose solution was replaced with water two days prior to blood feeding and returned after blood feeding. Females were offered human blood for 30-60 minutes in a 15.0 x 2.5 x 2.5cm screened cage strapped to the arm. Nulliparous females were blood-fed 2-13 days post eclosion and parous females the day after oviposition. Nullipars with the abdomen distended with blood (50% or more), and all blood-fed pars, were used in the experiments.

For oviposition, a single gravid female was placed in a screened cage, which was partially submerged in water. Females were placed in

these cages five days after blood feeding, and were left from 1-3 days to oviposit.

Dissection method and the blind test

Anautogenous nullipars were dissected at 6-34 days post eclosion for the follicle resorption study, and at ≤ 12 days post eclosion for the known oviposition study. Females were scored as autogenous if any follicle had developed beyond stage IIb (Brust 1991). The follicle stages referred to are those described by Watts and Smith (1978). Some researchers recognise a germarium and a stage N follicle. In this study the germarium was considered synonymous with the stage N follicle. Autogenous nullipars, which were infrequent, were excluded from the study. Sucrose-fed nullipars were dissected at 6, 12, 18, 26 and 34 days post eclosion. Data collected from nullipars greater than 12 days of age were not used to develop the diagnostic criteria. Parous females were dissected 2-3 days after oviposition.

Each female was aspirated into a partially filled vial of distilled water, which was briefly agitated. The immobilized female was transferred with forceps to a glass slide containing a drop of physiological saline (Hagedorn et al. 1977). The abdomen was removed using a minuten pin embedded in a swab stick. After this, a pair of dissecting needles were the only tools used until the cover slip was applied.

To reveal the ovaries, the terminal abdominal segments were removed, and when necessary the pleural membrane was torn along one side

of the abdomen. Both ovaries were then transferred to one drop of fresh saline on a clean slide.

One needle was entangled in the trachea which enter the ovary. The other needle was used to gently flick the first needle, and vibrate the ovary until the ovarioles separated from the calyx and dispersed throughout the saline (Hitchcock 1968). Small clumps of ovarioles which broke away were treated in a similar manner. Occasionally the ovarian sheath had to be torn prior to vibrating the ovary. These procedures were carried out at 12X magnification, using a dissecting microscope.

The preparation was covered with a #1, 22mm glass circle, cover slip supported on the edges by broken pieces of a #2 cover slip. This ensured that ovarioles were not depressed or lost to the edge. The ovarioles were viewed with a phase contrast photomicroscope at 100-400X magnification. A detailed record was made of structural features of the ovarioles, which included the condition of dilatations and pedicels. Pedicels were scored as absent if they were less than two pedicel cell equivalents in length, and cellular when they had at least two adjacent pedicel cells which were structurally sound. Pedicels which did not fit the cellular category were scored as acellular.

Diagnostic criteria were developed using three parameters: (1) the minima of 0-dilated ovarioles found in nullipars versus the maxima of 0-dilated ovarioles found in pars, (2) the minima of 1-dilated ovarioles found in pars versus the maxima of rogue ovarioles found in nullipars, (3) the minima of 2-dilated ovarioles found in 2-pars versus the maxima of rogue ovarioles found in 1-pars.

The blind test was comprised of 25 nullipars frozen at 6-8 days post eclosion, and 27 one-pars and 10 two-pars frozen 2-3 days post oviposition. Females were labelled using random numbers and then mixed and dissected as unknowns. The dissector (who was another research worker) was aware that the females were either nullipars, 1-pars or 2-pars.

Definitions

Pedicel

A pedicel is a narrow stalk of variable length which may be cellular or acellular (degenerated). The pedicel connects the primary follicle to the calyx (central tube of the ovary) in an ovariole with no dilatation. The pedicel connects the primary dilatation to the calyx in an ovariole with one or more dilatations (adapted from Bertram 1962). A pedicel is only found in ovarioles which have never ovulated (Lange and Khok 1981).

Primary connecting stalk

The primary connecting stalk connects the secondary follicle to the dilatation in 1-dilated ovarioles. The secondary connecting stalk connects the dilatations in 2-dilated ovarioles, etc. (Bertram 1962).

Degenerating follicle

The follicle begins to collapse and/or is partially devoid of contents (follicle cells, trophocytes and oocyte). The degeneration of stage N-IIb follicles is known as early stage degeneration; the degeneration of follicles developed beyond stage IIb is known as late stage degeneration (adapted from Giglioli 1965).

Dilatation versus degenerating follicle

A dilatation is a localized swelling at the previous site of a follicle (Bertram 1962). A degenerating follicle is recorded as a dilatation when it shrinks to \leq the width of the next developing follicle. This definition only applies when the next follicle is still at stage N (Fig. 1).

Relic

A dull to bright yellow mass within the dilatation (viewed with phase contrast at 100-200X magnification). The relic is larger than the average pedicel cell (all dilatations in Figures except Fig. 14).

Basal dilatation

A basal dilatation (Giglioli 1965) is furthest from the follicle. It has a relic and the ovariole has no pedicel (lower ovariole Fig. 10, Fig. 16).

Normal and abortive oogenesis

Normal oogenesis is the development of a resting stage follicle into an egg. Abortive oogenesis is the degeneration of early or late stage follicles in females committed to normal oogenesis (Detinova 1962).

n-dilated ovarioles

A 0-dilated ovariole has no dilatation and a pedicel of at least six adjacent cells (Fig. 5, Brust unpublished). The 0-dilated ovariole is the diagnostic ovariole in nullipars. A 1-dilated ovariole has one dilatation and may or may not have a pedicel. A 2-dilated ovariole has two dilatations, etc..

Diagnostic ovariole

This is an ovariole where the number of dilatations in the ovariole is equivalent to the parity status of the female. The pedicel is intact and consequently all dilatations were formed from abortive oogenesis (Lange and Khok 1981). The primary dilatation (furthest from the follicle) may be a basal dilatation (terminal sac), in this case the ovariole ovulated in the first gonotrophic cycle (Anufrieva and Artem'ev 1981).

The diagnostic index (index of diagnostic reliability) is the proportion of dilated diagnostic ovarioles in the ovaries (Lange and Khok 1981).

Sacculate (saccate) ovariole

The sacculate ovariole is formed at ovulation. The sac eventually shrinks to form a basal dilatation (Giglioli 1965, Sokolova 1981, Figs. 2, 11).

Rogue ovariole

An ovariole which causes an overestimation of parity status. (Figs. 1, 6, 9, 14, 17).

Club-shaped ovariole

An ovariole with a rudimentary stage N follicle attached to a longer than average pedicel or connecting stalk (adapted from Sokolova 1981, Fig. 8).

Results

Follicle resorption (21°C) in 6-34 day old nullipars

The number of 0-dilated ovarioles (Figs. 5, 7) found in 50 nullipars ranged from 4-126 per female over 34 days. On average there were fewer 0-dilated ovarioles in older females (Table 1). The mean maximum number of pedicel cells in any 0-dilated ovariole (per female, n=47) was 10.9 ± 0.4 (6-16) cells.

At least 50% of nullipars (per sample day, Table 1) had one or more rogue ovarioles (Figs. 1, 9). The maximum number of rogue ovarioles in any nullipar was 31. Nullipars ≤ 12 days old had no 2- or 3-dilated ovarioles and a mean of 87.9 zero-dilated ovarioles (Table 2).

All follicles of 0-dilated ovarioles and 39.6% of follicles of 1-dilated ovarioles (Table 1) were developed beyond stage N (Appendix I). Stage I Ib follicles were found in 60.7% of 18-34 day old nullipars. Two nullipars (day 26 and 34) had one club-shaped ovariole with one and three dilatations.

Nullipars (≤ 12 days old), and known 1-pars, 2-pars and 3-pars

The frequency of diagnostic ovarioles (Figs. 3, 4, 5, 10, 13, 15) declined with increasing parity status. Ten per cent of 2-pars and 20% of 3-pars had no diagnostic ovariole. Sixty per cent of 3-pars had no diagnostic ovariole, when diagnostic ovarioles which lacked a pedicel were excluded. At least one rogue ovariole was found in 50% of nullipars, 42% of 1-pars (Fig. 6) and 28% of 2-pars. None were found in 3-pars (Table 2).

The diagnostic index (%) was 46.1 ± 2.1 (12.3-103.6) for 1-pars (n=47), 6.8 ± 1.0 (0-24.4) for 2-pars (n=44) and 0.9 ± 0.3 (0-1.6) for 3-pars (n=5).

The ratio of the mean number of 1-dilated : 0-dilated ovarioles was 0.01:1 in nullipars, 41:1 in 1-pars and 88:1 in 2-pars (Table 2). The frequency of 2-dilated ovarioles was higher in 3-pars (Fig. 16) than in 2-pars (Table 2).

Pars had follicles developed beyond stage N but not beyond stage II (apart from females with retained eggs, see below); 5.3% of pars had a follicle at stage II.

Club-shaped ovarioles were found in 26.3% of 1-pars and 42.0% of 2-pars. The mean number of club-shaped ovarioles per female was 2.0 ± 0.4 in 1-pars and 2.4 ± 0.4 in 2-pars. The maximum number of dilatations found in any club-shaped ovariole was three. Club-shaped ovarioles were not used to develop the diagnostic criteria, because the penultimate "dilatation" did not fit the definition of a dilatation (Fig. 8). Only three females had club-shaped ovarioles which were rogue ovarioles (by one dilatation).

Autogeny and fecundity

No autogeny was found in 10-12 day old females (n=118) and 1.2% autogeny was found in 17-19 day old females (n=165). One autogenous female had six eggs.

Three autogenous females were found on day 26 (Table 1, n=13) of the follicle resorption study, one had five and one had six eggs. Ten per cent of females (n=100) maintained at 24°C were autogenous

(Appendix I); five of these had a mean of 21.0 ± 4.7 (5-34) eggs.

There was a decrease in fecundity with increasing parity status (Table 3). Nine per cent (10/112) of pars retained a mean of 2.1 ± 0.6 (1-7) eggs after oviposition. One 1-par which had retained three eggs had 14 stage IV follicles.

Ovariole composition: nullipars, 1-pars, 2-pars and 3-pars

A comparison of ovariole types in females of different parity status, did not reveal trends in ovariole composition (Tables 4, 5) which could be used as diagnostic criteria. The presence of a pedicel in 1-dilated ovarioles, and pedicel cell counts (Table 4), were useful as separation indicators (see below).

One-dilated ovarioles with a pedicel of < 2 pedicel cell equivalents (top ovariole Fig. 10) were infrequent. They were classed with 1-dilated ovarioles with basal dilatations (Table 4), because it was difficult to judge whether or not the (pedicel) remnant was in fact the pedicel or other tissue.

Pedicel cells were well defined in 0- to 2-dilated ovarioles of nullipars (Figs. 1, 7, 9, 14). Acellular pedicels in dilated ovarioles of pars ranged from being crimped (Fig. 4) to cylindrical in part (Fig. 6, 13). There was a progressive degeneration of the pedicel and connecting stalks in many 2-dilated ovarioles (Figs. 13, 17).

Trends which differentiated 2-dilated ovarioles of 1- and 2-pars were follicle stage, and the quantity and quality of cells in the primary connecting stalk (Table 5, compare Fig 6 and 13).

The proportion of 2-dilated ovarioles with stage N follicles was smaller in 2- and 3-pars than it was in 1-pars (Table 5). The proportion of 3-dilated ovarioles with a stage N follicle was similar in 2- and 3-pars.

Diagnostic criteria

- 1 Nullipars had ≥ 25 zero-dilated ovarioles.
- 2 Pars had ≥ 15 one-dilated ovarioles.
- 3 Two-pars fit criterion no.2 and had ≥ 5 two-dilated ovarioles.
- 4 The number of 2-pars $\times 1.43$ accounts for the number of 2-pars misdiagnosed as 1-pars.

Separation indicators

- 1 12.2% of 1-dilated ovarioles in nullipars and 88.1% of 1-dilated ovarioles in 1-pars had no pedicel.
- 2 64.6% of 1-dilated ovarioles in nullipars and 0.5% of 1-dilated ovarioles in 1-pars had a pedicel of ≥ 5 adjacent cells.

Females used to develop the diagnostic criteria fit criteria 1 and 2 in 99.2% (n=132) of nullipars and pars. Sixty-three nullipars reared at a temperature of 24°C (Appendix I) and dissected at 2-14 days of age fit the diagnostic criteria. Females used to develop the diagnostic criteria fit criterion 3 in 98.2% (n=57) of 1-pars and 70.0% (n=50) of 2-pars. The presence of a 3-dilated ovariole in a 2-par increased confidence in classification. Three-dilated ovarioles were not used to diagnose 2-pars and were ignored when the correction factor was determined. The correction factor was calculated from the total number

of 2-pars (n=50) divided by the number of 2-pars which fit diagnostic criterion 3 (n=35, Appendix II). Three-pars fit criterion 3 and would be diagnosed as 2-pars in an sample of unknowns. This would affect the efficacy of the correction factor.

One-dilated ovarioles with connecting stalks of > 5 cells (Fig. 11) were frequently found in 1-pars with 0-dilated ovarioles. It is possible that some of these ovarioles broke (during dissection) at their junction with the dilatation, and were erroneously classed as 0-dilated ovarioles. None of the primary connecting stalks (apart from club-shaped ovarioles) had > 8 cells.

When the 0-dilated ovariole was defined by ≥ 9 pedicel cells, 64% of 12 day old nullipars (n=25) did not fit the diagnostic criteria, and 38% of these had ≤ 5 zero-dilated ovarioles. When the 0-dilated ovariole was defined by ≥ 6 cells in the same group of females, 12% of females did not fit the diagnostic criteria, none of these had ≤ 5 zero-dilated ovarioles.

The blind test

This test consisted of needle dissections of ovaries of 62 previously frozen females. Three were excluded because they had ≤ 5 zero-dilated ovarioles and ≤ 5 one-dilated ovarioles. Fifty-six females were correctly classed as nullipars or pars. Six of these did not fit the diagnostic criteria and were separated using the separation indicators. One 2-par (n=10) was correctly diagnosed.

Discussion

The problem of age underestimation and age overestimation

Underestimation and overestimation of gonotrophic age in mosquitoes are obstacles to the confident application of Polovodova's (1949) method for determining parity status (Lange and Khok 1981). Polovodova (1949) equated the maximum number of dilatations (thickenings) in any ovariole, to the parity status of a mosquito. Age underestimation can be minimized by careful dissection and the analysis of all ovarioles, and by the examination of known oviposition cycles to determine when age estimation is subject to error (Liu 1968). The analysis of all ovarioles would also maximise the potential for age overestimation. The small proportion of rogue ovarioles in nulliparous, 1-parous and 2-parous *Cs. inornata* demonstrates the potential for age overestimation in this species. Rosay (1969) and Reisen *et al.* (1989) reported dilatations in laboratory-reared anautogenous, nulliparous *Cs. inornata*. Relatively little has been published on the condition of the ovarioles in known nulliparous and parous *Cs. inornata*, despite the ease with which this species may be colonized (McLintock 1952, Owen 1942).

The potential for age overestimation using Polovodova's (1949) method was high in 0- to 2-parous *Cs. inornata*. Age overestimation was reduced by the development and application of diagnostic criteria. The potential for age underestimation was high in 2- and 3-parous *Cs. inornata*. The parity diagnosis of 2-parous *Cs. inornata* was affected age overestimation and age underestimation. Age underestimation was offset by the correction factor.

Diagnostic ovarioles and the diagnostic index

Giglioli (1965) reported that repeated cycles of normal oogenesis in wild *Anopheles melas* Theobald, resulted in the formation of a single basal dilatation. Giglioli (1965) found that abortive oogenesis in *An. melas* rarely occurred in the first cycle, which made age estimation presumptive. Lange and Khok (1981) used the terms dilatation and sac to specify abortive and normal oogenesis respectively, and therefore restricted the traditional use of the term dilatation (Beklemishev *et al.* 1959 and others).

The proportion of ovarioles with distinct terminal sacs was low in parous *Cs. inornata* (general observations). The use of the term, terminal sac, defined by Lange and Khok (1981), epitomises normal oogenesis. The term basal dilatation (Giglioli 1965) was adopted so as to avoid misinterpretation. The scarcity of distinct terminal sacs in parous *Cs. inornata* may have been due to dissection technique, anatomy of the species studied, and/or time lapse between oviposition and dissection. Sokolova (1983) reported that terminal sacs began to lose their distinctive appearance 1-7 days after oviposition. The proportion of ovarioles with distinct terminal sacs was higher in gonotrophically older *Cs. inornata* (general observations). This was possibly due to increased (cumulative) fecundity, and/or a reduction in the elasticity of the ovarian tissue. Spencer (1979) reported reduced elasticity in the ovarian tissue of wild 3-parous *Anopheles farauti* Laveran.

Lange and Khok (1981) developed the diagnostic index, which is the mean proportion of (dilated) diagnostic ovarioles found in succeeding gonotrophic cycles. The proportion of females which lack diagnostic

ovarioles (age underestimation), and the proportion of females which possess rogue ovarioles (age overestimation) cannot be determined from the index. In *Cs. inornata*, the diagnostic index declined with increasing gonotrophic age. This was consistent with the literature, apart from *Anopheles hyrcanus* Pallas (Anufrieva and Artem'ev 1981). The value of the index for interspecies comparison, is limited by differences in dissection method and definition of the diagnostic ovariole.

Detinova (1962) stressed the need to find the (diagnostic) ovariole with the maximum number of dilatations and a pedicel. The ovariole type that Lange and Khok (1981) used to determine their index of diagnostic reliability was essentially the same. However, their understanding of how it was formed and the significance of this to age grading studies, was very different. The number of ovulations associated with a terminal sac is speculative in females which lack Lange and Khok's (1981) diagnostic ovariole (Hoc and Charlwood 1990). Anufrieva and Artem'ev (1981) counted diagnostic ovarioles with dilatations and a pedicel, and diagnostic ovarioles without a pedicel. This approach was applied to *Cs. inornata* (in the current study) so that the overall count of diagnostic ovarioles would be (artificially) higher, and the frequency of age underestimation in gonotrophically older females would be lower. A high count of diagnostic ovarioles increased the overall confidence in parity diagnosis, and made it possible to raise the baseline diagnostic criteria, to account for rogue ovarioles in the preceding cycle.

The efficacy of Lange and Khok's (1981) diagnostic ovariole,

relies on the assumption that follicles which do not develop into eggs undergo abortive oogenesis. This assumption appeared to be true in gonotrophically younger *Cs. inornata*. The few 0-dilated ovarioles in 1-pars and 2-pars, may have been 1-dilated ovarioles with long connecting stalks that broke (close to the dilatation) during dissection. However, if a follicle is quiescent in any cycle (Fig. 12) and diagnostic ovarioles are nonexistent, the assumption could result in diagnostic error.

Lange and Khok (1981), and Beklemishev *et al.* (1959) reported that normal oogenesis can follow abortive oogenesis in the same ovariole in subsequent cycles. The random nature of normal oogenesis reduces the diagnostic index in gonotrophically older females (Lange and Khok 1981). However, Giglioli (1965) believed that when abortive oogenesis occurs in *An. melas*, it is likely to continue in the same ovariole in subsequent cycles. Gillies (personal communication) believed that normal oogenesis is largely random, but that a small number of ovarioles exist in some anophelines to which this rule does not apply. The presence of a diagnostic ovariole in a 12-par (Gillies and Wilkes 1965) supports Gillies' hypothesis. Sokolova and Lange (1989) speculated that a developmental defect may cause some ovarioles to consistently resorb each developing follicle.

The frequency of the dilated diagnostic ovariole applied to *Cs. inornata* would be affected by random oogenesis after the second gonotrophic cycle, whereas the frequency of Lange and Khok's diagnostic ovariole, which has a pedicel, would be affected by random oogenesis after the first cycle. Evidence that normal oogenesis can follow

abortive oogenesis in the same ovariole, was seen in autogenous *Cs. inornata*. Autogenous females laid small egg rafts in the first gonotrophic cycle (Appendix V), and were blood-fed and laid larger egg rafts in the second cycle. It was assumed that the majority of follicles were committed to abortive or normal oogenesis in the autogenous cycle (Bellamy and Corbet 1973). If this assumption is correct then reduced fecundity, or a reduction in fecundity with each oviposition cycle, increases the probability of finding diagnostic ovarioles in gonotrophically older females.

The numbers of adjacent cells in the connecting stalk and the pedicel vary among species. The connecting stalk is always shorter than the pedicel in some species (Giglioli 1965, Gozhenko 1980), whereas in others there is some overlap (Hoc 1975). Brust (personal communication) found that 1-parous *Culex tarsalis* Coquillett, had 1-dilated ovarioles with primary connecting stalks of less than six adjacent cells. Brust assumed that ovarioles with at least six pedicel cells and no dilatation, would not be 1-dilated ovarioles which had broken during dissection.

The application of the 0-dilated ovariole to the parity diagnosis of *Cs. inornata*, was limited by its low frequency in older nullipars, and by the variable length of the primary connecting stalk in 1-dilated ovarioles. Despite these drawbacks, the frequency of 0-dilated ovarioles provided a quantitative tool for the diagnosis of nullipars. Prior to this, the quantitative diagnosis of nullipars relied on the absence of dilated ovarioles or sacs. The number of pedicel cells which best define

the 0-dilated ovariole probably varies among species, and may not be applicable in some cases.

Development and application of the diagnostic criteria

Criteria for parity diagnosis were developed from the relative frequency of 0-dilated ovarioles in pars, rogue ovarioles, and diagnostic ovarioles. The separation indicators provided useful clues when the diagnostic criteria could not be applied. It was assumed that in nature, females would blood-feed within 12 days of adult eclosion.

Anufrieva and Artem'ev (1981) calculated the minimum number of diagnostic ovarioles required to separate 1- to 4-parous *Anopheles pulcherrimus* Theobald and *An. hyrcanus*. They calculated these minima from the diagnostic index and potential fecundity of the species. It was not clear how, or why they did this. There was no evidence of rogue ovarioles in these species and the incidence of age underestimation was less than one per cent.

The diagnostic criteria for *Cs. inornata* provide a base line for parity diagnosis. The criteria reflect the minimum number of diagnostic ovarioles found in a parous class, which can be used to differentiate gonotrophically younger females with rogue ovarioles. Any increase in the number of diagnostic ovarioles would increase confidence in classification. In theory, the base line can be reinforced by adult feeding conditions. The provision of sucrose is known to increase fecundity in a number of mosquito species (Nayar and Sauerman 1975). This would only be effective in the first cycle if Lange and Khok's (1981) diagnostic ovariole were used. Therefore the base-line diagnostic

criteria established for *Cs. inornata* were not affected by selecting nullipars which had imbibed a specific quantity of blood.

Diagnostic criteria 1 and 2 fit all the females from which they were extrapolated, apart from a 1-par which had 26 zero-dilated ovarioles and 25 1-dilated ovarioles. The accurate separation of wild 1- and 2-pars using the diagnostic criteria and the correction factor, is dependent on the correlation between ovariole type frequency in wild and laboratory-reared specimens. This is less critical for the separation of nullipars and pars, where a major constraint is the assumption that nullipars are ≤ 12 days of age.

Further study should focus on applying the diagnostic criteria to field populations, and increasing the data on ovariole type frequency in females of known oviposition history. Three- and 4-parous *Cs. inornata*, which are known to occur in the wild (Meyer *et al.* 1982, Meyer and Washino 1978, Reisen *et al.* 1989) may be few in number. Therefore, from an epidemiological perspective, they may be less important than 1- and 2-pars.

The results of the blind test, especially for 2-pars, were disappointing. The poor results were attributed to ovariole breakage caused by freezing the specimens. The specimens were frozen so that all the parity classes could be dissected simultaneously. The use of frozen specimens for dissection is definitely not recommended. The test results were an improvement on a previous test (Meyer *et al.* 1982) in which known nulliparous and 1-parous *Cs. inornata* were separated using Polovodova's method (Giglioli 1963b).

The recognition of rogue ovarioles

Follicle stage and frequency, the contents of a dilatation, and the condition of a pedicel or connecting stalk, are features which may contribute to the recognition of a rogue ovariole. Hoc (1975), Sokolova and Lange (1989) and others, reported that pedicels of dilated ovarioles were cellular in nullipars and degenerate in pars. This phenomenon was quantified in *Cs. inornata*, and the proportion of 1-dilated ovarioles with cellular pedicels, was used as a separation indicator when the diagnostic criteria were inapplicable. The scoring of pedicel cells as structurally sound versus degenerating was subjective. The pedicel cells of 1-dilated ovarioles in nulliparous (anautogenous) *Cs. inornata* had seldom degenerated (general observations). The dilatations in these ovarioles would be formed from early stage degeneration (see definitions). It is possible that the degeneration of the pedicel is affected by follicle stage and hormonal factors.

The data collected from rogue ovarioles in *Cs. inornata* was not used to develop separation indicators for 1- and 2-pars. Follicle stage and the condition of the primary connecting stalk, may be useful features for differentiating 2-dilated rogue and diagnostic ovarioles.

Ovariole types, terms and definitions

The application of terms and definitions established in age grading studies is complicated by the need to service two conflicting hypotheses. Detinova (1962), Hoc and Charlwood (1990), Lange and Khok (1981), Sokolova (1981) and others, described ovariole types which conform to explanations of hypothetical development. The definition of

ovariole types for parity diagnosis need not accurately conform to actual developmental processes provided that they work for parity diagnosis.

The terms agonotrophic and gonotrophic are well established in the Russian literature (Gozhenko 1980, Lange and Khok 1981, Sokolova and Lange 1989). The dilatations of rogue ovarioles in nullipars would be agonotrophic. However, the description of dilatations in parous females as agonotrophic is presumptive. Lange and Khok (1981) did not have a method for differentiating agonotrophic and gonotrophic dilatations. Hoc and Charlwood (1990) assume that one gonotrophic dilatation is formed per ovariole per gonotrophic cycle. The duration of the gonotrophic cycle is influenced by a number of factors, including temperature and the location of a suitable oviposition site. The increased occurrence of rogue ovarioles as nullipars age, suggests that rogue ovarioles are more likely to form during long, rather than short, gonotrophic cycles.

The possibility that more than one dilatation could form from one late stage degenerating follicle, made the counting of proximal dilatations questionable. In the current study, proximal dilatations which were not separated by a discrete section of connecting stalk were rare. When they did occur, the following guideline was applied: the diameter of the constriction defining the dilatations should approximately equal the diameter of the pedicel or connecting stalk. This was difficult to judge when the whole ovariole could not be viewed simultaneously. Borderline cases were judged in favour of the larger number of dilatations.

In the current study the term sac was only applied to sacculate

ovarioles (however, see Chapter IV, pp. 66, 68, 72). The terminal sac (basal dilatation) described by Lange and Khok (1981) and Anufrieva and Artem'ev (1981) had a relic (yellow body) whereas Hoc and Charlwood (1990) did not mention relics in their description of the terminal sac. The counting of sacs (Lange and Khok 1981) or sacculate ovarioles, provides an estimate of fecundity (Anufrieva and Artem'ev 1981, Hoc and Charlwood 1990). The fecundity of *Cs. inornata* was determined from known oviposition studies and the use of oviposition pools (Brust 1990, Buth *et al.* 1990).

Small ovarioles were apparent in *Cs. inornata*, although an attempt to define them on the basis of follicle length was abandoned because of their low frequency. Hoc and Charlwood (1990) found dwarf ovarioles in wild *Aedes cantans* Meigen. Contrary to Gillies and Wilkes (1965), Hoc and Charlwood (1990) believed that dwarf ovarioles were unreliable for parity diagnosis.

Sokolova (1981) identified numerous ovariole types in pars, which included small, normal and club-shaped ovarioles with combinations of: degenerating follicles, pregonotrophic dilatations, agonotrophic dilatations and gonotrophic dilatations. Sokolova (1981) defined the club-shaped ovariole as an ovariole without a follicle which may or may not have a functional germarium. In the current study the definition was restricted to ovarioles with a rudimentary stage N follicle, which is equivalent to Sokolova's (1981) non-functional germarium.

Spencer (1979) and Sokolova (1983) reported that compressed follicular debris, from successive cycles of ovulation, can be seen as distinct granular zones in the basal dilatation (terminal sac). Sokolova

(1983) found dilatations between the follicular tube and the ovariole sheath, and believed that these were torn (pushed aside) from the follicular tube when normal oogenesis followed abortive oogenesis. These were called vestigial dilatations (Sokolova 1983).

Sokolova (1983) proposed a combined (combinative) method of parity diagnosis. This relied on the agreement in diagnosis of ovarioles with different combinations of: granular zones, gonotrophic dilatations, and vestigial dilatations. Spencer (1979) used granular zones and dilatations to age grade *An. farauti*.

Spencer (1979) and Sokolova (1983) interpreted their experimental results from different perspectives, which were based on the (then) current hypotheses concerning the formation of dilatations. There was no evidence of granulation zones and vestigial dilatations in *Cs. inornata* using the vibrating needle method (personal observations).

The choice of dissection method

The vibrating needle method (Hitchcock 1968) and the oil injection method (Hoc and Charlwood 1990) permit the analysis of all ovarioles at high magnification. The dissection method used by Beklemishev *et al.* (1959) had the advantage of being able to analyse ovarioles intact, but at low magnification and generally in small numbers. This lowers the probability of encountering rogue ovarioles. The dissection method could affect the interpretation of the ovaries. The method of Beklemishev *et al.* (1959) relied on the stretching of ovarioles. Giglioli (1965) found evidence of serial dilatations in stretched sacculate ovarioles of multiparous *An. maculipennis*.

The vibrating needle method is relatively quick and simple, which is important if a large numbers of mosquitoes are to be dissected. However, there is no way to estimate the number of ovarioles which break at their junction with the calyx. This problem may be reduced using the oil injection method (Lange and Khok 1981).

The small proportion of nullipars, which did not fit the diagnostic criteria, is an indication that the method (or the definition) is fallible. The pedicels in ovarioles with large follicles (associated with older nullipars) may have a tendency to break close to the follicle. Careful dissection is important, especially when the ovarioles are being dispersed. The provision of secondary diagnostic criteria (Chapter IV) for *Cs. inornata* may be appropriate.

The mode of ovulation: conflicting hypotheses

The hypothesis of Lange and Khok (1981) and Giglioli's (1965) observations in *An. melas*, that the sac shrinks after any number of ovulations to form a single terminal sac (basal dilatation), was not proven for *Cs. inornata*. However, the reduction in the number of diagnostic ovarioles with increasing gonotrophic age in *Cs. inornata*, and the high proportion of dilated ovarioles in pars which lacked a pedicel, are an indication that their hypothesis is valid for this species.

Beklemishev *et al.* (1959) assumed that ovulation occurred via the expanded pedicel which then reformed. Spencer (1979) believed that the pedicel did not always reform after the first ovulation. Hoc (1975) found a terminal sac after ovulation which opened into the calyx.

The sac was formed from degenerating follicular epithelium and the tunica. Hoc (1975) believed that the degeneration of pedicel cells during the gonotrophic cycle was in preparation for ovulation. Lange and Khok (1981) reported that the pedicel was lost forever after ovulation.

Lehane and Laurence (1978) reported that the calyx extended around the egg (primary follicle) and breaks appeared where the calyx and follicular epithelium made contact. The egg then protruded into the lumen of the calyx. The breaks in the calyx were not visible after oviposition. Prior to blood feeding, nullipars had a pedicel with a solid core of cells attached to the calyx, and after ovulation the ovariole was connected to the calyx by the ovariole sheath alone, and the pedicel was lost. Lehane and Laurence (1978) assumed that dilatations were formed by the ovariole sheath (associated with the follicle) because the tunica degenerated.

In the current study, a light microscopic examination of the ovaries of newly emerged *Cs. inornata* (Appendix V), showed that the pedicel was a solid core of cells without a lumen. Dilatations which formed from follicle degeneration, and basal dilatations which were deemed to result from normal oogenesis (live dissections/phase contrast), were not associated with the ovariole sheath.

It is plausible that a long pedicel would be bypassed during ovulation. However, the proportion of ovarioles with long pedicels was not high in nulliparous *Cs. inornata*. The tunica of the pedicel may be as elastic as the tunica of the follicle, and ovulation via the pedicel cannot be ruled out. If this is the case, more than one mode of ovulation may occur. The whole question regarding the mode of ovulation

requires further study. The hypotheses concerning the formation of dilatations are inextricably linked to the mode of ovulation.

Natural conditions

Constant temperature and photoperiod, the use of sucrose and optimal blood-feeding in adult females, and high protein diet for larvae, are not necessarily representative of field conditions. Wild nulliparous and parous *Cs. inornata* imbibe syrup (Hudson 1977a), but the use of sucrose in the laboratory may be inappropriate because it is known to be a potent phagostimulant (Schmidt and Friend 1991).

Follicle stages in nullipars and pars were consistent with those recorded in the literature (Buth *et al.* 1990, Reisen *et al.* 1989), as were the frequency and number of retained eggs (Hudson 1977a). The mean number of eggs laid by 1-pars was lower than means recorded for wild pars (Buth *et al.* 1990). A reduction in fecundity with gonotrophic age is supported by Owen (1942). Reduced fecundity could be related to blood feeding behaviour, the voiding of meals (Owen 1942), or physiological factors associated with increased age.

The scoring of autogeny was based on practical rather than definitive criteria. It would be difficult to prove that a female which developed follicles beyond the resting stage was certain to develop eggs. *Cs. inornata* are primarily anautogenous, but autogenous females are known to occur (Hudson 1977b, Meyer and Washino 1978, Meyer *et al.* 1982, Owen 1942, Reisen *et al.* 1989). Autogenous-anautogenous pars could have more diagnostic ovarioles than their anautogenous counterparts if cumulative fecundity was low. The ovaries of autogenous 1-pars may be

similar to ovaries of anautogenous 1-pars which developed a small number of eggs.

If a high proportion of females coming to traps are sacculate, then females can be maintained on water or sucrose solution for a day while the sacs shrink. The large amounts of ovarian membrane (tunica and ovariole sheath) encountered in sacculate females may obscure diagnostic ovarioles (personal observation). Sacculate post aestival *Cs. inornata* (Barnard and Mulla 1978, Reisen *et al.* 1989), which oviposit after holding eggs for an extended time, may have sacculate ovarioles with a dilatation between the sac and the next developing follicle.

Empty 1-parous *Cs. inornata*, which were fecund and delayed host seeking, or were unsuccessful in obtaining a blood meal for an extended time after oviposition, may be misdiagnosed as nullipars with rogue ovarioles if they have connecting stalks of > 5 cells. Sokolova (1983) reported that terminal sacs were difficult to discern in females (*Anopheles*, *Aedes* and *Culex* species) which were dissected three weeks or more after oviposition.

Polovodova's (1949) method, unaffected by Lange and Khok's (1981) reappraisal of ovarian dynamics, continues to be important in mosquito ecology. Its application to some anthropophilic vectors of malaria (Anufrieva and Artem'ev 1981, Lines *et al.* 1991) and other species (Gozhenko 1980) has proven to be highly effective. Species which exhibit rogue ovarioles require specific parity diagnostic criteria, extrapolated from known oviposition studies. The problem of age overestimation and age underestimation is insufficient reason to abandon the dilatation method for more convenient and less specific methods.

Table 1. Mean number of ovarioles in sucrose-fed nulliparous *Culiseta inornata* (10/day) over a 34 day period (21±0.2°C; 16L:8D).

Day	0-dilated ovarioles			1-dilated ovarioles			2-dilated ovarioles			3-dilated ovarioles		
	$\bar{x} \pm SE$	(Range)	#♀♀	$\bar{x} \pm SE$	(Range)	#♀♀	$\bar{x} \pm SE$	(Range)	#♀♀	$\bar{x} \pm SE$	(Range)	#♀♀
6	97.0±6.5	(69-126)	10	1.0±0.0	-	5	-	-	0	-	-	0
12	78.8±8.6	(44-125)	10	4.2±1.3	(2-9)	5	-	-	0	-	-	0
18	66.8±8.3	(8-104)	10	4.2±1.4	(1-15)	10	1.5±0.5	(1-2)	2	-	-	0
26	38.1±8.1	(4-77)	10	3.2±0.9	(1-8)	8	1.0±0.0	-	2	-	-	0
34	34.4±6.1	(15-70)	10	11.9±3.9	(1-31)	8	1.8±0.5	(1-4)	6	1.0±0.0	-	1

Table 2. Mean number of ovarioles in known nulliparous, 1-parous, 2-parous and 3-parous *Culiseta inornata*.

Cycle	0-dilated ovarioles			1-dilated ovarioles			2-dilated ovarioles			3-dilated ovarioles		
	$\bar{x} \pm SE$	(Range)	% $\varphi\varphi^a$	$\bar{x} \pm SE$	(Range)	% $\varphi\varphi$	$\bar{x} \pm SE$	(Range)	% $\varphi\varphi$	$\bar{x} \pm SE$	(Range)	% $\varphi\varphi$
0 ^b	87.9 \pm 5.6	(44-126)	100.0	2.6 \pm 0.8	(1-9)	50.0	-	-	0.0	-	-	0.0
1	5.0 \pm 1.4	(1-26)	35.1	72.1 \pm 3.4	(18-146)	100.0	2.0 \pm 0.3	(1-6)	42.1	-	-	0.0
2	2.6 \pm 0.6	(1-8)	32.0	73.6 \pm 3.8	(29-142)	100.0	12.5 \pm 1.5	(1-41)	90.0	1.4 \pm 0.2	(1-3)	28.0
3	-	-	0.0	47.8 \pm 3.6	(36-56)	100.0	19.6 \pm 4.7	(9-35)	100.0	1.5 \pm 0.3	(1-2)	80.0

^aPercentage of females with at least one ovariole in that class (n=20,57,50 and 5 for nullipars 1-pars 2-pars and 3-pars respectively). One 3-par, unlike other pars 2-3 days post oviposition, had 10 sacculate ovarioles.

^bCombined data day six and 12, Table 1.

Table 3. Mean number of eggs laid and number of ovarioles in successive gonotrophic cycles of Culiseta inornata (21±1°C; 17L:7D).

	First cycle ^a		Second cycle		Third cycle	
	$\bar{x} \pm SE$	(Range) # $\phi\phi$	$\bar{x} \pm SE$	(Range) # ϕ	$\bar{x} \pm SE$	(Range) # ϕ
Eggs laid	135.3±3.5	(42-286) 145	92.2±5.0	(34-153) 39	57.4±4.1	(43-68) 5
Total # ovarioles	170.9±4.6	(103-242) 47	166.9±5.7	(118-290) 44	128.8±10.0	(97-152) 5

^a1-pars, 2-pars and 3-pars were 8-21, 17-29 and 29-36 days old respectively. The mean no. of eggs laid was significantly different, and the mean no. of ovarioles was not significantly different, at the 5% level by t-test for 1-pars and 2-pars.

Table 4. Per cent composition of 1-dilated ovarioles^a in nulliparous and 1-parous *Culiseta inornata* (21°C).

Structure	Condition	0-pars	1-pars
Dilatation			
	Relic present	59.3	99.1
	No relic	39.7	0.8
	Cellular ^b	1.1	0.1
Pedicel			
	Absent ^c	12.2	88.1
	Acellular ^d	2.6	8.2
	2-4 cells ^e	20.6	3.2
	≥ 5 cells	64.6	0.5

^an=189 ovarioles from 36 nullipars, n=4112 ovarioles from 57 one-pars.

^bDilatation had a strand of cells through it.

^cBasal dilatation, or pedicel < two pedicel cell equivalents.

^dPedicel ≥ two pedicel cell equivalents.

^eIn part, a single strand of adjacent cells.

Table 5. Per cent composition of 2-dilated ovarioles^a in 1-parous, 2-parous and 3-parous *Culiseta inornata*.

Structure	Condition	1-pars	2-pars	3-pars
Follicle stage				
	N	51.5	7.8	2.1
	> N	48.5	92.2	97.9
Dilatations				
	Relics present	54.5	68.2	40.2
	No relics	0.0	2.1	9.3
	Other ^b	45.5	29.7	50.5
Connecting stalk				
	2 cells	30.3	10.9	17.5
	≥ 3 cells	57.5	8.9	7.2
	Other ^c	12.2	80.2	75.3
Pedicel				
	Present	69.7	54.7	90.7

^an=33 ovarioles from 16 1-pars, 192 ovarioles from 16 2-pars and 97 ovarioles from 5 3-pars.

^bCombination of two of the following: dilatation had a relic, dilatation had no relic, dilatation had a strand of cells through it.

^cPrimary connecting stalk: acellular, one cell, or nonexistent.

Plate II. Photomicrographs of *Culiseta inornata* ovarioles

Each scale bar represents 25 μ m. c - calyx, d - dilatation, f - follicle at stage I-II (Watts and Smith 1978), n - follicle at stage N, p - pedicel, s - sac.

- Fig. 1. One-dilated ovariole from a 26 day old nullipar. The ovariole sheath (the membranous outer covering of the ovariole) is broadly joined to the calyx around the cellular pedicel.
- Fig. 2. Sacculate ovariole from a 1-par. The ovariole sheath has been torn from the calyx during dissection. The shrinking sac is full of follicular debris.
- Fig. 3. One-dilated ovariole from a 1-par. The pedicel is cellular.
- Fig. 4. One-dilated ovariole from a 1-par. The pedicel is acellular (the cells have degenerated).
- Fig. 5. Zero-dilated ovariole from an 18 day old nullipar.
- Fig. 6. Two-dilated ovariole from a 1-par. The presence of a pedicel indicates that normal oogenesis did not occur.
- Fig. 7. Zero-dilated ovariole from a 34 day old nullipar.
- Fig. 8. Degenerate ovariole from a 1-par. The long connecting stalk is typical of many degenerate ovarioles.
- Fig. 9. One-dilated ovariole from a 34 day old nullipar. The pedicel is cellular.
- Fig. 10. One-dilated ovarioles from a 1-par. The upper ovariole has a pedicel of < 2 pedicel cell equivalents and the lower ovariole has no pedicel.

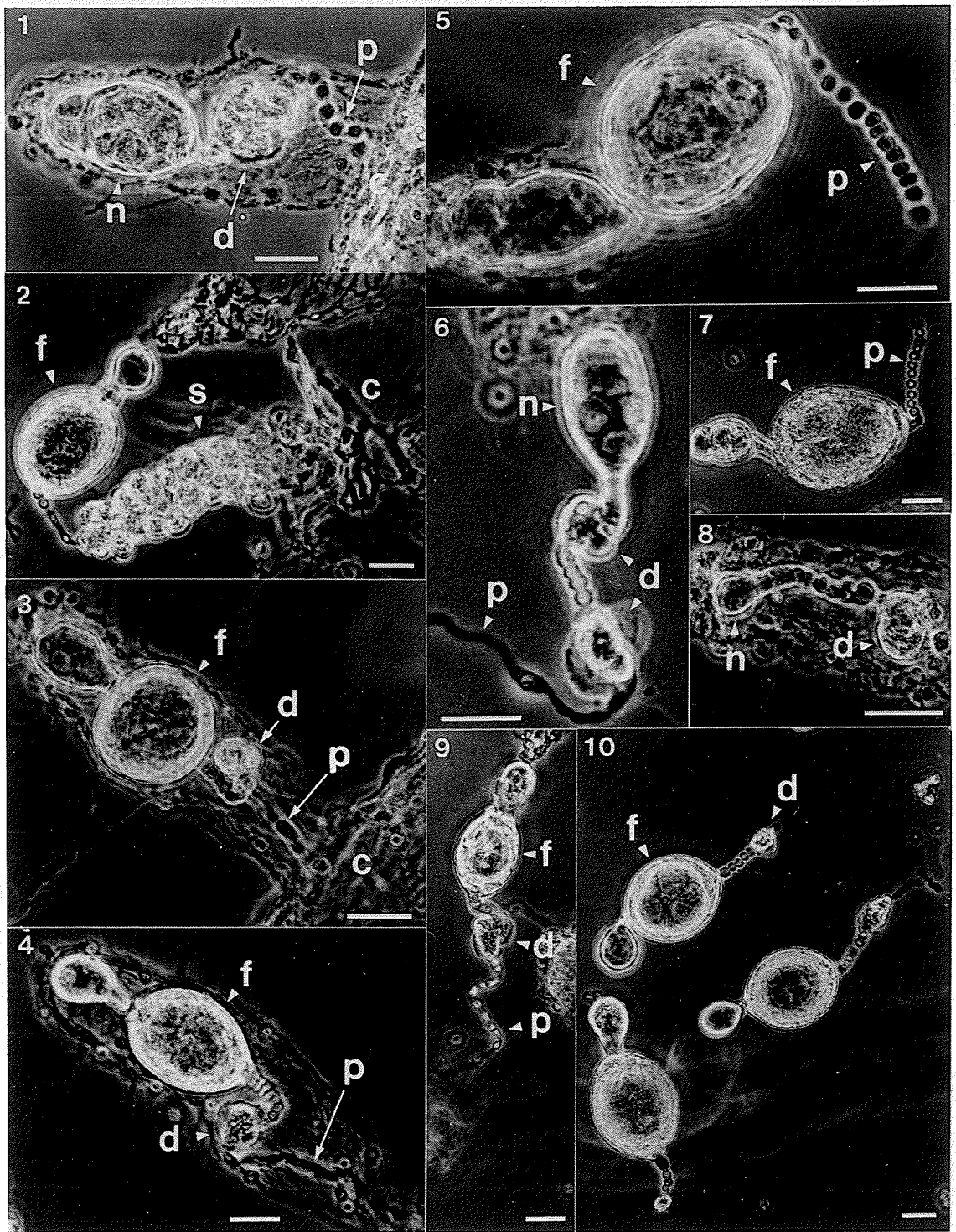
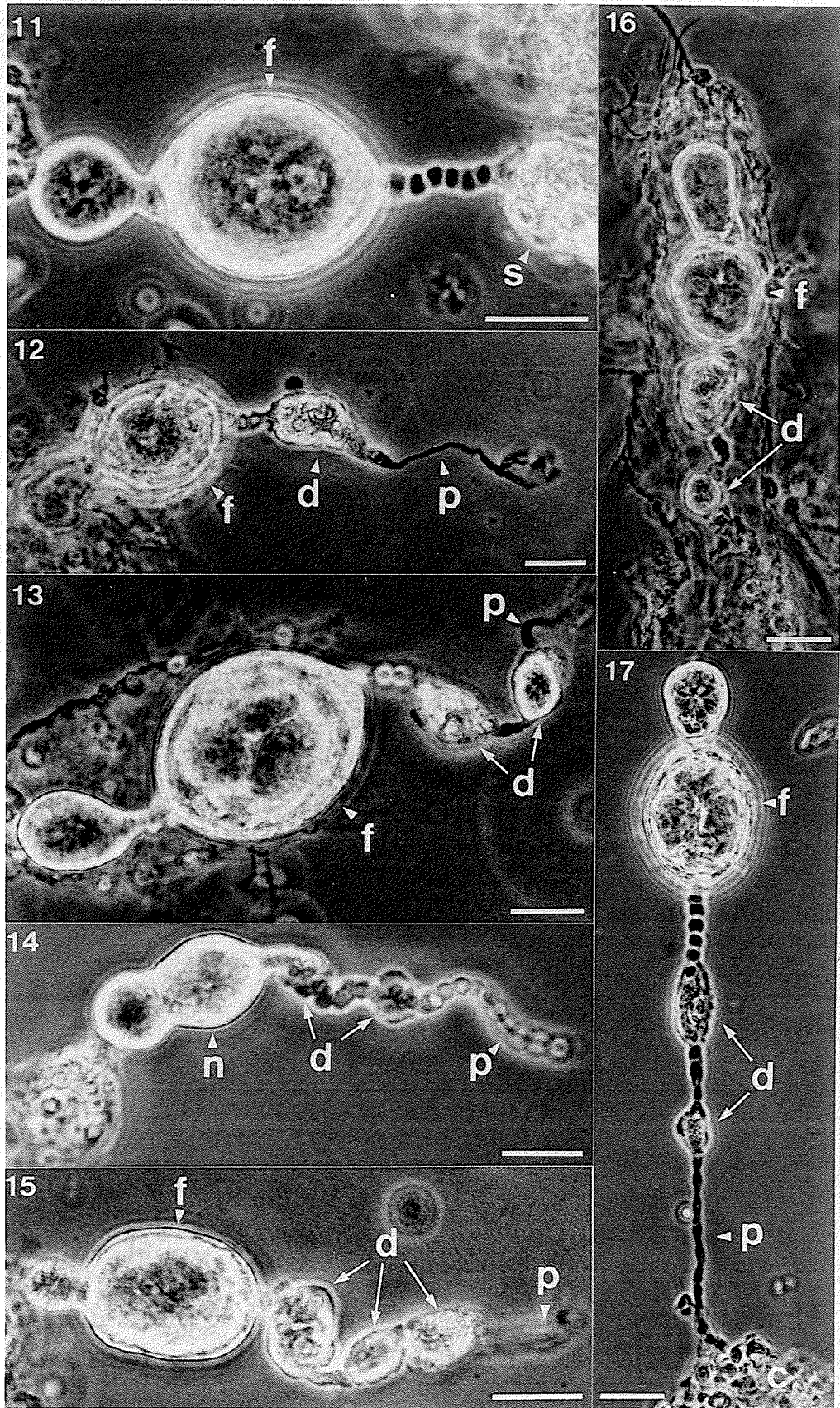


Plate III. Photomicrographs of *Culiseta inornata* ovarioles

Each scale bar represents 25 μ m. c - calyx, d - dilatation, f - follicle at stage I-II (Watts and Smith 1978), n - follicle at stage N, p - pedicel, s - sac.

- Fig. 11. Sacculate ovariole from a 1-par. Follicular debris is concentrated at the anterior end of the shrinking sac. The connecting stalk has six cells.
- Fig. 12. One-dilated ovariole from a 3-par. Note the terminal sac which was part of the calyx.
- Fig. 13. Two-dilated ovariole from a 2-par. The follicle stage, and the prominent and clearly separated dilatations with relics, were typical of this ovariole type in 2-pars.
- Fig. 14. Two-dilated ovariole from a 34 day old nullipar. The pedicel is cellular and the dilatations are small with no relic.
- Fig. 15. Three-dilated ovariole from a 3-par.
- Fig. 16. Two-dilated ovariole from a 3-par. The primary dilatation has a membranous sac.
- Fig. 17. Two dilated ovariole from a gravid nullipar which did not oviposit in the allotted time. The dilatations are small and probably result from early stage degeneration. The pedicel and connecting stalks show a gradation of cellular degeneration.



CHAPTER IV
THE EFFECT OF ROGUE OVARIOLES ON PARITY DIAGNOSIS IN
CULEX TARSALIS (DIPTERA: CULICIDAE)

Abstract

Parity diagnostic criteria were extrapolated from the analysis of ovarioles in nulliparous and known 1-parous *Culex tarsalis* Coquillett. Sixty-eight per cent of nullipars (≤ 10 days of age) had at least one rogue ovariole. The presence of rogue ovarioles causes an overestimation of parity status using Polovodova's method. Polovodova equated the maximum number of dilatations in any ovariole with the parity status of a mosquito. In a blind test, nullipars and known 1-pars (n=46) were correctly classified using the diagnostic criteria.

Introduction

The estimation of disease vector survival rate is important in epidemiology. An estimation of variation in survival rate with gonotrophic age requires the precise determination of parity status in vectors (Dye 1992). Polovodova (1949) reported that the maximum number of dilatations in any ovariole of *Anopheles maculipennis* Meigen was a specific measure of parity status.

Polovodova's (1949) method has been used to age grade a number of mosquito species, and continues to be the only method for determining the precise parity status of parous females. This is despite a change in our understanding of the dynamics of oogenesis and ovulation (Giglioli

1965, Lange and Khok 1981, Hoc and Charlwood 1990). Lange and Khok (1981) hypothesized that an ovariole with one or more dilatations and a pedicel had never ovulated. Prior to this it was assumed that dilatations, connecting stalks and the pedicel reformed after ovulation (Beklemishev *et al.* 1959, Giglioli 1965, Samarawickrema 1962).

Lange and Khok (1981) explained the scarcity of parity diagnostic ovarioles in gonotrophically older females. Their explanation has been supported by a number of Russian researchers (Anufrieva and Artem'ev 1981, Sokolova 1981). Polovodova's (1949) method appears to be accurate for parity assessment in a number of anopheline species (Anufrieva and Artem'ev 1981, Lines *et al.* 1991). However, the occurrence of rogue ovarioles (which cause an overestimation of parity status) in some, mostly culicine, species, has cast doubt on the comprehensive use of the method (Lange and Khok 1981, Magnarelli 1975 and others). The analysis of the maximum number of ovarioles in an undamaged state is important if diagnostic ovarioles are to be found in gonotrophically older females (Lange and Khok 1981). However, the observation of all ovarioles is also likely to maximize the probability of encountering rogue ovarioles.

Knight and Nayar (1982) reported a high frequency of follicle resorption in nulliparous *Culex salinarius* Coquillett, *Culex quinquefasciatus* Say, *Culex restuans* Theobald, *Culex erraticus* (Dyar and Knab) and *Culex opisthopus* Komp. They believed that for *Culex* species, the tracheation method (Beklemishev *et al.* 1959), which separates nullipars from pars, is more reliable than counting dilatations.

Nelson (1964, 1966) and Reisen *et al.* (1983) used Polovodova's (1949) dilatation method to separate nulliparous and known 1-parous

Cx. tarsalis in blind tests, and reported $\geq 98\%$ separation success. Reisen *et al.* (1983) reported an error of 29% in the separation of known 1- and 2-pars, and therefore restricted field studies to the separation of nullipars and pars. McHugh (1990) expected dissectors to separate nullipars and pars with $\geq 90\%$ accuracy. McHugh (1990) and Reisen *et al.* (1983) estimated female survivorship and the duration of the gonotrophic cycle in *Cx. tarsalis* from parous rates established using Polovodova's method. Rosay (1969) reported dilatations (rogue ovarioles) in nulliparous *Cx. tarsalis* but was still able to identify 100%, 91% and 67% of known 1-, 2- and 3-pars respectively.

Culex tarsalis is the primary epidemic vector of Western Equine Encephalomyelitis in Canada (McLintock and Iversen 1975), and therefore the efficacy of parity assessment in this species is important to epidemiologists. The enigma presented by the success in separating nulliparous and known 1-parous *Cx. tarsalis*, and the potential for follicle resorption in nulliparous *Culex* species prompted the current study. The objectives of the study were (1) to determine the frequency of rogue ovarioles in nulliparous, and known 1-parous anautogenous *Cx. tarsalis*, and (2) to assess the effect of rogue ovarioles on the separation of laboratory-reared nullipars and known 1-pars.

Materials and methods

Females in the resorption study were reared from 40 egg rafts collected in July, 1990 at Glenlea Manitoba. Females were reared in environmentally controlled cabinets (Model 1-35 VL, Percival Manufacturing Company, Boone, Iowa), at a temperature of $21.0 \pm 0.2^\circ\text{C}$ and

at photoperiods of 16L:8D, 14L:10D and 8L:16D. Larvae were reared at a density of 400 per 21 X 32 X 7cm polypropylene pan, and were fed an excess of finely ground bovine liver powder (ICN Biochemicals, Inc.). Adults were supplied with 10% sucrose solution and only anautogenous females were used.

Nullipars and pars in the known oviposition study were the F1-7 generations of colonies started in August 1989 and 1990 from egg rafts collected at Glenlea. The colony room was maintained at a temperature of $21 \pm 1^\circ\text{C}$ and a photoperiod of 17L:7D and was equipped with a 2.5 (high) X 1.5 X 1.5 m mating cage. Larvae were reared at a density of four egg rafts per pan.

Wild females were CO₂-light-trapped (SSAM, J.W. Hock Company, Gainesville, FL 32604) at Glenlea, Manitoba, during July and August of 1989.

The sucrose solution was replaced with water when at least 40% of a sample (n=20) of females were inseminated. The females were blood-fed 5 days later. Females were blood-fed at 24°C during scotophase. They were confined to a 30 X 30 X 30cm Plexiglas® cage with two restrained quail for six hours. Nullipars were blood-fed at 7-19 days post eclosion. Nullipars which were less than one third blood-fed were not used. Nullipars were given one chance, and 1-pars were given two chances to blood feed. One-pars were offered blood on the day they oviposited. Three hundred 1-pars, each of which laid > 200 eggs, were offered blood to initiate a second gonotrophic cycle. Blood-fed females were provided with 10% sucrose solution and maintained under colony conditions.

Polystyrene oviposition cups (0.25L) containing water-covered grass sod, were presented to individual females in 18 X 18 X 18cm Plexiglas® cages. Oviposition cups were withheld to control the number of dissections performed each day. Females which did not oviposit immediately were left to oviposit for up to five days within a 6-12 day period after blood feeding.

Dissection and analytical methods were described in Chapter III. Apart from the blind test all females were dissected live. Nullipars in the resorption study were dissected at 2-34 days post eclosion. The diagnostic criteria were developed from the analysis of nullipars dissected at ≤ 10 days post eclosion, and from 1-pars dissected at 2-3 days post oviposition (15-34 d post eclosion). Twenty-nine nullipars and 21 one-pars were frozen for the blind test. The person carrying out the dissections was aware that the females were either nullipars or 1-pars.

Results

Follicle resorption in 2-34 day old nullipars

The number of 0-dilated ovarioles (Figs. 1, 2) found in 120 nullipars ranged from 0-139 per female over 34 days. On average there were fewer 0-dilated ovarioles in older females (Table 1). The mean maximum number of pedicel cells in any 0-dilated ovariole (per female, n=118) was 9.4 ± 0.2 (6-17) cells.

Thirty per cent of females had one rogue ovariole by day 2 (Table 1). All females had at least one rogue ovariole after day 14, with a maximum of 134 in one female on Day 34 (Fig. 8). After day 10, 10-80% of females had 1-24 two-dilated ovarioles, and after day 14, 10-20% of

females had 1-4 three-dilated ovarioles.

Dilatations were found in nullipars reared at 8L:16D and 14L:10D (Figs. 10, 12). Follicle resorption was infrequent at 8L:16D (general observations) although extensive resorption was encountered in some older females (day 34).

Follicles in 99.7% of 0-dilated ovarioles (n=4788) and 64.5% of 1-dilated ovarioles (n=1187) were developed beyond stage N. Fifteen per cent of 2-4 day old (n=20), and 87.3% of 6-34 day old (n=94) anautogenous females, had follicles developed past stage I. Stage I Ib follicles were found in 5.0% and 39.4% of females respectively. Degenerating follicles were found in 48.3% of females ($\bar{x}=4.6\pm 0.6$, range 1-21/female).

Nullipars (≤ 10 days old) and known 1-pars and 2-pars

At least one rogue ovariole was found in 68.4% of nullipars and 55.9% of 1-pars. None were found in 2-pars. The ratio of the mean number of 1-dilated to 0-dilated ovarioles was 0.1:1 in nullipars, 17:1 in 1-pars and 9:1 in 2-pars (Table 2). The maximum follicle stage per female (n=64) was IIa in 12.5%, and IIb in 4.7% of 1-pars.

The percentage of ovarioles which could be categorized was higher in 1-pars (44.2%) than in nullipars (17.3%). There was a > 50% reduction in the mean number of ovarioles categorized in 2-pars compared to 1-pars (Table 2).

Ovarioles with a connecting stalk of \leq five cells and a small sac with no relic (ovariole with a sac, Fig. 9) were found in 93.5% of 1-pars (10.5 ± 1.5). Fifteen pars (three 2-pars) had one 1-dilated

ovariole with a sac.

Infrequent observations included: degenerating follicles with the potential to form more than one dilatation, ovarioles which had developed a new follicle beyond stage N without resorbing the preceding follicle, and dilatations with adjacent cells through them (Table 3. Figs. 5, 11, 12).

Two-dilated ovarioles and one sacculate ovariole with a dilatation, were found in seven sacculate females (dissected shortly after oviposition). The majority of sacculate ovarioles were full of follicular debris and very few had an intact ovariole sheath (Fig. 6). The sac in Fig. 6 appears to terminate at a sphincter in the calyx (Giglioli 1965). The majority of sacculate ovarioles were broken close to the calyx.

Ovariole composition: nullipars, 1-pars and 2-pars

The comparison of 1- or 2-dilated ovarioles in females of different parity status identified trends in ovariole composition common to rogue versus diagnostic ovarioles (Tables 3,4). The extent of pedicel cell degeneration and cell shape was variable in diagnostic ovarioles (Lange and Khok 1981, Figs 3,4,5). Therefore the counting of adjacent cells (Table 3) was somewhat subjective. The three adjacent pedicel cells in Fig. 5 represent the lower limit of classification. Follicles in 37.5% (n=16) and 66.7% (n=6) of 3-dilated ovarioles, in nullipars and 1-pars respectively, were developed beyond stage N. Two or three relics were found in 63.6% of 3-dilated ovarioles (n=22).

The frequency of 1-dilated ovarioles with cellular pedicels was

used as a separation indicator (see below). This feature was a better indicator of the rogue versus diagnostic ovariole, than follicle stage or the presence of a relic (compare Figs. 7,8). However, follicle stage plus the absence of a relic in the secondary dilatation, was a good indication that the ovariole in Fig. 11 was a rogue ovariole. Such an assumption would be reinforced by the quality and composition of the primary connecting stalk, and by the frequency of the ovariole type.

Diagnostic criteria and the separation indicator

Females with \leq five 0-dilated ovarioles and \leq five 1-dilated ovarioles and no 2- or 3-dilated ovarioles were excluded from parity assessment.

Primary diagnostic criteria

- 1 Nullipars had \geq 15 zero-dilated ovarioles.
- 2 Pars had \geq 15 one-dilated ovarioles.

Secondary diagnostic criteria

- 1 When both primary diagnostic criteria could be applied, parity status was assigned in accordance with the more frequent ovariole type, provided that the ratio of types was at least 2:1.
- 2 Females were classified as pars when ovarioles with a sac and sacculate ovarioles were counted with 1-dilated ovarioles (to fit the primary criteria), or the total number of dilated ovarioles was \geq 15.

- 3 Females were classified as nullipars when there were no sacculate ovarioles, and no ovarioles with a dilatation or a sac. Females were classified as pars when there were no 0-dilated ovarioles.

Separation indicator

75.5% of 1-dilated ovarioles in nullipars and 2.2% of 1-dilated ovarioles in 1-pars had a pedicel of ≥ 2 adjacent cells.

Females used to establish the diagnostic criteria (Table 2) fit the primary diagnostic criteria in 93.7% (n=111) of nullipars (3/114 were excluded), 97.8% of 1-pars (n=93), and 81.8% of 2-pars (n=11). Six females fit the secondary diagnostic criteria. Three of five unclassified females fit the separation indicator.

The blind test

There were 29 nullipars and 21 pars in this test. Four nullipars were excluded, one was gravid (autogenous). Fifteen nullipars and 18 one-pars fit the primary diagnostic criteria. The secondary diagnostic criteria and the separation indicator were successfully applied to the remaining 13 females. Nullipars which fit the diagnostic criteria had a mean of 27.3 ± 3.2 0-dilated ovarioles and 1-pars had a mean of 71.0 ± 7.4 1-dilated ovarioles.

CO₂-light-trap study

The parity status of wild females (Table 5) does not include 18 of the females sampled (n=167): nine were excluded (see above), three were fully gravid, and six did not fit the primary or secondary diagnostic criteria. The separation indicator was not applied (the data was collected before the known oviposition study was complete). Females were not separated on the basis of held or retained eggs in order to emphasize the use of the diagnostic criteria. Sixteen females (n=167) retained a mean of 1.6 ± 0.2 (1-4) eggs.

There was a decrease in the frequency of nullipars, and an increase in parity status and the frequency of pars over the five week trapping period (Table 5). Two- and 3-parous females were classified according to Polovodova's (1949) method after they had been diagnosed as pars.

The reclassification of 2- and 3-pars with one diagnostic ovariole (Table 5) increased the proportion of 1-pars by 9.4%, and decreased the proportion of 2-pars and 3-pars by 8.7% and 0.7% respectively. After reclassification, 2-pars had 7.9 ± 1.5 (2-20) 2-dilated ovarioles and 3-pars had 2, 13 and 15 three-dilated ovarioles.

Fifty-five females with 29.8 ± 2.0 (15-88) 0-dilated ovarioles fit the primary diagnostic criteria for nullipars. Of these, 25.5% had 3.3 ± 0.7 (1-10) rogue ovarioles (all 1-dilated). Fifty-eight females with 36 ± 2.3 (15-96) 1-dilated ovarioles fit the primary diagnostic criteria for pars.

Thirty-six females did not fit the primary diagnostic criteria. Fifteen were classified as parous by secondary criterion no. 2. Eighteen

were classified as nulliparous, and three as parous, by secondary criterion no. 3. Three-dilated ovarioles in known 1-pars (Table 2) had smaller follicles than other ovarioles in the same female. This was not the case for 3-dilated ovarioles found in wild females (Table 5).

Discussion

The use of a recently established colony ensured that females were similar to those found in natural populations. However, an extended time period between female eclosion and blood feeding was required to ensure mating success. Therefore, the assumption that females would mate and seek a host at ≤ 10 days of age was not met for all laboratory-reared females. Subsequently, the frequency of rogue ovarioles in wild 1-pars may be lower than the values presented in Table 2. In California, the duration of the gonotrophic cycle for blood-fed *Cx. tarsalis* was 4-6 days, and females took 2-4 days to mate and seek a host (McHugh 1990, Reisen *et al.* 1983, 1992). Rearing conditions could maximize the proportion of ovarian follicles that resorb. Oda *et al.* (1978) believed that the small proportion of wild *Culex tritaeniorhynchus* Giles with resorbed follicles, compared to females maintained in the laboratory, was the result of nullipars finding a host soon after eclosion. Oda *et al.* (1978) reported (for the same species) that the proportion of resorbed follicles was lower in diapausing versus non-diapausing females. There was a low frequency of follicle resorption in diapausing *Cx. tarsalis* (laboratory conditions), and most dilatations were small (personal observation).

The success that Rosay (1969) had in rearing multiparous (4- and

5-parous) *Cx. tarsalis*, and more recent research on ovarian changes during oogenesis (Lange and Khok 1981), indicates that a further study of multiparous *Cx. tarsalis* of known oviposition history may be appropriate. Rosay (1969) believed that age underestimation resulted from the coalescence of dilatations. This assumption was based on the lack of diagnostic ovarioles in gonotrophically older *Cx. tarsalis*. These results may now be interpreted differently. A 3-dilated ovariole of *Cx. quinquefasciatus* photographed by Rosay (1969) had cellular connecting stalks and an intact pedicel. A colony which can produce young (calendar age) multipars would be needed to study gonotrophically older *Cx. tarsalis* of known history. Brust (personal communication) found that females in an older colony (> 60 generations) of *Cx. tarsalis* from Manitoba, had weakened ovarian tissue, which precluded parity assessment using the dilatation method.

Only a small proportion of 1-parous *Cx. tarsalis* (11/300) blood-fed, oviposited and survived until dissected. Therefore, the proportion of naturally occurring 2-pars may be small. Attempts to initiate successive gonotrophic cycles in wild (CO₂-trapped) females was unsuccessful beyond one blood meal and one oviposition cycle (personal observation).

The division of pars into separate parous groups (Table 5) did not account for the effect of age underestimation. The known oviposition study did not extend beyond the 2-parous category, and the sample size for 2-pars was insufficient for confident analysis. The simple manipulation of the data (by one diagnostic ovariole in 2- and 3-pars), shows how rogue ovarioles could affect the proportion of females in the

different parous groups. It is clear that supporting data from known oviposition studies is a prerequisite for specific parity diagnosis in *Cx. tarsalis*.

The occurrence of ovarioles with traces of a sac and no relic (and a connecting stalk of ≤ 5 cells) was useful for identifying pars which had few or no diagnostic ovarioles. The absence of a relic in the sac distinguished these ovarioles from those described by Lange and Khok (1981) and Anufrieva and Artem'ev (1981).

Detinova's (1962) definition of abortive oogenesis can be adapted to fit both autogenous and anautogenous *Cx. tarsalis* (Chapter III). The term abortive is not always used in the sense intended by Detinova (1962). Lange and Khok (1981) used the term to describe all forms of follicle resorption. Once initiated, abortive oogenesis is irreversible (Lea *et al.* 1978). Clements and Boocock (1984) reviewed the different developmental gates documented in mosquito oogenesis. Lea *et al.* (1978) found that *Aedes aegypti* initiated and then arrested oogenesis after imbibing a very small blood meal. Nayar and Knight (1981b) made a distinction between ovarioles with "resorbed follicles" which had the pedicel swollen close to the follicle, and ovarioles with a dilatation and a connecting stalk. Infrequently, primary dilatations were encountered in *Cx. tarsalis* which were proximal to the secondary follicle (i.e. there was no connecting stalk). Ovarioles with pedicels slightly swollen close to the follicle were also encountered. These were not used in the parity diagnosis of *Cx. tarsalis* unless the pedicel had at least six cells (0-dilated ovariole).

Autogenous females were excluded from the current study in order to simplify the experiment. Brust (1991) reported that autogeny levels in *Cx. tarsalis*, reared under natural temperature and photoperiod conditions in southern Manitoba, ranged from 82% in late July to 6% in early September. The effect of autogeny on age grading this species cannot be ignored. The separation of autogenous females and those which have taken a small blood meal seems unlikely using the dilatation method. However, the dilatation method may be more appropriate for identifying females which had laid small rafts than the tracheation method. Burdick and Kardos (1963) achieved a 39%, 80% and 68% success in separating nulliparous, autogenous parous and blood-fed parous *Cx. tarsalis* respectively. Sixty-one per cent of nullipars were misdiagnosed as autogenous parous.

Nelson and Milby (1982) reported that autogenous *Cx. tarsalis* probably did not seek blood until after they had oviposited. Bellamy and Corbet (1973) reported autogenous laboratory-reared *Cx. tarsalis* which imbibed blood in late stages of autogenous development. These females appeared to develop the secondary follicles in all ovarioles. Secondary follicles in ovarioles with eggs were resorbed, whereas secondary follicles in ovarioles with a resorbed primary follicle, developed into an egg. This resulted in an assortment of eggs developed autogenously and anautogenously in the same female. Bellamy and Corbet (1974) suggested that gravid autogenous nullipars could be mistaken for pars with retained eggs. Retained eggs should be removed during dissection because their yolk leaks and obscures the ovarioles (personal observation). The presence of sacs would only be a valid indicator of

recent oviposition if a sac was found in a portion of the ovary which had not retained an egg, or if the number of sacs was greater than the number of eggs removed.

Nelson and Milby (1982) reported that the small proportion of sacculate *Cx. tarsalis* coming to baited traps was an indication that few females sought blood immediately after oviposition. This was supported by Reisen *et al.* (1983) who found that only 9.2% of sacculate females in resting boxes contained blood. If the proportion of wild, sacculate females is to be determined, then sacculate ovarioles can be substituted for 1-dilated ovarioles in the primary diagnostic criteria. If the proportion of females with sacculate ovarioles is high, and they are not a focus of the study, then females can be maintained on sucrose, or water for a day prior to dissection. The number of diagnostic ovarioles found in wild females which were frozen was low and the data was not used.

The application of the diagnostic criteria revealed that rogue ovarioles do occur in wild nulliparous *Cx. tarsalis*. Therefore, there is a need for further laboratory, or controlled outdoor studies of this and other species. A study of follicle resorption in *Cx. restuans* (Appendix IV) support the findings of Knight and Nayar (Table 1 *in* Knight and Nayar 1982) and provide data on the frequency of 0-dilated ovarioles in nulliparous *Cx. restuans*.

It is possible that researchers have recognized, and selectively ignored, the occasional rogue ovariole in nulliparous *Cx. tarsalis*. The current study provides quantitative guidelines for the confident separation of a large proportion of nullipars and pars. Females of

uncertain history can be assigned parity status using the secondary diagnostic criteria and the separation indicator, which although somewhat cumbersome, were not needed to diagnose the majority of females. The problem associated with the potential for autogeny in *Cx. tarsalis* may not be resolved through parity diagnosis. In epidemiology, the need to identify the proportion of autogenous *Cx. tarsalis* in the field, is probably more pressing than the need to identify gonotrophically older females.

Table 1. Mean number of ovarioles in sucrose-fed nulliparous *Culex tarsalis* (10/day) over a 34 day period (21±0.2°C; 16L:8D).

Day	0-dilated ovarioles			1-dilated ovarioles			2-dilated ovarioles			3-dilated ovarioles		
	$\bar{x} \pm SE$	(Range)	#♀♀	$\bar{x} \pm SE$	(Range)	#♀♀	$\bar{x} \pm SE$	(Range)	#♀♀	$\bar{x} \pm SE$	(Range)	#♀♀
2	87.5±8.8	(36-127)	10	1.0±0.0	-	3	-	-	0	-	-	0
4	51.8±11.4	(8-122)	10	2.4±0.5	(1-4)	7	-	-	0	-	-	0
6	46.5±4.1	(28-68)	10	3.1±1.2	(1-11)	8	-	-	0	-	-	0
8	58.3±12.9	(27-139)	10	4.8±0.9	(1-9)	9	-	-	0	-	-	0
10	39.2±8.4	(5-84)	10	5.2±1.3	(1-13)	10	-	-	0	-	-	0
12	30.0±5.9	(9-64)	10	9.9±3.7	(2-35)	9	2.0±0.0	-	1	-	-	0
14	33.8±7.7	(4-74)	9	12.2±9.4	(1-97)	10	2.0±0.3	(1-3)	5	-	-	0
18	40.2±3.2	(3-98)	10	4.5±0.9	(2-12)	10	1.0±0.0	-	3	1.0±0.0	-	1
22	30.2±9.4	(1-90)	10	17.2±3.2	(1-117)	10	2.6±0.9	(1-7)	7	1.5±0.5	(1-2)	2
26	27.4±6.9	(1-67)	10	10.8±7.9	(3-23)	10	5.6±2.8	(1-24)	8	3.5±0.5	(3-4)	2
30	17.7±3.4	(2-33)	10	18.9±5.2	(4-56)	10	1.6±0.4	(1-3)	5	2.0±0.0	-	1
34	19.6±3.8	(4-38)	10	32.2±11.2	(6-126)	10	2.6±0.7	(1-5)	5	1.5±0.5	(1-2)	2

Table 2. Mean number of ovarioles in known nulliparous, 1-parous and 2-parous *Culex tarsalis*.

Cycle	0-dilated ovarioles			1-dilated ovarioles			2-dilated ovarioles			3-dilated ovarioles		
	$\bar{x} \pm SE$	(Range)	% ^{pp} ^a	$\bar{x} \pm SE$	(Range)	% ^{pp}	$\bar{x} \pm SE$	(Range)	% ^{pp}	$\bar{x} \pm SE$	(Range)	% ^{pp}
0 ^b	47.0±2.8	(3-139)	100.0	4.2±0.4	(1-14)	68.4	-	-	0.0	-	-	0.0
1	4.2±0.9	(1-25)	40.9	73.0±4.6	(16-222)	100.0	3.5±0.7	(1-28 ^c)	55.9	1.3±0.3	(1-3 ^c)	6.5
2	3.2±0.6	(1-5)	54.5	29.9±6.5	(6-83)	100.0	4.3±0.9	(1-8)	90.9	-	-	0.0

^aPercentage of females with at least one ovariole in that class (n=114, 93 and 11 for nullipars, 1-pars and 2-pars respectively.

^bIncludes data from Table 1, day 2-10.

^cThis female, unlike other pars 2-3 days post oviposition, had 10 sacculate ovarioles and undigested blood in the gut.

Table 3. Per cent composition of 1-dilated ovarioles^a in nulliparous and 1-parous *Culex tarsalis*.

Structure	Condition	0-pars	1-pars
Dilatation			
	Relic present	60.1	98.0
	No relic	37.0	1.6
	Cellular ^b	2.9	0.3
Pedicel			
	Absent ^c	24.5	86.9
	Acellular ^d	0.0	10.8
	2-4 cells ^e	40.4	1.9
	≥ 5 cells	35.1	0.3

^an=1378 ovarioles from 147 nullipars, n=6793 ovarioles from 93 one-pars.

^bDilatation had a strand of cells through it.

^cBasal dilatation, or pedicel < two pedicel cell equivalents.

^dPedicel ≥ two pedicel cell equivalents.

^eIn part, a single strand of adjacent cells.

Table 4. Per cent composition of 2-dilated ovarioles^a in nulliparous, 1-parous and 2-parous *Culex tarsalis*.

Structure	Condition	0-pars	1-pars	2-pars
Follicle stage				
	N	46.5	45.5	11.6
	> N	53.5	54.5	88.4
Dilatations				
	Relics present	43.4	45.5	72.1
	No relics	20.2	7.9	0.0
	Other ^b	36.4	46.6	27.9
Connecting stalk				
	2 cells	27.3	17.4	2.3
	≥ 3 cells	33.3	44.9	2.3
	Other ^c	39.4	37.7	95.4

^an=99 ovarioles from 34 nullipars, 178 ovarioles from 51 one-pars and 43 ovarioles from 10 two-pars.

^bCombination of two of the following: dilatation had a relic, dilatation had no relic, dilatation had a strand of cells through it.

^cPrimary connecting stalk: acellular, one cell, or nonexistent.

Table 5. Parity status of Culex tarsalis CO₂-light trapped at Glenlea, Manitoba.

Week	n	0-par	1-par	(adj.) ^a	2-par	(adj.)	3-par	(adj.)
30 ^b	35	88.6 ^c	8.6	(11.4)	2.9	(0.0)	0.0	-
31	24	58.3	33.3	(41.7)	8.3	(0.0)	0.0	-
32	31	45.2	35.5	(45.2)	19.4	(9.7)	0.0	-
33	29	27.6	31.0	(41.4)	37.9	(27.6)	3.4	(3.4)
34	30	20.0	36.7	(53.3)	33.3	(20.0)	10.0	(6.7)

^aNumbers of ♀♀ adjusted: 2-pars and 3-pars with one diagnostic ovariole were included in the preceding age class.

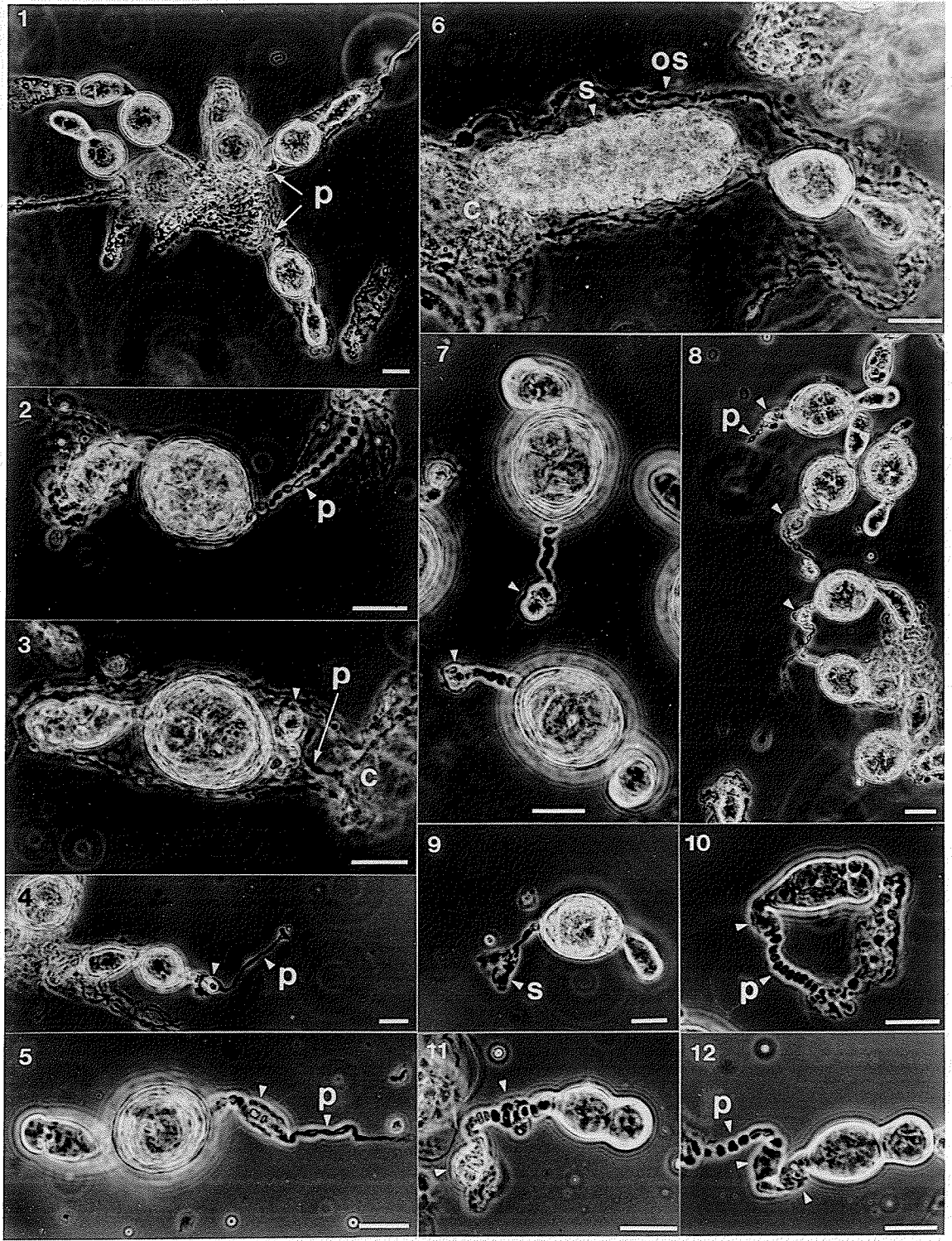
^bWeek ended July 28, 1989.

^cAll values are percentages of n.

Plate IV. Photomicrographs of *Culex tarsalis* ovarioles

Each scale bar represents 25 μ m. c - calyx, os - ovariole sheath, p - pedicel, s - sac, unlabelled arrow - dilatation. The follicles in Figs. 10-12 are at early to late stage N, all other Figs. have follicles at stage I-II. Figs. 1-5, and Fig. 7 show diagnostic ovarioles. Fig. 8 and Figs. 10-12 show rogue ovarioles.

- Fig. 1. Zero-dilated ovarioles from a 30 day old nullipar reared at 8L:16D. The pedicel cells have not degenerated.
- Fig. 2. Zero-dilated ovariole from an 18 day old nullipar reared at 16L:8D. The pedicel is complete.
- Fig. 3. One-dilated ovariole from a 1-par. The dilatation has a relic. The pedicel is attached to the calyx.
- Fig. 4. One-dilated ovariole from a 1-par. The dilatation has a relic. The acellular pedicel was broken where it joined the calyx.
- Fig. 5. One-dilated ovariole from a 1-par. The dilatation has a strand of cells through it, and the pedicel has ≥ 2 adjacent cells.
- Fig. 6. Sacculate ovariole from a 1-par. The sac is separate from the ovariole sheath and appears to be continuous with a sphincter at the calyx.
- Fig. 7. One-dilated ovarioles from a 1-par. The dilatations are basal.
- Fig. 8. One-dilated ovarioles from a 14 day old nullipar reared at 16L:8D. The dilatations have relics and the pedicels are cellular.
- Fig. 9. Ovariole with a sac from a 1-par.
- Fig. 10. One dilated ovariole from a 12 day old nullipar reared at 8L:16D. The dilatation is small and has no relic.
- Fig. 11. Two-dilated ovariole from a 1-par. The primary dilatation is basal and larger than the secondary dilatation, which has a strand of adjacent cells through it.
- Fig. 12. Two-dilated ovariole from a 12 day old nullipar reared at 14L:10D. The pedicel is cellular and complete. The dilatations do not have relics. The primary dilatation has a strand of adjacent cells through it.



CHAPTER V

GENERAL DISCUSSION

Age underestimation and age overestimation are potentially serious problems in the parity diagnosis of *Cs. inornata* and *Cx. tarsalis*. Polovodova's (1949) method is evidently unreliable for the parity diagnosis of gonotrophically younger females of these species. The parity diagnostic criteria, proposed as a modification to Polovodova's (1949) method, are dependent on the assumptions that mosquitoes found in nature undergo similar levels of resorption to laboratory-reared females, and that females mate and seek a host within a prescribed time period. These assumptions present a dilemma because their verification may require the application of the criteria in question.

It may be assumed, given the new hypothesis, that a small egg batch laid in the first cycle, either as a result of autogenous development or a small blood meal, is likely to maximise the probability of finding diagnostic ovarioles with pedicels in gonotrophically older females. This assumption is dependent on the effect of changes in fecundity in subsequent gonotrophic cycles, the effect of random oogenesis and the extent to which ovarioles are quiescent in any cycle. Reduced fecundity with increased gonotrophic age and the incidence of abortive oogenesis are widely documented, but the extent and effects of random oogenesis and the incidence of quiescent follicles are not. Lange and Khok (1981) described random oogenesis as the alternative degeneration or maturation of eggs in different cycles, and a major factor in the destruction of diagnostic ovarioles. Gillies (personal

communication) believes that the occurrence of diagnostic ovarioles in gonotrophically older females of known oviposition history (Gillies and Wilkes 1965) is an indication that at least some ovarioles must be degenerating in a non-random fashion. These questions as well as the mode of ovulation require further study.

The explanation for the decrease or absence of diagnostic ovarioles in gonotrophically older females (Lange and Khok 1981) is a major contribution to understanding the limits of Polovodova's (1949) method. These limits were possibly misinterpreted by some researchers as an inability to perform dissections, or as a lack of multiparous females in nature.

An interesting component of the literature concerning Polovodova's (1949) method is the range of dissection techniques. Beklemishev *et al.* (1959) stretched the ovarioles, hence the sac may appear as a narrow tube. Using the oil injection method of Lange *et al.* (1981) the sac may be inflated before it separates from the calyx. Using the needle method, neither of these are likely to occur. However, the confident application of specific diagnostic criteria, such as the correction factor (Chapter III) requires that ovarioles break at their junction with the calyx. The needle method may be best suited to field studies because it is relatively quick, and all the ovarioles can be viewed under high magnification. Large samples of wild females would be appropriate as well as the modification of the correction factor as more data from known oviposition studies are amassed by different researchers. It is evident from the current studies that specimens should not be frozen, especially if 2- to n-parous females are to be diagnosed.

The separation of nullipars and pars in blind tests was effective using the diagnostic criteria and separation indicators. There was 95% and 100% correct separation for *Cs. inornata* and *Cx. tarsalis* respectively, excluding one gravid female and females with ≤ 5 zero-dilated or ≤ 5 one-dilated ovarioles (6% of females). It may be argued that methods which are quicker but simpler than the dilatation method are adequate for separating nulliparous from parous females. However, the dilatation method not only provides a complex insight into the gonotrophic history of a mosquito, but may also provide a more reliable estimate of the parous rate than the single parameters used by other methods. By widespread use of the dilatation method, it may be demonstrated that it has potential for effective parity diagnosis in a wide range of species. Widespread use of the method may also lead to practical modifications in dissection technique. A reliable estimation of the method's limits for some species is essential for mosquito ecologists and epidemiologists to apply it in the field.

REFERENCES

- Anderson, R.A., and Gallaway, W.J. 1987. The host preferences of *Culiseta inornata* in southwestern Manitoba. J. Am. Mosq. Contr. Assoc. 3: 219-221.
- Anufrieva, U.N., and Artem'ev, M.M. 1981. Refinement of the method of determining the physiological age of female mosquitoes, as exemplified by populations of *Anopheles pulcherrimus* and *An. hyrcanus* in north-eastern Afghanistan, and the fecundity of these species. Med. Parazitol. Parazit. Bolezni 50(6): 55-62. [In Russian, English summary]. [Abstract in Trop. Dis. Bull. 1982. 79: 816-817].
- Barnard, D.R., and Mulla, M.S. 1978. The ecology of *Culiseta inornata* in the Colorado Desert of California: seasonal abundance, gonotrophic status, and oviparity of adult mosquitoes. Ann. Entomol. Soc. Am. 71: 397-400.
- Beckemeyer, E.F. and Lea, A.O. 1980. Induction of follicle separation in the mosquito by physiological amounts of ecdysterone. Science 209: 819-821.
- Beklemishev, W.N., Detinova, T.S., and Polovodova, V.P. 1959. Determination of physiological age in anophelines and of age distribution in anopheline populations in the USSR. Bull. Wld Hlth Org. 21: 223-232.
- Bellamy, R.E., and Corbet, P.S. 1973. Combined autogenous and anautogenous ovarian development in individual *Culex tarsalis* Coq. (Dipt., Culicidae). Bull. entomol. Res. 63: 335-346.
- Bellamy, R.E., and Corbet, P.S. 1974. Occurrence of ovariole dilatations in nulliparous mosquitoes. Mosquito News 34: 334.
- Bertram, D.S. 1962. The ovary and ovarioles of mosquitoes. In Detinova, T.S. Age-grouping methods in Diptera of medical importance. Wld Hlth Org. Monogr. Ser. 47: 195-210.
- Brust, R.A. 1990. Oviposition behaviour of natural populations of *Culex tarsalis* and *Culex restuans* (Diptera: Culicidae) in artificial pools. J. Med. Entomol. 27: 248-255.
- Brust, R.A. 1991. Environmental regulation of autogeny in *Culex tarsalis* (Diptera: Culicidae) from Manitoba, Canada. J. Med. Entomol. 28: 847-853.
- Burdick, D.J., and Kardos, E.H. 1963. The age structure of fall, winter, and spring populations of *Culex tarsalis* in Kern County, California. Ann. Entomol. Soc. Am. 56: 527-535.

- Buth, J.L., Brust, R.A., and Ellis, R.A. 1990. Development time, oviposition activity and onset of diapause in *Culex tarsalis*, *Culex restuans* and *Culiseta inornata* in southern Manitoba. J. Am. Mosq. Contr. Assoc. 6: 55-63.
- Christophers, S.R. 1911. The development of the egg follicle in anophelines. Paludism 2: 73-89.
- Clements, A.N., and Boocock, M.R. 1984. Ovarian development in mosquitoes: stages of growth and arrest, and follicular resorption. Physiological Entomology 9: 1-8.
- Clements, A.N., and Paterson, G.D. 1981. The analysis of mortality and survival rates in wild populations of mosquitoes. J. Appl. Ecol. 18: 373-399.
- Detinova, T.S. 1949. Physiological changes in the ovaries of female *Anopheles maculipennis*. Med. Parazitol. Parazit. Bolezni 18(5): 410-420. [In Russian].
- Detinova, T.S. 1962. Age-grouping methods in Diptera of medical importance. Wld Hlth Org. Monogr. Ser. 47: 1-216.
- Dow, R.P., LaMotte, Jr., L.C., and Crane, G.T. 1976. Post-hibernating *Culex tarsalis* and *Culiseta inornata*: oviparity and tests for virus. Mosquito News 36: 63-68.
- Dye, C. 1992. The analysis of parasite transmission by bloodsucking insects. Annu. Rev. Entomol. 37: 1-19.
- Giglioli, M.E.C. 1963a. The reproductive system of *Anopheles gambiae melas*. Estratto dalla Rivista di Malariologia 42: 149-176.
- Giglioli, M.E.C. 1963b. Aids to ovarian dissection for age determination in mosquitoes. Mosquito News 23: 156-159.
- Giglioli, M.E.C. 1964. The reproductive system of *Anopheles gambiae melas*. Estratto dalla Rivista di Malariologia 43: 265-275.
- Giglioli, M.E.C. 1965. The problem of age determination in *Anopheles melas* Theo. 1903, by Polovodova's method. Cah. O.R.S.T.O.M. Entomol. Med. 3 et 4: 157-177.
- Gillies, M.T. 1956. A new character for the recognition of nulliparous females of *Anopheles gambiae*. Bull. Wld Hlth Org. 15: 451-459.
- Gillies, M.T., and Wilkes, T.J. 1965. A study of the age-composition of populations of *Anopheles gambiae* Giles and *A. funestus* Giles in north-eastern Tanzania. Bull. entomol. Res. 56 237-262.

- Gozhenko, V.A. 1980. Some peculiarities of oogenesis in *Mansonia richiardii* (Ficalbi) 1889. Med. Parazitol. Parazit. Bolezni 49(3): 58-61. [In Russian, English summary].
- Gwadz, R.W., and Spielman, A. 1973. Corpus allatum control of ovarian development in *Aedes aegypti*. J. Insect Physiol. 19: 1441-1448.
- Hagedorn, H.H., Turner, S., Hagedorn, E.A., Pontecorvo, D., Greenbaum, P., Pfeiffer, D., Wheelock, G., and Flanagan, T.R. 1977. Postemergence growth of the ovarian follicles of *Aedes aegypti*. J. Insect Physiol. 23: 203-206.
- Hayashi, S., and Kurihara, T. 1965. Studies on the age of mosquitoes. I. The determination of physiological age of *Culex pipiens pallens* by the relics formed at ovarioles after the oviposition. Jpn. J. Sanitary Zool. 16: 29-33. [In Japanese, English summary].
- Henderson, L.P., and Brust, R.A. 1977. Studies on the potential transovarial transmission of Western Equine Encephalomyelitis virus by *Culex tarsalis* Coquillett. Manitoba Entomol. 11: 69-73.
- Hitchcock, J.C. 1968. Age composition of a natural population of *Anopheles quadrimaculatus* Say (Diptera: Culicidae) in Maryland, U.S.A. J. Med. Entomol. 5: 125-134.
- Hoc, T.Q. 1975. Structure of the pedicel and connective peduncles of the ovariole in culicid mosquitoes. Additional new traits for determination of physiological age. Moscow Univ. Biol. Sci. Bull. 30(3-4): 73-76. [English translation].
- Hoc, T.Q., and Charlwood, J. D. 1990. Age determination of *Aedes cantans* using the ovarian oil injection technique. Med. Vet. Entomol. 4: 227-233.
- Hudson, J.E. 1977a. Seasonal biology of *Anopheles*, *Culex* and *Culiseta* in central Alberta, (Diptera: Culicidae). Ph.D. thesis, University of Alberta, Edmonton, AB.
- Hudson, J.E. 1977b. Induction of diapause in female mosquitoes, *Culiseta inornata* by a decrease in daylength. J. Insect Physiol. 23: 1377-1382.
- Hudson, J.E. 1979. Follicle development, blood feeding, digestion and egg maturation in diapausing mosquitoes, *Culiseta inornata*. Entomol. exp. and appl. 25: 136-145.
- Kay, B.H. 1979. Age structure of populations of *Culex annulirostris* (Diptera: Culicidae) at Kowanyama and Charville, Queensland. J. Med. Entomol. 16: 309-316.

- Knight, J.W., and Nayar, J.K. 1982. Evaluation of ovarian age grading techniques for Florida *Culex* mosquitoes. *J. Fla. Anti Mosq. Assoc.* 53: 8-12.
- Lange, A.B., and Khok, C.K. 1981. Abortive oogenesis and the physiological age of blood-sucking mosquitoes (Diptera: Culicidae). *Med. Parazitol. Parazit. Bolezni* 50(3): 48-56. [In Russian, English summary]. [Abstract in *Trop. Dis. Bull.* 1982. 79: 816-817].
- Lange, A.B., Khok, C.K., and Sokolova, M.I. 1981. The method of intraovarian oil injection and its use in the determination of the physiological age of female blood-sucking mosquitoes. *Med. Parazitol. Parazit. Bolezni.* 50(4): 51-53. [In Russian].
- Laurence, B.R., and Simpson, M.G. 1974. Cell replication in the follicular epithelium of the adult mosquito. *J. Insect Physiol.* 20: 703-715.
- Lea, A.O., Briegel, H., and Lea, H.M. 1978. Arrest, resorption, or maturation of oocytes in *Aedes aegypti*: dependence on the quantity of blood and the interval between blood meals. *Physiological Entomology* 3: 309-316.
- Lehane, M.J., and Laurence, B.R. 1978. Development of the calyx and lateral oviduct during oogenesis in *Aedes aegypti*. *Cell Tissue Res.* 193: 125-137.
- Lines, J.D., Wilkes, T.J., and Lyimo, E.O. 1991. Human malaria infectiousness measured by age-specific sporozoite rates in *Anopheles gambiae* in Tanzania. *Parasitology* 102: 167-177.
- Liu, T. 1968. Observations on the physiological age of *Culex pipiens pallens* Coquillett, and *Aedes albopictus* Skuse. *Acta Entomol. Sinica* 2: 17-25. [English translation].
- Magnarelli, L.A. 1975. Egg retention in mosquitoes (Diptera: Culicidae) and its relation to physiological age. *Mosquito News* 35: 396-399.
- McHugh, C.P. 1990. Survivorship and gonotrophic cycle length of *Culex tarsalis* (Diptera: Culicidae) near Sheridan, Placer County, California. *J. Med. Entomol.* 27: 1027-1030.
- McLintock, J. 1952. Continuous laboratory rearing of *Culiseta inornata* (Will.) (Diptera: Culicidae). *Mosquito News* 12: 195-201.
- McLintock, J., and Iversen, J. 1975. Mosquitoes and human disease in Canada. *Can. Entomol.* 107: 695-704.

- Meyer, R.P. and Washino, R.K. 1978. Seasonal activity, relative abundance, autogeny, and physiological age in central Californian populations of *Culiseta inornata* (Williston). 46th Ann. Conf. Calif. Mosq. Vect. Assoc. Jan. 29 - Feb. 1, pp. 54-55.
- Meyer, R.P., Washino, R.K., and McKenzie, T.L. 1982. Studies on the biology of *Culiseta inornata* (Diptera: Culicidae) in three regions of central California, USA. J. Med. Entomol. 19: 558-568.
- Mitchell, C.J. 1979. Winter survival of *Culex tarsalis* (Diptera: Culicidae) hibernating in mine tunnels in Boulder County, Colorado, USA. J. Med. Entomol. 6: 482-487.
- Nayar, J.K., and Knight, J.W. 1981a. Occurrence of ovariole dilatations in nulliparous mosquitoes: *Culex nigripalpus*. Mosquito News 41: 281-287.
- Nayar, J.K., and Knight, J.W. 1981b. Ovarian development in *Culex nigripalpus* and its implication for disease transmission. Entomol. Exp. Appl. 29: 49-59.
- Nayar, J.K., and Sauerman, Jr., D.M. 1975. The effects of nutrition on survival and fecundity in Florida mosquitoes. Part 3. Utilization of blood and sugar for fecundity. J. Med. Entomol. 12: 220-225.
- Nelson, R.L. 1964. Parity in winter populations of *Culex tarsalis* Coquillett in Kern County, California. Am. J. Hyg. 80: 242-253.
- Nelson, R.L. 1966. A comparison of two techniques for distinguishing parous from nulliparous *Culex tarsalis* Coquillett. Mosquito News 26: 11-13.
- Nelson, R.L., and Milby, M.M. 1982. Autogeny and blood-feeding by *Culex tarsalis* (Diptera: Culicidae) and the interval between oviposition and feeding. Can. Entomol. 114: 515-521.
- Nicholson, A.J. 1921. The development of the ovary and ovarian egg of a mosquito, *Anopheles maculipennis*, Meigen. Quart. J. Micr. Sci. 65: 395-448.
- Oda, T., Wada, Y., and Mori, A. 1978. Follicular degeneration in unfed nulliparous females of *Culex tritaeniorhynchus*. Tropical Medicine 20: 113-122.
- Owen, W.B. 1942. The biology of *Theobaldia inornata* Williston, in captive colony. J. Econ. Entomol. 35: 903-907.
- Polovodova, V.P. 1949. The determination of the physiological age of female *Anopheles*, by the number of gonotrophic cycles completed. Med. Parazitol. Parazit. Bolezni 18(4): 352-355. [In Russian].

- Reisen, W.K., Meyer, R.P., and Milby, M.M. 1989. Studies on the seasonality of *Culiseta inornata* in Kern County, California. J. Am. Mosq. Contr. Assoc. 5: 183-195.
- Reisen, W.K., Milby, M.M., and Meyer, R.P. 1992. Population dynamics of adult *Culex* mosquitoes (Diptera: Culicidae) along the Kern River, Kern County, California, in 1990. J. Med. Entomol. 29: 531-543.
- Reisen, W., Milby, M., Reeves, W., Meyer, R., and Bock, M. 1983. Population ecology of *Culex tarsalis* (Diptera: Culicidae) in a foothill environment of Kern County, California: temporal changes in female relative abundance, reproductive status and survivorship. Ann. Entomol. Soc. Am. 76: 800-808.
- Rosay, B. 1969. Anatomical indicators for assessing age of mosquitoes: Changes in ovarian follicles. Ann. Entomol. Soc. Am. 62: 605-611.
- Samarawickrema, W.A. 1962. Changes in the ovariole of *Mansonia (Mansonioides)* mosquitoes in relation to age determination. Ann. Trop. Med. Parasitol. 56: 110-126.
- Schmidt, J.M., and Friend, W.G. 1991. Ingestion and diet destination in the mosquito *Culiseta inornata*: effects of carbohydrate configuration. J. Insect Physiol. 37: 817-828.
- Shalaby, A.M. 1971. Changes in the ovaries of *Anopheles multicolor* and *Anopheles pharoensis* (Diptera: Culicidae) following oviposition. Z. ang. Entomol. 69: 187-197.
- Shemanchuk, J.A. 1965. On the hibernation of *Culex tarsalis* Coquillett, *Culiseta inornata* Williston, and *Anopheles earlei* Vargas (Diptera: Culicidae) in Alberta. Mosquito News 25: 456-462.
- Sokolova, M.I. 1981. Age changes and morphological types of ovarioles of females of a northern population of blood-sucking mosquitoes, *Aedes caspius dorsalis* Meig. Med. Parazitol. Parazit. Bolezni 50(6): 63-70. [In Russian, English summary].
- Sokolova, M.I. 1983. Diagnostic importance of the structure of the ovarioles for the determination of the physiological age of blood-sucking mosquitoes (Diptera: Culicidae). Med. Parazitol. Parazit. Bolezni 61(2): 53-58. [In Russian, English summary].
- Sokolova, M.I., and Lange, A.B. 1989. Morphofunctional changes in the ovarioles of blood-sucking mosquitoes (Diptera, Culicidae) during oogenesis: 2. Abortive oogenesis. Med. Parazitol. Parazit. Bolezni 58(3): 55-60. [In Russian, English summary].

- Spencer, M. 1979. Age grouping of female *Anopheles farauti* populations (Diptera: Culicidae) in Papua New Guinea. *J. Med. Entomol.* **15**: 555-569.
- Trueman, D.W., and McIver, S.B. 1983. Seasonal incidence of single and multiple parity in *Mansonia perturbans* (Diptera: Culicidae). *Can. Entomol.* **115**: 435-438.
- Watts, R.B., and Smith, S.M. 1978. Oogenesis in *Toxorhynchites rutilus* (Diptera: Culicidae). *Can. J. Zool.* **56**: 136-139.
- Wood, D.M., Dang, P.T., and Ellis, R.A. 1979. The insects and arachnids of Canada. Part 6. Mosquitoes of Canada. *Can. Dept. Agric. Publ.* 1686. 390 pp.

APPENDICES

Appendix I. Nulliparous (21°, 24°C) and 1-parous (21°C) *Culiseta inornata**Nullipars (24°C, 16L:8D)*

The mean number of ovarioles per female (n=90) was 173.1 ± 3.6 (99-323). Eighty-two per cent of females (n=90) had a mean of 5.0 ± 0.6 (1-31) ovarioles with a rudimentary stage N secondary follicle (non-functional germarium) and a normal primary follicle. The mean maximum number of pedicel cells in any 0-dilated ovariole (per female, n=88) was 11.2 ± 0.3 (6-19) cells.

Eighty-three per cent of 1-dilated ovarioles (n=128) had dilatations with a relic, 14% had dilatations with no relic and 3% had a string of cells through the dilatation. Eighty per cent of 2-dilated ovarioles (n=10) had a relic in both dilatations.

The secondary follicle in 67% of 1-dilated ovarioles had developed beyond stage N.

Ten per cent of females (n=100) were autogenous. Five autogenous females had a mean of 21.0 ± 4.7 (5-34) eggs (larvae and pupae were reared at 21°C).

Nullipars and known 1-pars and 2-pars (21°)

Forty per cent of nullipars (Table 1, Chapter III) had a mean of 2.9 ± 0.6 (1-9) degenerating follicles (defined in Chapter III). The mean length of normal follicles per sample day (n=100, 10/♀) ranged from $73.9 \pm 1.2 \mu\text{m}$ (day 6) to $95.2 \pm 1.9 \mu\text{m}$ (day 26).

Six 1-pars were dissected the morning after oviposition (only five egg rafts were counted). Each female had a mean of 163.0 ± 10.0 (125-196) ovarioles and laid a mean of 117.6 ± 3.7 (104-126) eggs. Each female had a mean of 69.2 ± 10.0 (48-108) sacculate ovarioles and a mean of 33.5 ± 4.9 (17-52) 1-dilated ovarioles. Sixty-one per cent of 1-dilated ovarioles (n=201) had a basal dilatation. Two females had one 0-dilated ovariole, five females had a mean of 1.4 ± 0.2 (1-2) 2-dilated ovarioles, and one female had one 3-dilated ovariole.

Sixty-eight per cent of 1-pars (n=57) had a mean of 3.7 ± 0.4 (1-9) ovarioles with a sac (defined in Chapter IV).

Table 1. Mean number of ovariotes in sucrose-fed nulliparous *Culiseta inornata* over a 24 day period (24±0.2°C; 16L:8D).

Day	n	0-dilated ovariotes			1-dilated ovariotes			2-dilated ovariotes		
		$\bar{x} \pm SE$	(Range)	#♀♀	$\bar{x} \pm SE$	(Range)	#♀♀	$\bar{x} \pm SE$	(Range)	#♀♀
2	10	108.1±11.6	(55-165)	10	-	-	0	-	-	0
4	10	120.5±7.7	(84-163)	10	1.0±0.0	-	2	-	-	0
6	10	110.0±15.8	(50-201)	10	3.0±2.0	(1-5)	2	-	-	0
8	8 ^a	88.9±9.7	(54-137)	8	4.0±0.0	-	1	-	-	0
10	6	75.0±17.2	(26-142)	6	6.0±0.0	-	1	-	-	0
12	10	95.8±9.7	(44-143)	10	1.4±0.3	(1-3)	7	-	-	0
14	9	90.9±9.8	(26-123)	9	2.3±0.5	(2-4)	4	-	-	0
16	9	87.2±12.7	(10-126)	9	4.0±1.0	(2-8)	5	1.0±0.0	-	1
20	9	39.7±11.2	(1-114)	9	4.5±2.7	(1-18)	6	2.0±0.6	(1-3)	3
24	9	73.1±12.0	(26-137)	9	6.0±3.5	(1-27)	7	1.0±0.0	-	3

^a10-n autogenous females excluded.

Appendix II. The separation of 1-parous from 2-parous *Culiseta inornata*

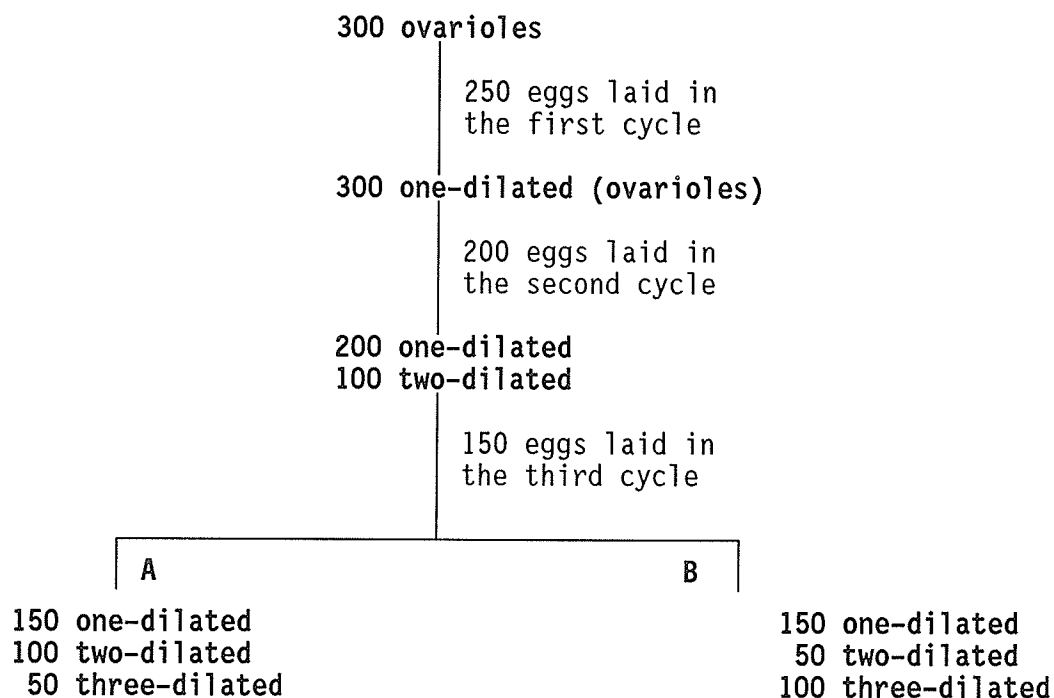
# 2-d. ovarioles	1-pars (n=57)	2-pars (n=50)
0	32	5
1	13	2
2	6	2
3	3	4(1) ^a
4	2	2(1)
5	0	3(1)
6	1	3
7	0	2
>7	0	27(11)

^aNumber of females with at least one 3-dilated ovariole.

A correction factor of 1.43 was calculated by dividing the actual number of 2-pars (50) by the number of 2-pars (35) which fit the diagnostic criteria. The factor accounts for 2-pars which would be misdiagnosed as 1-pars because they had 0-4 two-dilated ovarioles. The factor, multiplied by the number of wild females diagnosed as 2-pars, gives the number of 1-pars which should be classed as 2-pars in a sample of unknowns. The correction factor is based on the separation of 2-pars using 2-dilated ovarioles (and not 3-dilated ovarioles). The one 1-par which had six 2-dilated ovarioles was classed as an outlier and ignored.

Appendix III. The effect of random oogenesis on the frequency of diagnostic ovarioles

Fecundity was reduced in each gonotrophic cycle. It was assumed that all ovarioles participated in either abortive or normal oogenesis, dilatations formed in accordance with the new hypothesis (Chapter I), and diagnostic ovarioles may or may not have a pedicel.



- A** Random oogenesis. To simulate random oogenesis it was assumed that equal proportions of ovariole types were committed to normal oogenesis.
- B** Nonrandom oogenesis. An ovariole, once committed to abortive oogenesis, was committed to abortive oogenesis in subsequent cycles.

The occurrence of 2- to n-dilated diagnostic ovarioles (\pm pedicel) is dependent on abortive oogenesis. The number of diagnostic ovarioles may be increased by a reduction in fecundity, and decreased by the effects of random oogenesis. The frequency of dilated diagnostic ovarioles with a pedicel, would be affected by random oogenesis during the second cycle. In a normal ovary there may be a small proportion of quiescent follicles in different ovariole types in each cycle. This would complicate the phenomena described above.

Appendix IV. Nulliparous *Culex restuans* (21°C)

The mean maximum number of pedicel cells in any 0-dilated ovariole (per female, n=117) was 11.1 ± 0.2 (6-17) cells.

Fifty-two per cent of dilatations in 1-dilated ovarioles (n=696) had a relic, 41% lacked a relic and 8% had a strand of cells through the dilatation. Twenty-three per cent of 1-dilated ovarioles had a basal dilatation, one had an acellular pedicel and the remainder (77%) had pedicels with more than two adjacent cells (62% of these had ≥ 5 cells).

The proportion of 0-dilated ovarioles (n=5584) with a stage N primary follicle was 0.1%. Forty-seven per cent of 1-dilated ovarioles had a stage N secondary follicle.

Table 1. Mean number of ovariols in sucrose-fed nulliparous *Culex restuans* (10/day) over a 34 day period (21±0.2°C; 16L:8D).

Day	0-dilated ovariols			1-dilated ovariols			2-dilated ovariols			3-dilated ovariols		
	$\bar{x} \pm SE$	(Range)	#♀♀	$\bar{x} \pm SE$	(Range)	#♀♀	$\bar{x} \pm SE$	(Range)	#♀♀	$\bar{x} \pm SE$	(Range)	#♀♀
2	46.8±4.1	(27-76)	10	1.0±0.0	-	1	-	-	0	-	-	0
4	82.8±7.3	(47-126)	10	2.0±0.6	(1-3)	3	-	-	0	-	-	0
6	76.9±5.9	(62-116)	10	2.3±0.5	(1-6)	10	-	-	0	-	-	0
8	75.5±5.2	(45-96)	10	4.0±0.6	(2-8)	9	-	-	0	-	-	0
10	56.5±4.8	(29-72)	10	4.4±1.2	(1-13)	10	-	-	0	-	-	0
12	47.5±5.7	(20-79)	10	3.2±1.4	(1-14)	9	-	-	0	-	-	0
14	41.7±6.3	(15-77)	10	8.1±2.1	(1-16)	9	1.0±0.0	-	1	-	-	0
18	20.0±3.3	(6-37)	10	12.3±4.7	(2-40)	8	-	-	0	-	-	0
22	28.4±3.2	(9-68)	10	6.9±1.4	(1-13)	10	2.0±0.6	(1-3)	4	-	-	0
26	21.9±3.8	(7-40)	10	10.7±2.3	(3-25)	10	3.0±0.6	(2-4)	3	2.0±0.0	-	2
30	33.8±7.6	(9-93)	10	7.6±2.0	(1-17)	10	1.7±0.3	(1-2)	3	-	-	0
34	26.6±7.6	(2-82)	10	14.9±5.4	(1-44)	9	2.3±0.9	(1-4)	3	-	-	0

Appendix V. Ovarioles in multiparous autogenous-anautogenous *Culiseta inornata*

Each scale bar represents 25 μ m. bd - basal dilatation, c - calyx, df - degenerating follicle, f - follicle at stage I-II (Watts and Smith 1978), lc - lumen of calyx, o - oocyte, p - pedicel, t - trophocyte, unlabelled arrow - dilatation.

- Fig. 1 One of three diagnostic ovarioles found in a 35-37 day old F11 four-par which laid 101 eggs in the fourth cycle.
- Fig. 2 One of seven 4-dilated ovarioles found in a 50-52 day old F8 five-par which laid 54 eggs in the fifth cycle. The intact pedicel indicates that this ovariole is diagnostic (Lange and Khok 1981). However, diagnostic ovarioles were not found in this female.
- Fig. 3 One of nine diagnostic ovarioles found in a 24-26 day old F10 three-par. This ovariole never ovulated. One rogue ovariole was found in this female.
- Fig. 4 Longitudinal plastic section (2 μ m) of nulliparous ovary 2-5 hours post adult eclosion. The follicles are at stage N.
- Fig. 5 One of two 4-dilated ovarioles with the fifth follicle degenerating (5-par described in Fig. 2). In the absence of diagnostic ovarioles, this ovariole type provided the best indication of parity status.
- Fig. 6 One-dilated ovariole which ovulated in the fourth cycle (4-par described in Fig. 1).
- Fig. 7 One of eight diagnostic ovarioles found in a 24-26 day old F10 three-par. This ovariole ovulated in the first cycle, but not in subsequent cycles.

Females were selected for autogeny and maintained on 3% sucrose at a temperature of 24°C and a photoperiod of 16L:8D. Nullipars of alternate generations (except F9), and all pars, were blood-fed. Females were dissected 1-2 days after oviposition.

F8 one-pars (n=56) laid a mean (\pm SE) of 30.7 \pm 1.6 autogenously developed eggs. F11 one-pars (n=9) laid a mean of 14.2 \pm 2.1 autogenously developed eggs. F10 one-pars (n=15) laid a mean of 218.3 \pm 11.1 anautogenously developed eggs.

