

IMMUNITY AND INFLAMMATION AS SYNERGISTIC
MECHANISMS IN THE PATHOGENESIS OF PERIODONTAL DISEASE

A Thesis Presented To

The Faculty of Graduate Studies
The University of Manitoba

In Partial Fulfillment
of the Requirements of the Degree

MASTER OF SCIENCE

by

Henry M. Dick, D.D.S.

Graduate Dental Research Fellow
N.R.C. (Associate Committee of Dental Research)
Department of Oral Pathology

MAY, 1968⁴



"Read not to contradict and confute nor to believe
and take for granted, but to weigh and consider"

Bacon

CONTENTS

	<u>Page</u>
ABSTRACT	1
ACKNOWLEDGEMENTS	2
INTRODUCTION	3

PART I

PERIODONTAL DISEASE AND THE ROLE OF IMMUNE MECHANISMS

RELEVANT CONCEPTS

<u>PERIODONTAL DISEASE</u>	4
<u>THE PERIODONTIUM</u>	4
THE PERIODONTAL MEMBRANE	5
THE EPITHELIAL ATTACHMENT	6
THE BLOOD SUPPLY	7
<u>HOST-PARASITE RELATIONSHIPS</u>	8
FACTORS OPERATING AGAINST THE HOST	9
The Parasite	9
Local Irritants	10
Systemic Factors	11
FACTORS OPERATING IN DEFENCE OF THE HOST	12
Local Factors	12
General Factors	13
<u>INFLAMMATION AND TISSUE INJURY</u>	14
INFLAMMATION	15
HYPERSENSITIVITY REACTIONS	16

	<u>Page</u>
<u>IMMUNE REACTIONS AND PERIODONTAL DISEASE</u>	19
HOST RESPONSE (IMMUNOLOGICAL) TO INDIGENOUS ORAL FLORA	19
HYPERSENSITIVITY REACTIONS IN ORAL TISSUES	20
AUTOIMMUNITY AND PERIODONTAL DISEASE.	22
SUMMARY	23

PART II

THE PRIMARY IMMUNE RESPONSE OF MICE TO HORSE FERRITIN
AND BOVINE SERUM ALBUMIN ANTIGENS

OBJECTS OF THE INVESTIGATION	25
INTRODUCTION	26
MATERIALS AND METHODS	28
<u>SENSITIZATION OF ANIMALS</u>	28
<u>SERUM PREPARATION AND ANTIBODY ASSAY</u>	29
<u>TISSUE METHODOLOGY</u>	31
<u>REACTION TO CHALLENGE WITH HOMOLOGOUS ANTIGEN</u>	35
<u>STATISTICAL METHODS</u>	35
RESULTS	37
<u>PRIMARY RESPONSE OF BSA STIMULATED MICE</u>	37
SEROLOGY	37
LYMPH NODE CHANGES	37
H&E Stain	40
Prussian blue Stain	43
CHANGES OBSERVED IN THE SPLEEN	43
H&E Stain	43
Prussian blue Stain	46

	<u>Page</u>
LYMPH NODE PREPLASMA CELL COUNTS	49
REACTION TO CHALLENGE WITH BSA	49
<u>PRIMARY RESPONSE OF HORSE FERRITIN STIMULATED MICE.</u>	52
SEROLOGY	52
LYMPH NODE CHANGES	52
H&E Stain.	52
Prussian blue Stain	55
CHANGES OBSERVED IN THE SPLEEN	55
H&E Stain	55
Prussian blue Stain	55
LYMPH NODE PREPLASMA CELL COUNTS	57
REACTION TO CHALLENGE WITH HORSE FERRITIN	57
DISCUSSION	63
SUMMARY AND CONCLUSIONS	69

PART III

THE EFFECT OF TRAUMATIC INFLAMMATION ON THE LOCAL IMMUNE REACTION IN ORAL TISSUES OF HORSE FERRITIN SENSITIZED MICE

OBJECTS OF THE INVESTIGATION	71
INTRODUCTION	72
<u>TERMINOLOGY</u>	
TRAUMATIC INFLAMMATION	72
ALLERGIC INFLAMMATION	72
SENSITIZATION AND CHALLENGE	72
<u>ALLERGIC INFLAMMATION</u>	73
PLATELET AGGLUTINATION	73

	<u>Page</u>
DEGRANULATION OF MAST CELLS	74
POLYMORPHONUCLEAR LEUKOCYTE CHEMOTAXIS	75
 MATERIALS AND METHODS	
<u>GENERAL PLAN AND LESION CLASSIFICATION</u>	79
<u>PREPARATION OF ANIMAL SUB-GROUPS</u>	80
NON-SENSITIZED ANIMALS: LOCAL REACTION SITE	80
Traumatic Inflammation.	80
Primary H Fe and Inflammation + Primary H Fe	82
SENSITIZED ANIMALS: LOCAL REACTION SITE	82
Traumatic Inflammation	82
Challenge and Inflammation + Challenge	83
<u>PRUSSIAN BLUE CONTROLS</u>	83
<u>TISSUE METHODOLOGY</u>	83
SEROLOGY.	83
PREPARATION OF SOFT TISSUE SECTIONS	84
Fluorescent Staining	84
H&E Preparations	85
Prussian blue Preparations	86
Carbol Fuchsin-Wright's Preparations	86
<u>VALIDITY OF OBSERVATIONS</u>	87
<u>STATISTICAL METHODS</u>	88
RESULTS	90
<u>NORMAL TISSUE</u>	90
<u>NON-SENSITIZED ANIMALS: LOCAL REACTION SITE</u>	91
TRAUMATIC INFLAMMATION	91
PRIMARY H Fe	92

	<u>Page</u>
H&E Preparations	92
Prussian blue Preparations.	92
Tissue Fluorescence	95
INFLAMMATION + PRIMARY H Fe	95
H&E Preparations	95
Prussian blue Preparations.	97
Tissue Fluorescence	97
<u>SENSITIZED ANIMALS: LOCAL REACTION SITE</u>	97
TRAUMATIC INFLAMMATION.	98
CHALLENGE	98
H&E Preparations	98
Prussian blue Preparations	101
Tissue Fluorescence	101
INFLAMMATION + CHALLENGE	103
H&E Preparations.	103
Prussian blue Preparations	106
Tissue Fluorescence	107
<u>PRUSSIAN BLUE CONTROLS</u>	107
DISCUSSION	108
<u>THE VALIDITY OF THE IMMUNE REACTION</u>	108
ANIMAL SENSITIZATION.	108
INTERPRETATION OF PRUSSIAN BLUE STAINING AND FLUORESCENCE	108
Prussian blue Staining	109
Fluorescent Staining.	110
The Presence of Antibody and Antigen as Immune Complexes	111

	<u>Page</u>
<u>THE ALLERGIC INFLAMMATORY LESION</u>	117
PLATELET AGGLUTINATION	118
PMN RESPONSE.	120
THE ROLE OF POLYMORPHONUCLEAR LEUKOCYTES	123
<u>THE EFFECT OF TRAUMATIC INJURY ON THE ALLERGIC INFLAMMATORY REACTION</u>	126
SUMMARY AND CONCLUSIONS	135
APPENDIX	137
BIBLIOGRAPHY	138

TABLES

	<u>Page</u>
TABLE I	PRIMARY SEROLOGICAL RESPONSE TO BSA 38
TABLE II	PREPLASMA CELL COUNTS IN PRIMARY BSA STIMULATED LYMPH NODES 50
TABLE III	PRIMARY SEROLOGICAL RESPONSE TO HORSE FERRITIN 53
TABLE IV	PREPLASMA CELL COUNTS IN PRIMARY HORSE FERRITIN STIMULATED LYMPH NODES 60
TABLE V	MAST CELL COUNTS 93
TABLE VI	TISSUE RESPONSE TO PRIMARY HORSE FERRITIN INJECTION (PRIM. H Fe). 94
TABLE VII	RESPONSE OF TRAUMATICALLY INFLAMED TISSUE TO PRIMARY HORSE FERRITIN INJECTION (INFL. + PRIM. H Fe) 96
TABLE VIII	TISSUE RESPONSE TO CHALLENGE INJECTION OF HORSE FERRITIN (CHALLENGE). 99
TABLE IX	RESPONSE OF TRAUMATICALLY INFLAMED TISSUE TO CHALLENGE HORSE FERRITIN INJECTION (INFL. + CHALLENGE). 104

FIGURES

	<u>Page</u>
Figure 1	Morphology of Preplasma Cells 34
Figure 2	Primary Serum Antibody Response to BSA . . . 39
Figure 3	Normal Cervical Lymph Node of the Mouse . . . 41
Figure 4	Early Lymph Node Changes Following BSA Stimulation 42
Figure 5	Late Lymph Node Changes Following BSA Stimulation 44
Figure 6	Histomorphology of the Normal Spleen of the Mouse 45
Figure 7	Changes in the Spleen Observed 4 Days Following BSA Stimulation 47
Figure 8	Changes in the Spleen Observed 10 Days Following BSA Stimulation 48
Figure 9	BSA Stimulated Animals: Preplasma Cell Counts per 1,000 Total Cells 51
Figure 10	Primary Serum Antibody Response to Horse Ferritin 54
Figure 11	Prussian blue Staining in Local Cervical Lymph Nodes of Horse Ferritin Injected Animals 56
Figure 12	Prussian blue Staining in the Normal Spleen of the Mouse 58
Figure 13	Prussian blue Staining Observed in the Spleen 1 Hour Following Horse Ferritin Injection 59
Figure 14	Horse Ferritin Stimulated Animals: Preplasma Cell Counts per 1,000 Cells 61
Figure 15	Animal Preparation 81
Figure 16	Correlation Between Fluorescence and Prussian blue Staining 115

	<u>Page</u>
Figure 17	Correlation of Fluorescence-Prussian blue in Challenged and Inflammation + Challenged Tissues 116
Figure 18	Mast Cell Response to Tissue Injury 119
Figure 19	PMN Response to Tissue Injury 121
Figure 20	Correlation Between Tissue Fluorescence and PMN Response 122
Figure 21	Correlation of PMN Response to Prussian blue Staining 124
Figure 22	Correlation of PMN Response and Mast Cell Degranulation (Non-Sensitized Tissues) 125
Figure 23	Correlation of PMN Response and Mast Cell Degranulation (Sensitized Tissues). 127
Figure 24	Correlation Between PMN-Fluorescence Response in Challenged and Inflamed + Challenged Tissues . . 129
Figure 25	Correlation Between PMN-Prussian blue Response in Challenged and Inflamed + Challenged Tissues . . 130
Figure 26	Correlation of PMN-Mast Cell Response in Challenged and Inflamed + Challenged Tissues. . . . 132
Figure 27	Schematic Representation of the Role of Immune Complexes in Allergic Inflammation. 133

ABSTRACT

The primary immune response of adult albino mice to bovine serum albumin antigen and horse ferritin antigen was studied from 1 through 28 days following primary antigen injection. The mandibular labial sulcus served as the injection site. The immune response reached peak 14 days after antigen injection, then returned to near normal by 28 days.

The local immune response to challenge antigen injection in sensitized mice was investigated. Challenge injection was administered through the maxillary labial mucosa.

The influence of non-specific inflammation on the challenge response was studied when both were present simultaneously in a local oral tissue site. The results indicate that inflamed tissues react more violently to the presence of horse ferritin-anti horse ferritin complexes than do non-inflamed tissues. Although the challenge reaction in non-inflamed tissues incited an acute inflammatory lesion, this same reaction occurring in inflamed tissue induced an Arthus reaction.

ACKNOWLEDGEMENTS

This thesis was prepared in the Department of Oral Pathology, Faculty of Dentistry, University of Manitoba. The author wishes to express his deep appreciation to Dr. J. R. Trott, my supervisor. Frequent consultation and instructive discussions with him provided valuable guidance throughout this study and in the preparation of the manuscript. Helpful comments from Drs. W. G. Young and W. L. Parker are also gratefully acknowledged.

Technical assistance from Mrs. Yien Pan and Miss Diana Dale, in preparing the histological material, was very much appreciated. University of Manitoba grants to Mr. Daniel Green, Mr. Harvey Kryger, and Mr. Martin Nevile provided assistance in much of the routine laboratory work.

Also acknowledged are the art and photographic assistance provided by Mr. Douglas Lane and Mr. Alex Domokos. I would like to thank Mrs. Barbara Tiller for the very able secretarial assistance throughout the preparation of this thesis.

Financial assistance from the National Research Council helped make possible this most enjoyable, rewarding and educational experience.

INTRODUCTION

The structures comprising the periodontium are subject to a great variety of diseases. The most prevalent and most damaging of these diseases, in terms of resultant premature loss of teeth, is chronic destructive periodontitis. Whenever the term "periodontal disease" is used in this thesis, unless otherwise specified, it is to be interpreted as the chronic inflammatory destructive form of periodontitis.

The nearly universal nature and the apparent complexity and inconclusiveness surrounding the etiology of periodontal disease justify the investigation of all possible factors that may contribute to the initiation and development of the disease. In recent years the possible role of the immune mechanism in periodontal disease has been frequently alluded to. Experimental investigation has accumulated evidence which supports this supposition.

Of the many causal factors relating to periodontal disease, the oral microbiota (as possible sources of antigens) and local tissue inflammation have been the two elements that have received continued and increased attention. It has not been determined how the indigenous oral population of bacteria relates to the local gingival inflammation which is apparently the forerunner of periodontal disease. It is equally uncertain how gingival inflammation, once present, progresses to destruction of bone and collagen. It was the intention of this thesis to introduce the concept of synergism between local inflammation and immune reactions, and to produce experimental evidence in support of such a concept. Such a synergistic mechanism, if it does in fact operate in mammalian tissues, may be a factor to be considered in the pathogenesis of periodontal disease.

PART I

PERIODONTAL DISEASE AND THE ROLE
OF IMMUNE MECHANISMS

RELEVANT CONCEPTS

A Literature Review

PERIODONTAL DISEASE

Recognition of periodontal disease as a widespread public health problem, with up to 95% of the population affected, has been well documented. The techniques for diagnosis and treatment have become sophisticated and highly effective. However there are such a variety of factors exerting their influence on the affected tissues that the pathogenesis and to a lesser degree the etiology of periodontal disease is obscure. The clinical handling of the disease remains empirical (Waerhaug, 1967).

It has become evident that the development of the periodontal lesion must be a convergent biological phenomenon in which a number of variable factors must co-exist in the immediate environment of the periodontal organ. These variable factors may be local, systemic, endogenous and/or exogenous. It must also be recognized that the products of interaction of these various factors may be many and varied; some of them possibly directly related to subsequent disease, some of them not. One must also assess the effect of the interaction product on the normal physiologic capacity of the tissues involved, especially in an organ that is submitted to mechanical forces of the magnitude occurring in the periodontal organ.

THE PERIODONTIUM

Sorrin (1960) defines the periodontium as all those tissues in immediate proximity to and surrounding the tooth. These include cementum, periodontal membrane, alveolar bone and gingiva. The peculiar nature of this organ suggests that the disease processes associated with it are either directly or indirectly related to some of the anatomical features

composing it. A brief summary of the more important anatomical structures and their possible relationship to disease is therefore included.

THE PERIODONTAL MEMBRANE

The structural component of the periodontal membrane is collagen fibres and a cementing ground substance. Chemically this tissue is made up of mucopolysaccharides composed of hyaluronic acid and chondroitin sulfuric acid forming complexes with protein. The proportional content of the two acids is important in the consideration of disease. Chondroitin sulfuric acid-protein complexes are relatively stable, whereas hyaluronic acid-protein complexes are more readily dissolved (Ehrich, 1952). In immature collagen the more soluble hyaluronic acid-protein complexes are present in greater proportion than the more insoluble complexes. This may be an important consideration in periodontitis, in which disaggregation of collagen occurs.

It is possible that inflammation associated with periodontal disease acts to block or alter the maturation process of newly synthesized collagen (Stirn, 1967). The periodontal membrane would then be gradually replaced by the more soluble immature collagen which would be more susceptible to disaggregation. Schultz-Hautt & Aas (1960) determined the amount of soluble and insoluble collagen in normal and inflamed gingival tissues and were unable to find significant differences.

THE EPITHELIAL ATTACHMENT

The junction of oral soft tissue and the hard tooth surface, the epithelial attachment area, may be the all-important gateway for disease producing substances from the oral cavity entering the periodontal tissues. The nature of the epithelial attachment has not been completely elucidated but most prominent today are two schools of thought. The static concept, supported by Gottlieb and Orban (1938), states that there is organic attachment of the invaginated epithelium to the tooth enamel. The dynamic concept states that the cells of the invaginated epithelium are "attached" only by adhesion to the enamel surface. Therefore the epithelial cuff is merely a tightly fitting cuff around the neck of the tooth (Waerhaug, 1966) leaving a space in the nature of 100-200 A^0 between the epithelium and the hard tissue of the tooth.

The oral epithelium is well protected against assault by its keratinized surface. The gingival crevice, which is probably subjected to more threatening agents than is most of the oral mucosa, is lined by a non-keratinized squamous epithelium.

Experimental investigation has determined that the cell-renewal rate in the epithelium of the gingival crevice and attachment area is relatively high. Trott & Gorenstein (1963) found that in rats the crevicular epithelium had a higher renewal rate than that of the attached or crestal gingiva, but not higher than the epithelium covering the palate and buccal mucosa. However epithelial cells of the gingival attachment had by far the highest rate of turnover. The significance of this latter finding is not entirely clear but does indicate that the epithelial attachment is a dynamic organ.

THE BLOOD SUPPLY

The blood supply to the periodontal membrane comes mainly from the dental artery which sends branches into the alveolus. The alveolar arteries in turn send branches laterally, perforating the lamina dura (Birn, 1966). Once having entered the periodontal membrane these branches anastomose with other arteries of similar origin to form a vascular plexus proximal to the alveolar wall. Carranza, et al (1966) have found that arterial branches from the dental artery also penetrate the periodontal membrane directly to form a plexus of vessels similar to the one just described, but proximal to the cemental side of the membrane.

The blood supply of the gingiva is largely independent of the periodontal blood supply and arises from mucosal vessels (Weinman, 1941; Carranza, et al, 1966; Kindlova, 1967). These investigators found that there are vascular connections between the gingival and periodontal tissues but suggest that these are of only minor importance. The lymphatic and venous drainage of both areas follows the arterial pathways.

Recently much attention has been directed to the blood supply of the crevicular epithelium and the dento-gingival junction (Carranza, 1966; Egelberg, 1966; Kindlova, 1967). From these investigations it has become fairly clear that a clinically healthy gingiva has a well defined vascular plexus underlying the crevicular epithelium. This plexus extends from the gingival margin to the base of the crevice and does not show vascular loop formation as is found under the oral epithelium of the gingiva.

In intimate relationship to the epithelial cuff is a vascular plexus which, similar to the plexus underlying the crevicular epithelium,

is rich in vessels of the venular type. Because the crevicular epithelium is relatively thin these venous networks are situated very proximal to the surface and thus both their position and physiological characteristics make them extremely vulnerable to injury.

In chronically inflamed gingiva the thin layer of blood vessels underlying the crevicular epithelium is replaced by a vascular bed rich in loop formations (Egelberg, 1966). The coiled vascular network under the epithelial attachment becomes grossly varicose and shows a pronounced inflammatory reaction. The anastomoses between gingival and periodontal vasculatures increase. Associated with these anatomical changes is an increased flow of tissue fluid through the gingival crevice (Egelberg, 1963). This finding is consistent with the known tendency for vessels of the venular type to respond to injury by increased permeability.

HOST-PARASITE RELATIONSHIPS

Bacteria and bacterial products appear to represent an indispensable factor in periodontal disease (Schultz-Haudt & Lundqvist, 1962; Gibbons, 1964; Mulvihill, et al, 1967; Winer, et al, 1967). Most, if not all, living things are infested with a variety of indigenous microbial agents which are at least potentially pathogenic.

At the same time the host defence mechanism is of such a nature that it is able to maintain a healthy state even in the presence of potentially harmful agents. The presence of these microorganisms normally becomes manifest only when something occurs to upset this equilibrium between parasite population and/or pathogenicity and host defences (Schultz-Haudt & Lundqvist, 1962). Any factor, local or systemic, exogenous or endogenous, which operates to tip this balance in favor of the parasite must then be considered etiologic in the resulting disease state.

FACTORS OPERATING AGAINST THE HOST

The Parasite: It has not been demonstrated that a qualitative difference in oral flora exists in healthy and diseased individuals (Ellison & Mandell, 1963; Courant, et al, 1965). Bacteria or bacterial exotoxins have not been discovered in the tissues relating to periodontal disease (Bibby, 1953). However change in relative or absolute numbers of organisms do exist between individuals with healthy and diseased periodontal structures (Roseburg, et al, 1950; Gibbons, 1964). This would indicate that a mere increase in the population of oral microflora is enough to upset the delicate equilibrium between parasite and host. There are many known factors, some of which will be discussed presently, which readily contribute to such quantitative changes.

It has been demonstrated that certain of the indigenous oral microbes are capable of elaborating proteolytic enzymes capable of disrupting gingival tissue and disintegrating collagen (Waerhaug, 1966; Cobb & Brown, 1967). Lucas and Thonard (1955) cultured bacteria from healthy and diseased gingiva and demonstrated that bacteria from diseased pockets were capable of disintegrating collagen. McDonald and Gibbons (1962) tested some of the individual species of oral microorganisms and found that out of those tested only *B. Melaninogenicum* was capable of liquifying gelatin or hydrolysing collagen. Schultz-Haudt and Scherp (1955) found that individual strains of bacteria do not lyse collagen, but that a broth made from a sample of oral microbes collected from diseased tissue did. They suggested that the lytic process may require a synergistic action of enzymes from several kinds of microorganisms.

Whether or by what method these bacterial products actually enter the periodontal tissues has not been specifically determined. If bacteria or their products are able to penetrate the tissue barrier and gain access to the underlying tissues it is conceivable that these lytic properties of oral bacteria could give rise to periodontal disease.

Triftshauser, et al (1966) and Bennick & Hunt (1967), theorized that it was equally possible that inflamed tissue itself may possess collagenolytic activity. Inflamed live human gingival tissues were tested for collagenolytic activity against reconstituted guinea pig skin collagen. Bennick & Hunt incubated the two tissues in a multi-antibiotic culture broth to insure sterility. The findings were that inflamed human gingival tissue contained factors that were able to lyse the reconstituted guinea pig collagen.

The question that arises is whether these authors were actually measuring natural tissue collagenase, or whether bacterial collagenase was present in the inflamed gingival tissue. Separation of the two types of collagenolytic factors would presumably be a difficult task.

Another potentially harmful bacterial factor may be the variety of bacterial antigens continuously in contact with gingival tissues (Rizzo and Mergenhagen, 1965). Strong circumstantial evidence and increasing experimental evidence supports the theory that local hypersensitivity mechanisms may be operating to upset the host-parasite equilibrium in favor of the parasite. This will be dealt with in greater detail later.

Local Irritants: Calculus is a contributing factor in the development of periodontal disease because it acts as a mechanical irritant and allows accumulation of bacterial and chemical irritants in high concentrations

(Ramfjord, 1952; Leung, 1962).

Rovin, et al (1966) used germ free rats to demonstrate that neither calculus nor microorganisms alone could initiate inflammatory periodontal disease, but that together they were effective in producing inflammation. Though dental calculus can form in germ free rats, the presence of microorganisms greatly facilitates the formation of calculus. These authors concluded that the presence of both local irritation and microorganisms was necessary to produce periodontal inflammation. It is not illogical to reason then that any factor that acts as an irritant to the gingival tissues enhances calculus formation, which in turn leads to high local concentrations of microorganisms. These increased populations of microflora are related to periodontal disease.

Systemic Factors: McDonald and Gibbons (1962) stated that while the periodontal membrane can reflect the impact of any or all systemic diseases, it is not possible to attribute periodontal disease to any known systemic factor. Karshan (1952) carried out a wide variety of tests and found no specific systemic factor that significantly contributed to periodontal disease. It is however conceded that systemic factors can so weaken the normal host defence mechanisms that a normally harmless oral situation can begin to manifest its previous potential pathogenicity (Kerr, 1962; Shaw, 1962; Brandzaeg, 1966; Waerhaug, 1966). Genetic and familial factors may also contribute to an unusual state of susceptibility to factors which are normally harmless (Baer & Leberman, 1960; Baer & Newton, 1960; Gorlin, et al, 1967).

FACTORS OPERATING IN DEFENCE OF THE HOST

Local Factors: The gingival epithelium is relatively thick and keratinized and thus presents an effective mechanical barrier to the entrance of bacteria and their products. The crevicular epithelium is thin and non keratinized, forming a rather weak barrier to invasion and injury (Egelberg, 1963). This area of vulnerability is probably protected by secondary lines of defence; namely, the increased cell renewal rate in this tissue (Beagrie and Skougaard, 1962; Trott & Gorenstein, 1963; Schultz-Haudt, 1964) and the cleansing effect of the crevicular tissue fluid (Brill and Bjorn, 1959; Brill, 1959). This tissue fluid contains fibrinolytic enzymes and such non-specific antibacterial agents as properdin and lysozyme which enhance its defence capacity (Brandzaeg & Mann, 1964; Waerhaug, 1966). Brill (1962) has shown by an immuno-electrophoretic method that globulin fractions, including β and γ globulins, are also present in gingival crevice fluid.

The epithelial attachment, as described by Waerhaug (1966), is dependent on normal serum proteins for its adhesiveness to tooth structure. This adhesive property is in constant danger of being destroyed by certain proteolytic enzymes being elaborated in close proximity to the attachment area (Schultz-Haudt, et al, 1963). The direction of flow of the crevicular tissue fluid therefore, as well as its chemical and biologic properties, constitute a host defence mechanism. It serves both to replenish the serum proteins necessary for maintenance of the normal physiology of the attachment and to wash harmful proteolytic enzymes orally. Antibodies against oral bacteria is a constituent of the crevicular fluid and further enhances its defence effectiveness (Brill and Brønneam, 1960).

Polymorphonuclear leukocytes are found associated with diseased periodontal tissues. They contribute to host defence by their phagocytic function (Schultz-Haudt and Lundqvist, 1962).

The lysozyme in saliva catalyzes the breakdown of certain polysaccharide constituents of bacterial cell walls (Brandtzaeg & Mann, 1964; Taichman, et al, 1966). Specific antibody to oral bacteria have also been found in measurable amounts in the saliva (Wheatcroft, 1957; Ellison, 1962).

General Factors: The typically slow progress of periodontal disease indicates that a continuous limiting influence is operating on the disease producing factors. This limiting factor is probably attributable to the two central resistance mechanisms; inflammation and immunity (Schultz-Haudt and Lundqvist, 1962).

Histological observations have shown that the inflammatory reaction in periodontal disease consists mainly of lymphocytes and plasma cells (Burnett and Scherp, 1962). These cells have been incontrovertably associated with the production of antibodies (Nossal, et al, 1964). Their invariable presence in periodontal disease lends credence to the postulate that the immune mechanism may play a major role in host defences against threat of tissue invasion by oral bacteria or their products.

Orban (1940) observed that eosinophils were also included in the inflammatory cell population in gingival disease. These have since been directly related to immune reactions. Litt (1964) observed that they were especially attracted to immune complexes and performed a phagocytic function on these complexes.

Brandtzaeg and Kraus (1965) have by the direct immunofluorescent technique identified the three immunoglobulins in the gingival tissues, and Schneider, et al (1966) determined that at least some of these globulins were specific antibodies to the microflora of the gingival crevice. Mergenhagen and DeAraujo (1965) tested human sera for specific antibody to *Leptotrichia Buccalis*, a gram negative bacterium indigenous to the human oral cavity. Their tests proved to be positive. Studies by Mergenhagen, Zipkin & Varah (1962) indicate that oral *Veillonella* also have demonstrable antigenic properties, although less specific. These findings prove that in humans immunological responses to indigenous oral microorganisms can develop.

The host-parasite relationship must thus be seen as a continuous struggle between the parasite which seeks to invade the host tissue and the host which seeks to prevent this invasion. The almost universal presence of inflammation in gingival tissues is mute evidence to such a struggle.

Taichman, et al (1966) raised the question whether this inflammatory response, while being beneficial to the well being of the host as a whole, may not have deleterious effects on the periodontal structures. Chapman and Goodell (1964) suggest that when functions which are usually phasic become continuous, the tissues involved may be pressed beyond their limits and mechanisms that normally serve to protect and restore the body now lead to disease. Periodontal disease then may be, at least in part, the result of noxious agents originating from both the parasite and the host.

INFLAMMATION AND TISSUE INJURY

Whether inflammation has a cause or effect relationship to periodontal disease is difficult to assess. It is conceivable that it is an

early link in a chain reaction in which multiple agents are released or activated at different stages. The final pathologic condition would be determined by the substances produced in the course of the reaction, and to what stage the reaction had progressed (Antopol and Chrysanthan, 1964). This chain reaction could be triggered by a great variety of factors which could then be considered etiologic for the resulting disease.

INFLAMMATION

The reaction of living tissue to injury in vertebrate animals is inflammation. Regardless of the type of injury, this response follows a regular pattern composed of two distinct phases (Schultz-Haudt and Solna, 1966).

The first phase is vascular in nature and involves dilatation of small blood vessels, especially those of the venular type, and increased permeability of the vessel walls. This gives rise to the inflammatory exudate. The second phase begins with the emigration of leukocytes from the blood stream into the injured tissue area. The course of the inflammatory reaction and the degree of tissue destruction resulting before healing takes place will depend upon the intensity, type and duration of injury. Many systemic factors may also influence the reaction.

Inflammation is not a direct result of injury, rather it is initiated and mediated by certain biologically active substances released into the tissues as a consequence of injury. Intimately related to these mediators are the mast cells, platelets, neutrophilic polymorphonuclear leukocytes and certain plasma constituents (Schultz-Haudt and Solna, 1966). The invariable consequence of the presence of these mediators in abnormal amounts is vascular damage resulting in tissue injury due to inadequate nutrition and altered metabolism (Stetson and Good, 1951).

Jancso (1961) found evidence to suggest that the mediators do not exert their effect by a simple direct action on the vascular wall. Experimental studies revealed that some kind of clotting process is involved in the mechanism of inflammation. Fibrinogen in the injured vessels appeared to be converted to fibrin, which in turn precipitated on the surface of the injured vessel wall. When certain anticoagulents were administered, or if the animal was defibrinated prior to application of phlogistic agents, thrombosis of vessels and concomitant edematous swelling and necrosis of tissue did not occur. The hyperaemic response was not affected. This would support the theory that tissue injury associated with inflammation is a direct result of interference with the normal perfusion of these tissues.

HYPERSENSITIVITY REACTIONS *

The immune reaction, as one of the systemic host resistance mechanisms, is directed at ridding the system of a potentially harmful foreign substance. It involves combination of antibody with the foreign substance (antigen) in an attempt to neutralize this substance and facilitate its removal by phagocytosis.

However in certain instances this beneficial effect is minor when compared with the harmful side effects which this union of antigen and antibody produces in host tissues. When the immune reaction is such that the harmful side effects predominate it is termed a hypersensitivity reaction.

Hypersensitivity reactions have been generally classified into Immediate-Type Hypersensitivity Reactions (I.T.H.) and Delayed-Type Hypersensitivity Reactions (D.T.H.). The two types are characterized by

* This discussion is based on information of a general nature as reported by the following authors: Stetson, 1951; Spouge & Cutler, 1963; Carpenter, 1965.

a number of distinguishing factors only several of which bear on this discussion.

I.T.H. occurs as a result of in-vivo union of antigen with humoral antibody, the site of union usually being in the lumina or walls of the smaller blood vessels. All of the usual protein and carbohydrate antigens are effective in inducing or inciting the reaction. Depending on the dosage and injection scheme followed, I.T.H. can be subdivided into local or systemic anaphylaxis which occur only in the presence of high serum antibody titre.

The Arthus reaction is a local hemorrhagic inflammatory reaction resulting from antigen-antibody union occurring in tissues and in the walls and lumina of small blood vessels. Thrombosis may be so extensive that tissue necrosis will become manifest clinically as an Arthus lesion.

Other local anaphylactic reactions are manifested by such symptoms as asthma, hay fever, eczema, etc. Because atopic reactions are associated with reagins and believed to occur only in man, there is some hesitation about including them under the I.T.H. reactions.

I.T.H. reactions develop rapidly and reach their height within approximately five hours. Microscopically the reaction is similar to an acute inflammatory reaction with neutrophilic polymorphonuclear leukocytes predominating. The reaction is mediated by chemical mediators, histamine probably playing the most essential role. If the lesion is sub-macroscopic the acute inflammatory stage will pass through the subacute phase to eventual healing without becoming clinically manifest.

Delayed-type hypersensitivity is an immunologically specific inflammatory reaction occurring in the absence of demonstrable antibody. It is often referred to as "allergy of infection", the most thoroughly

studied example involving the tuberculosis organism or some of its products. D.T.H. can also be induced by many other kinds of bacteria, viruses, or fungi provided that proper methods are followed for its induction.

The clinically detectable D.T.H. reaction takes from 24 to 48 hours to develop, manifesting as an area of induration which may go on to surface necrosis and ulceration.

Microscopically the early lesion shows perivascular infiltration of mononuclear cells, and dilatation of blood vessels with increased permeability. Polymorphonuclear cells are conspicuously absent. Chemical mediators do not appear to play a role in D.T.H.

Although humoral antibody is not associated with D.T.H. reaction, the antigen used to incite the reaction may in a later stage induce antibody production which will manifest as humoral antibody. Following this occurrence the antigenic material which previously incited D.T.H. would, upon reinjection, produce an I.T.H. reaction.

The Schwartzman phenomenon is a pseudo-immunological reaction that does not belong in either the I.T.H. or the D.T.H. classification. It is best demonstrated in rabbits by injecting bacterial cultures or endotoxic filtrates intracutaneously under specified conditions. A secondary intravenous dose of similar but not necessarily identical material 24 hours later provokes violent hemorrhagic necrosis at the cutaneous site. Histologically this reaction is very similar to the Arthus reaction (Stetson, 1951).

IMMUNE REACTIONS AND PERIODONTAL DISEASE

That in-vivo antigen-antibody reactions can and do incite disease has been well documented (Stetson, 1951; Cochrane & Weigle, 1958; Uriuhara and Movat, 1964; Taichman, et al, 1966). Inflammation, with its concomitant blood vascular changes, has been generally accepted as an integral part in the pathogenesis of such disease processes.

If the implications of these generalizations are applied to the environment of the periodontal structures it is logical to hypothesize that the host-parasite interaction may be at least in part an immunological inflammatory reaction, and is thus another link in the chain reaction of events earlier mentioned. Results of laboratory investigation have supported this supposition.

HOST RESPONSE (IMMUNOLOGICAL) TO INDIGENOUS ORAL FLORA

Although bacteria or their exotoxins have not been demonstrated within the gingival tissue, their removal from contact with inflamed gingiva results in a favorable tissue response. This would suggest that bacterial breakdown products may have constituents that are harmful to oral mucosa when in contact with it. Bibby, (1953) prepared a filtrate from bacterial debris removed from inflamed gingival areas and then injected a sample of this filtrate into the arm of the donor patient. In one of the three tests carried out the patient reacted with a violent inflammatory response at the site of injection, characteristic of the D.T.H. reaction. Schneider, et al (1966) labelled immune globulins in inflamed gingival tissue and then subjected these tissues to bacterial antigens from the oral cavity of the same patient. They found that these antigens were attracted to the antibodies in the gingival tissue. Also, this attraction appeared to be specific.

Thonard and Dalbow (1965), recognizing that gingival tissue contains specific antibodies, investigated their source. Employing Jerne's plaque technique they were able to demonstrate that the specific antibody which accumulates in gingival tissue when suitably stimulated antigenically is at least in part formed within this tissue.

HYPERSENSITIVITY REACTIONS IN ORAL TISSUES

Experimental work on laboratory animals has been undertaken to determine how hypersensitivity reactions might be operative in the local site of the periodontium.

Mergenhagen and Rizzo (1961) investigated the possibility of inducing I.T.H. and D.T.H. reactions in oral mucosa. Rabbits were sensitized to either horse serum or tubercle bacillin by extra-oral injection. The challenge dose, administered in the oral mucosa, produced a characteristic I.T.H. reaction in the case of the horse serum, and a characteristic D.T.H. reaction in the tubercle bacillin sensitized animals.

Spouge and Cutler (1963) compared the relative ease with which these hypersensitivity reactions could be elicited in the skin and oral mucous membrane of the rabbit. Using horse serum as antigen they found that both sites were equally effective as sensitizing sites but that large challenge doses were needed to produce a macroscopic reaction in the mucosa. Lesions of the D.T.H. reaction, using *Mycobacterium Tuberculosis* in Freund's adjuvant, were produced with equal facility in both skin and mucous membranes.

These findings were borne out by Rizzo and Mergenhagen (1965), who extended their observation of similar lesions in oral mucosa of rabbits over a longer time period. Comparing their histological findings of a 5-day old immunologically induced inflammatory lesion with human

gingival tissue, they made the comment that the immunologically induced lesion seemed quite similar to the plasma cell reactions observed in spontaneous cases of human gingivitis. These findings point to the possibility that the well-recognized plasma cell component of human gingivitis may be induced by indigenous oral bacterial antigens acting in the gingival tissues.

Turner (1965) investigated the comparative susceptibility of some oral tissues to the I.T.H. reaction. Using rabbits, guinea pigs and rats he found that the tongue, the attached gingiva and the oral mucosa developed reactive lesions in descending order of severity. As a result of his experimental work he justifies the assumption that local allergic manifestations may be of importance in the pathology of the human mouth.

Attempts have been made to initiate immunologically induced periodontal lesions. Julian (1957) sensitized rats to an antigen and then gave a challenging injection of homologous antigen in the sublingual mucosa and the vestibular mucosa. After two months he was able to observe pronounced decomposition of alveolar bone. Rizzo and Mitchell (1966) repeatedly placed antigen-impregnated packs in the gingival pockets of rabbits, and were thus able to induce a chronic mononuclear inflammation and a measurable specific serum antibody titre.

Experimental periodontitis was induced in germfree and conventional rats by Platt, Crosby & Dalbow (1967). Daily intragingival injection of bovine serum albumin over an extended period resulted in periodontitis simplex which closely resembled histologically human periodontitis. When a synthetic glycoprotein containing BSA was similarly injected, or when physiologic saline was injected no such response was elicited.

Beutner, et al (1966) injected a challenge dose of antigen in incomplete adjuvant into the labial gingival sulci of guinea pigs. The result was increased mobility of the teeth in the area of injection, mononuclear inflammation of the gingiva and histological evidence of osteoclastic activity. Unsensitized control animals showed a much milder or a negative response.

AUTOIMMUNITY AND PERIODONTAL DISEASE

It has been theorized that bacterial enzymes and toxins elaborated in the gingival area may cause local modification of self components and that these modified components would induce antibody formation. These antibodies would react not only with the modified tissue components but with unmodified self constituents as well (Brandtzaeg and Kraus, 1965). Wakesman (1960) found that known antoallergic lesions occur only where a rich venule concentration is present. The gingival epithelium would thus be anatomically susceptible to the occurrence of such lesions.

Novotny, et al (1950) investigated the presence of autoantibodies in the serum and periodontal tissues of periodontally diseased individuals. They found what they termed conclusive evidence for the presence of such antibodies. These antibodies reacted not only with extracts of autologous diseased tissue, but also with extracts from gingiva of healthy individuals.

These findings however were not supported by the work of Brandzaeg and Kraus (1965). They tested the sera of 76 patients with periodontal disease for the presence of antibodies to their gingival tissue and found no definite evidence for their presence. Although immune globulins were found present in these tissues, Brandzaeg and Kraus suggested that products of gingival bacteria, rather than autoantigens, may be the inducers of these antibodies.

SUMMARY

The unique anatomical nature of structures comprising the periodontium and the variety of factors in the immediate vicinity threatening the integrity of these structures demands that periodontal disease be defined in terms of the total environment in which this disease process operates.

The defence mechanism protecting the vulnerable gingival crevice would appear adequate under "normal" conditions. However if environmental conditions become such that the bacterial population is allowed to increase and the assault by injurious agents becomes pronounced and continuous, a "hole" in the defence mechanism may develop, tipping the balance in favour of the parasite. It seems also that when the demands on certain homeostatic mechanisms exceed a certain limit these mechanisms, as a quirk of nature, inadvertently bring about destruction of the very tissues they seek to protect.

Two such mechanisms which would appear to be operating in defence of the periodontium are the inflammatory reaction and the immune mechanism. Because of the concentration of vessels of the venular type proximal to the gingival surfaces this tissue is highly susceptible to injury. This accounts for the prevalence of inflammation in this area, even in clinically "healthy" mouths.

Experimental evidence favors the occurrence of immune activity in these same tissues.

Incontrovertible proof that immune reactions are in fact part of the active homeostatic mechanism in the periodontal structures is not at the same time evidence that this reaction is pathogenic. These reactions are normally successful in restoring and maintaining homeostasis.

However several possibilities can be considered whereby a normal defence reaction can become destructive:

1. The fact that immune reactions sometimes lead to host injury (allergic reactions) is evidence that the immune mechanism, as a host defence reaction, is a general rather than a specific reaction. The system can therefore not distinguish pathogenic from non-pathogenic antigens. It responds indiscriminately and to the best of its fairly limited abilities to both (Silverstein & Prendergast, 1963). Therefore in some individuals some indigenous oral bacterial antigens may give rise to an allergic reaction rather than an immune reaction. The determining factor in such a case would be the antigen.

2. The presence of non-specific inflammation in the gingival tissues is characterized by a vericose venular plexus in juxta position to the crevicular epithelium and the attachment area. Increased anastomoses between the gingival and periodontal vasculatures would establish a pathway for the spread of inflammation in an apical direction. Immune reactions superimposed on such an environment may be enhanced, resulting in a destructive allergic reaction rather than in healing. In this system the environment, rather than the antigen, determines the reaction.

PART II

THE PRIMARY IMMUNE RESPONSE OF MICE TO HORSE FERRITIN
AND BOVINE SERUM ALBUMIN ANTIGENS

OBJECTS OF THE INVESTIGATION

It was necessary to establish a suitable model for the study of immune reactions in oral tissues. The mouse was chosen as the experimental animal because of its ready availability in large numbers and its comparative high resistance to immediate-type hypersensitivity reactions (Freund and Stone, 1956). Both sexes respond similarly to stimulation with antigenic materials (Havas & Andre, 1955) allowing use of male and female animals indiscriminantly.

It was the intention of the investigation to observe and compare the primary immune response of mice to bovine serum albumin antigen and horse ferritin antigen. The parameters of the response to be investigated were the humoral antibody response, changes in regional lymph node and spleen morphology, and the response of the sensitized animal to a challenge injection of homologous antigen during the period of peak antibody titre.

A further purpose was to evaluate the Perl's Prussian blue method as a means of tracing the presence of antigenic ferritin in injected tissues.

INTRODUCTION

Single injections of protein antigens are known to induce a fairly low-level serum antibody response in mice (Berlin, 1966; Olson & Wostman, 1966). Use of adjuvants will enhance the antigenicity of these antigens (Havas & Andre, 1955) but because of the phlogistic properties of adjuvants their use in this study was contraindicated.

Bovine serum albumin, with a molecular weight of approximately 160,000 has been used as an effective antigen in a great variety of animals including mice. Horse ferritin is a less popular antigen but has been demonstrated antigenic in rabbits by Wellensiek & Coons (1964), in rats by Ada, et al (1964), and in a variety of animals by De Petris, et al (1963).

The ferritin molecule with a molecular weight of approximately 480,000, is composed of a central core of ferric-hydroxide-phosphate micelles enclosed by a protein shell (apo ferritin) which is the antigenic constituent (Wellensiek and Coons, 1964). Because of the ferric component in ferritin it gives a positive Prussian blue reaction which makes it possible to trace its presence in tissues (Gomori, 1936; Pearse, 1960; Culling, 1963). This property is of real advantage in studying immunologic inflammatory reactions induced by antigenic ferritin, as the Prussian blue reaction can be employed to indicate localization of ferritin in the inflammatory site.

If sensitization produces sufficiently high serum antibody titres in experimental animals, reinjection of homologous antigen may lead to systemic anaphylaxis and death, or it may give rise to severe local allergic lesions of the Arthus variety. Either of these reactions would make our model unsuitable as local factors influencing the intensity of the

reaction could not be readily evaluated. This made it necessary that antigen doses administered, both as primary dose and challenge dose, and that the timing of the challenge dose in relation to serum antibody titres be regulated to conform to this requirement.

MATERIALS & METHODS

Bovine serum albumin (BSA) fraction V powder, fatty acid poor, was obtained from Nutritional Biochemicals Corporation in Cleveland, Ohio. Twice crystallized horse ferritin (H Fe) (Not Cadmium Free) was purchased from the same corporation.

Sterile citrated sheep red blood cells, used in the hemagglutination tests, were obtained from the National Biological Laboratory, Winnipeg.

The albino mice used throughout this investigation were purchased from Canadian Breeding Laboratories, Montreal. They were 6 - 10 weeks old and weighed from 20 - 30 grams each. Females and males were used.

The animals were maintained in groups of six or less in wire cages under controlled environmental conditions. They had access to standard diet and water ad libitum.

SENSITIZATION OF ANIMALS

Investigation of the response of local lymph nodes to antigenic stimulation required that an appropriate oral injection site be chosen. The cervical lymph nodes are readily accessible in the mouse and by injection of india ink in the mandibular labial sulcus area it was established that the lymphatic drainage of this area is through these lymph nodes. The mandibular labial sulcus was therefore chosen as the injection site.

The primary immunologic response of mice to 0.05 ml. 20% BSA (10 mgm.) was determined at 1 to 8, 10, 12, 13, 14, 16, 18, 22 and 28 days following injection. Similarly, the primary response of mice to 0.05 ml. 10% H Fe (5 mg.) was determined at 1, 4, 12 hours and 2, 4, 6, 8, 10, 12, 14, 16, 18, 21, 24 and 28 days following injection. The parameters of

the primary response evaluation included serological assay for anti-BSA or anti-H Fe titre, histological examination of the cervical lymph nodes and spleen, and preplasma cell counts from smears made of cervical lymph node contents.

Three animals in each of the BSA and H Fe groups were prepared by injection of the appropriate antigen under ether anaesthesia. A control animal was added to each group; the control animal received an injection of 0.05 ml. sterile physiological saline in the mandibular labial sulcus at the same time the antigen injections were administered. More antigen injected animals were later added to several groups in the critical areas in order to double-check initial results.

SERUM PREPARATION AND ANTIBODY ASSAY

Three hours prior to sacrifice the animals were starved in order to ensure a low serum lipid level. The animals were sacrificed by exsanguination under ether anaesthesia. Using a 2 ml. capacity B-D Yale glass syringe and a 25 gauge 5/8" sterile disposable needle between .75 ml. and 1.25 ml. of whole blood was obtained by cardiac puncture from each animal. These blood samples were placed immediately into individual 10 x 75 mm. glass test tubes, stoppered, labelled and stored in the refrigerator at 4-5° C.

The blood was left undisturbed in the refrigerator for 24 hours. By this time clot retraction was complete and the serum could be drawn from the clots with a disposable capillary pasteur pipette. These sera were centrifuged at 1750 rpm in a Fisher Model 970V2 centrifuge, drawn off as clear sera and stored in separate labelled test tubes at 4-5°C. Serum antibody titrations were done within 48 hours of animal sacrifice

in order to minimize possibility of bacterial contamination.

The methods available for serum antibody assay are many, and vary in sensitivity and methodological involvement. The present investigation found that the test tube precipitin reaction, the Ouchterlomy and Oakley-Preer Agar diffusion techniques (Kabat and Mayer, 1964), and the micro-double-diffusion technique (Johnson, et al, 1964), were not sensitive enough to measure the antibody response elicited in the animals in this investigation. It was found that the hemagglutination reaction as described by Stavitsky (1954) was reliably sensitive and relatively easy to perform. After slight modification (see Appendix "A"), it was used to assay the sera of all the animals used in this study for BSA or H Fe antibody titres.

The clear serum was removed from the refrigerator and diluted in pH 6.4 phosphate buffered normal saline (Stavitsky, 1954). The dilution factor was determined by the amount of serum sample needed for the particular test. It was usually between 2 and 6.

Triple washed packed sheep red blood cells, equal in volume to the undiluted serum, were added to the diluted serum to remove heterophile agglutinins. The cells and serum were well mixed, then incubated in a 35°C water bath for 30 minutes. After centrifugation the adsorbed serum was drawn from the red blood cells. It was next incubated in a water bath at 56°C for 30 minutes to inactivate the Complement factor. Thereafter 2-fold serial dilutions of serum in a volume of 0.25 ml. of 1:100 normal inactivated adsorbed horse serum in pH 6.4 phosphate buffered saline were prepared beginning with a 1:2 to 1:6 dilution. To these dilutions were added .025 ml. of a 2% solution of appropriately sensitized sheep red blood cells in pH 6.4 phosphate buffered saline. The mixtures were shaken

vigorously and then allowed to incubate undisturbed at room temperature for twelve hours. Positive or negative results were determined by the settling patterns of the red blood cells in the serum dilutions (Stavitsky, 1954). The end-point was read as the last tube to show definite agglutination of red blood cells. The results were recorded as \log_2 value of the reciprocal dilution at the end-point.

The sensitivity of the hemagglutination test requires that reliable controls be set up for each test. Sensitized red blood cells in normal serum dilutions served as one control. Another method of control was to add .025 ml. of tanned but unsensitized red blood cells to several tubes in the series of serum dilutions being tested. For this purpose the serum dilutions in tubes 1 and 2 were made identical. Control red cells were added to tubes 1, 5 and 10 in the dilution series.

As all of the sera were not tested with the same batch of sensitized cells, it was necessary to carry over at least one serum sample from one test to the next to ensure that one batch of sensitized sheep red blood cells had agglutinating properties similar to the other. When widely varying results were obtained on one serum sample, fresh cells were prepared and the test repeated.

TISSUE METHODOLOGY

The cervical lymph nodes were exposed by making a midline incision through the skin extending from the lower border of the sternum through the lower lip. The skin was freed from the underlying fascia and pinned back to expose the superficial cervical structures.

The lymph nodes were seen lying on either side in close relationship to the lateral border of the sterno-hyoid muscle and just covered by the mesial border of the parotid gland. Two and sometimes three lymph nodes could be removed from either side by dissecting them free from the overlying fascia with a small blunt instrument and lifting them out carefully with small finger-forceps. The lymph nodes thus obtained were divided into two equal groups; one group was placed into 10% neutral formalin for fixation; the other group was placed in several drops of fresh, cold normal saline in a watch glass for smearing (vide infra).

The abdominal cavity was entered for removal of a sample of the spleen. The distal 1/3 of the spleen was snipped off with a sharp scissors and added to the 10% neutral formalin solution containing the lymph nodes.

Following fixation these tissues were processed overnight in an Autotechnicon Model 2A. The tissues were then embedded in paraffin in preparation for cutting. Sections 5--7 microns in thickness were cut on a Spencer "820" microtome. Histological stains used were Hematoxylin and Eosin (H&E) for general histological examination and Prussian blue stain to determine presence of ferritin in these tissues.

The Perl's Prussian blue reaction (Culling, 1963) does not stain ferritin specifically. Staining depends on the production of ferric ferrocyanide when ferric ions (Fe^{+++}) in the tissues react with ferrocyanide in acid solution (Pearse, 1960).

Treatment with dilute acid liberates tissue ferric ion from unreactive loose combinations with protein. Thus Prussian blue positive reactions will occur in the presence of ferritin or hemosiderin. The iron in hemoglobin is more firmly bound and cannot be released by acid

treatment (Pearse, 1960).

The staining resulting from a positive Prussian blue reaction in tissues could therefore be indicative of the presence of natural ferritin or red blood cell breakdown products (hemosiderin). The lymph nodes and spleens of BSA stimulated animals were subjected to the Prussian blue stain in order to serve as controls on H Fe stimulated animal tissues.

The lymph nodes that had been placed into the fresh saline were immediately teased open with two sharp pointed instruments allowing the contents of the nodes to spill into the saline. The resulting suspension was taken up in a pasteur pipette and a drop placed on a glass slide that had been previously smeared with fresh normal mouse serum to aid cell adhesion to the slide. Smearing was accomplished by placing another serum coated slide against the suspension of lymph node cells, then quickly pulling the slides in opposite directions along their long axes. These slides were air dried, fixed, and stained with Giemsa stain (See Appendix "B").

Our histomorphological definition of preplasma cells accorded with Olson & Wostman's (1966) description of blast cells, plasmablasts and immature plasma cells. These cells have diameters greater than 10 microns, large eccentric nuclei with fine chromatin patterns, and cytoplasm which may be scanty and show pale blue staining, or bulky with deep blue staining, (Fig. 1). These cells are considered the forerunners of the antibody producing plasma cells (Fitch and Wissler, 1965). The presence of preplasma cells in lymph nodes could therefore serve as an indicator of antibody synthesizing activity.

33b

FIGURE 1

This figure represents three distinct cell types found in the lymph node smears. (a) A small lymphocyte (b) Immature plasma cell (c) Plasma blast. The cell types represented by b and c were considered preplasma cells. Giemsa stain. Original magnification 400X.

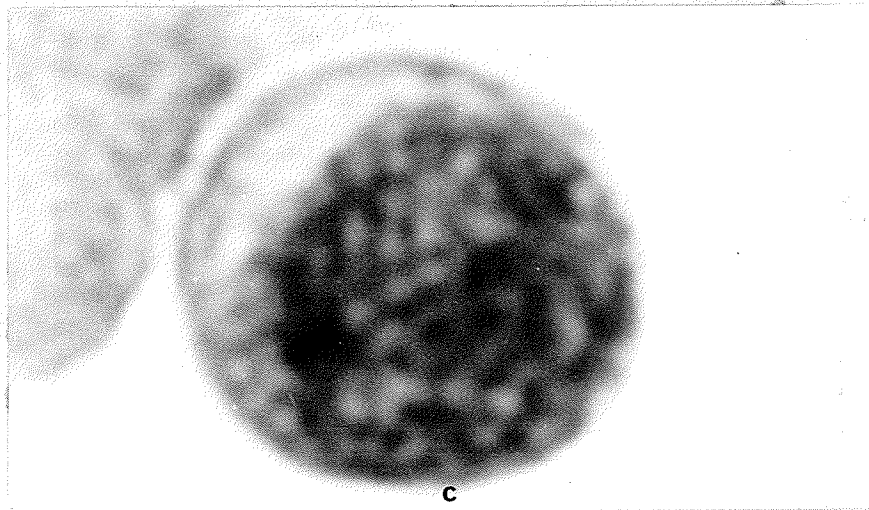
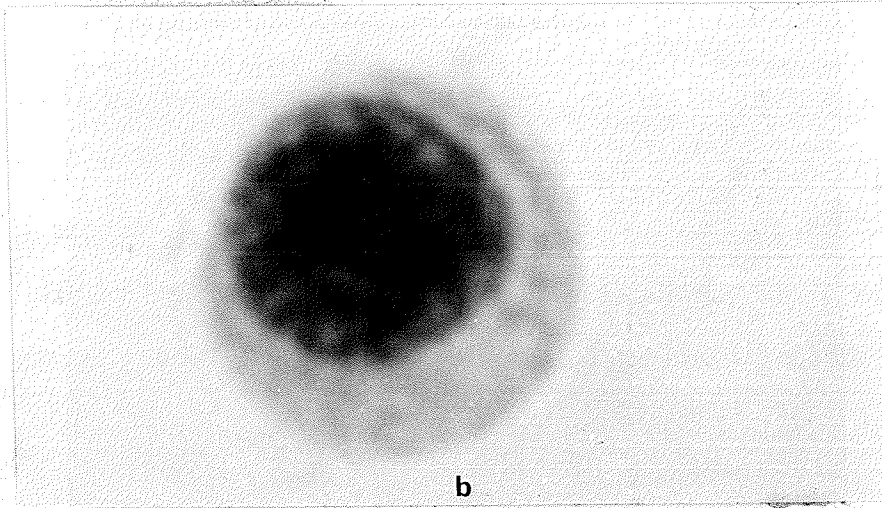
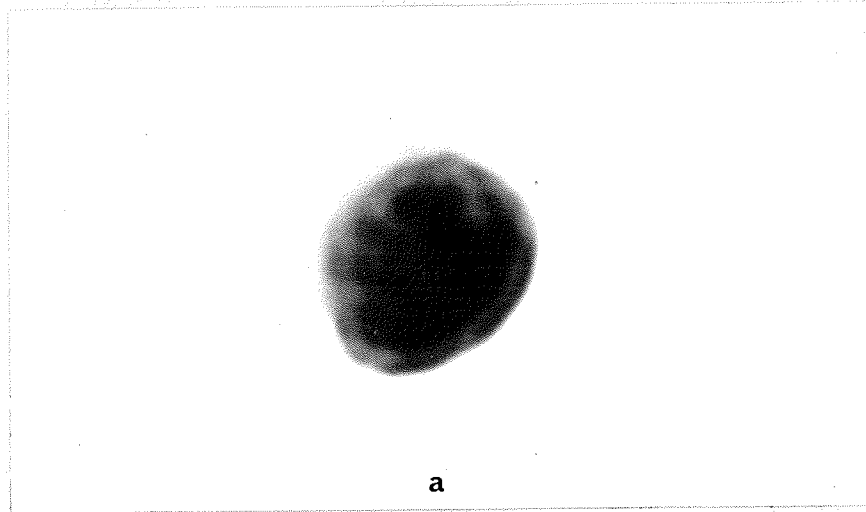


FIGURE I

Representative areas of the cell smears were counted under 400 magnifications to determine the number of preplasma cells present per 1,000 total cell count. The 1,000 cell count was repeated in four areas on each slide and the mean preplasma cell count per 1,000 cells per slide was determined and recorded.

REACTION TO CHALLENGE WITH HOMOLOGOUS ANTIGEN

In order to further evaluate the primary response of mice to the sensitizing dose of BSA and H Fe, a challenge dose of homologous antigen was administered by the same route at 7, 8, 10, 12, 13, 14 and 18 days following primary injection. Three mice in each of the seven groups were prepared with a primary injection of 0.05 ml 20% BSA in the mandibular labial sulcus, another three mice in each group were sensitized by a similar injection of 0.05 ml 10% H Fe. After appropriate time intervals the sensitized animals were challenged by injection of 0.05 ml 1% BSA or 0.05 ml 1% H Fe. Non-sensitized animals receiving a challenge dose served as controls.

Two hours following injection of the challenge dose the animals were killed by exsanguination. The whole blood was handled as previously described and assayed for hemagglutination titre. The cervical lymph nodes and a sample of spleen were removed, fixed in 10% neutral formalin, processed and embedded in paraffin, sectioned and stained with H&E and Prussian blue. Lymph node smears and cell counts were not done on these groups.

STATISTICAL METHODS

The results of the hemagglutination tests were recorded as Log_2 of the reciprocal titre of the serum dilution at end-point. The preplasma

cell counts per 1,000 total cells on lymph node smears were recorded as the mean of the four separate counts per slide.

The mean of the group values and the standard error of the mean was determined using accepted statistical methods.

RESULTS

PRIMARY RESPONSE OF BSA STIMULATED MICE

SEROLOGY

The serum antibody response of the mice to BSA, as assayed by the hemagglutination technique, is recorded in Table I. It can be observed that the initial serum antibody response was not detectable until the tenth day following primary injection of BSA and then only three out of ten animals had measurable antibody titres. On the twelfth day three out of four animals responded with measurable serum antibody titres, and from 13 to 18 days sera from all thirteen BSA injected animals gave a positive response. The 22nd and 28th day sera showed a trend towards rapidly decreasing antibody titres. All controls were negative.

Figure 2 is a graphic representation of the results in Table I. It is shown that the primary serum antibody titre rises sharply after 10 days to reach peak at 14 days. Serum antibody levels drop off fairly rapidly the first several days after reaching peak level, then decrease more gradually until at 28 days after primary injection the serum anti-BSA level has returned to near normal.

LYMPH NODE CHANGES

The diameter of normal cervical lymph nodes in the mice used in this investigation ranged from 1.5 mm. to 3 mm. The cervical lymph nodes of the saline injected control animals fell within the range of normality both in terms of gross morphology and histomorphology.

The lymph nodes draining the site of BSA injection became very much enlarged in the days following injection, some of them reaching a diameter up to 6mm. This enlargement was not uniform in all the cervical

TABLE I

This table shows the serum anti-BSA response, as measured by the hemagglutination technique, in mice from 1 to 28 days following primary injection of BSA.

TABLE I

PRIMARY SEROLOGICAL RESPONSE TO BSA

Days Post Inject.	Highest Serum Conc. Tested	Response - No. of Mice Log ₂ - Reciprocal Titre									Total No. of Animals Tested	Mean Titre	S.E.
		0	3.0	4.0	4.5	5.0	5.5	6.0	7.0	8.0			
1	1:3	2									2		
2	1:3	1									1		
3	1:3	2									2		
4	1:3	3									3		
5	1:3	3									3		
6	1:2	2									2		
7	1:2	3									3		
8	1:2	6									6		
10	1:2	7	2		1						10	1.1	0.6
12	1:2	1				1		1	1		4	4.5	1.6
13	1:2							1	1		2	6.5	0.5
14	1:4							1	2		3	6.7	0.3
16	1:2					1		3		1	5	6.2	0.5
18	1:4					3					3	5.0	0.0
22	1:4	1					2				3	3.7	1.8
23	1:4	2					1				3	1.8	1.8

FIGURE 2

Primary BSA stimulation gives rise to a rapidly developing serum anti-BSA fraction between 10 and 14 days following stimulation.

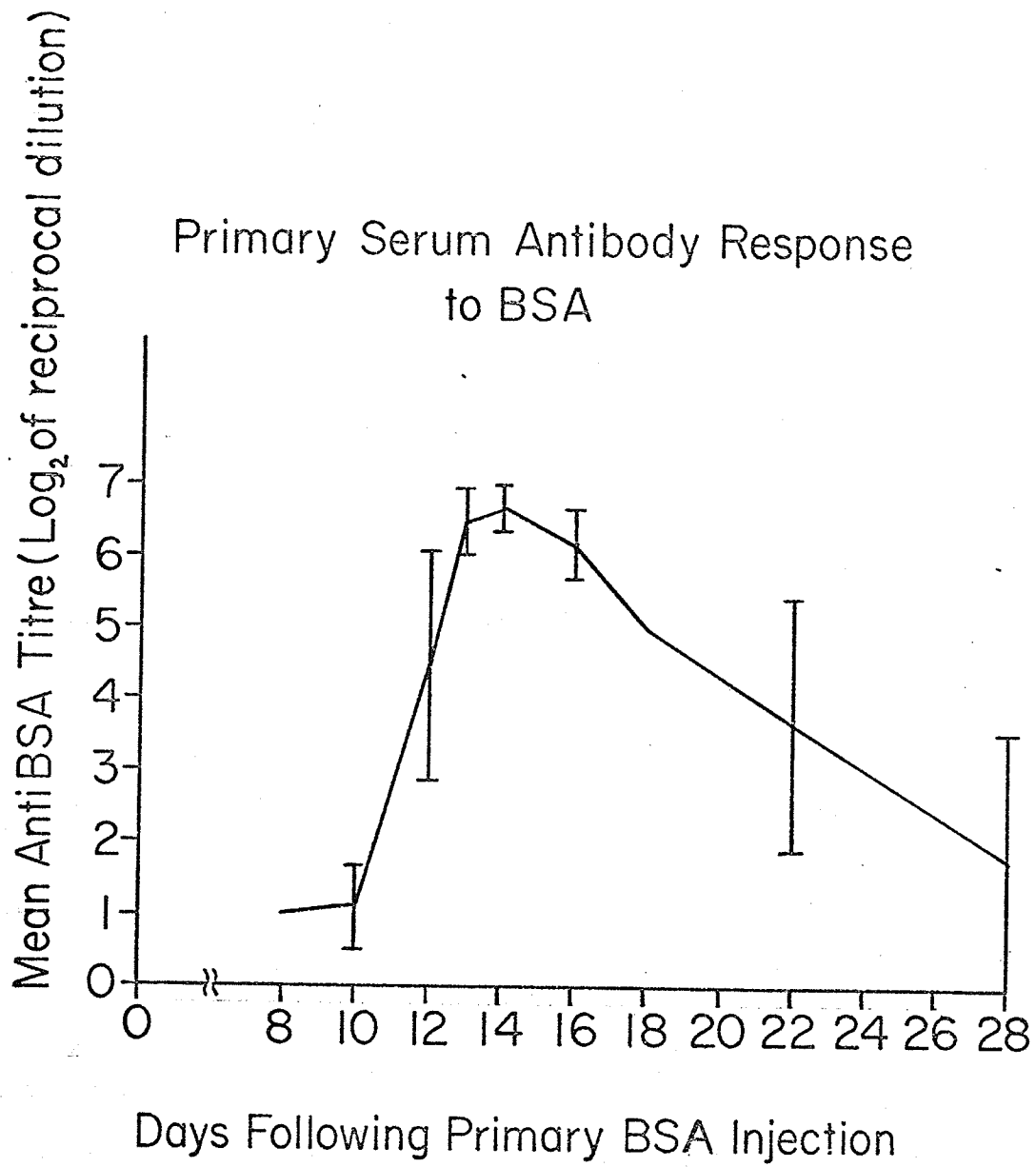


FIGURE 2

nodes of an animal. In some cases one or several would be very much enlarged, the others appearing almost normal.

Histological examination of the BSA stimulated lymph nodes was done not to determine cellular detail, but to observe general morphological changes. The cellular changes brought about in lymph nodes by antigenic stimulation have been described in detail by Humphrey and White (1964).

H&E Stain: The normal cervical lymph node of the albino mouse is a fairly structureless organ filled with a homogeneous mass of dark staining cells (Fig. 3). Although the cortex and medulla can be roughly distinguished, actual nodules and cords are ill-defined.

The early lymph nodes (1 day post-injection) were similar to the normal control both macroscopically and microscopically. By the second day however definite enlargement of the nodes was observed. The histomorphology was distinctive from the normal, with well-defined nodules with germinal centres appearing in the cortex (Fig. 4). This trend continued until by the fifth day the germinal centres had expanded so much that in some areas they appeared to coalesce to form a germinal band in the cortex. The medullary cords at this stage had become more distinct, being less densely packed with cells. Plasma cells were now abundant in the medullary sinuses.


Eight days after primary BSA injection the nodules again formed a more distinct pattern with large germinal centres surrounded by a narrow dense band of lymphocytes (Fig. 4). Secondary nodules appeared to encroach on the medullary area. The medullary sinuses had become packed with plasma cells. This picture remained fairly constant over the next eight to ten days.

FIGURE 3

This figure illustrates the histomorphology of a normal cervical lymph node. It appears as a fairly structureless mass with little evidence of follicles. H&E stain. Original magnification 10X.

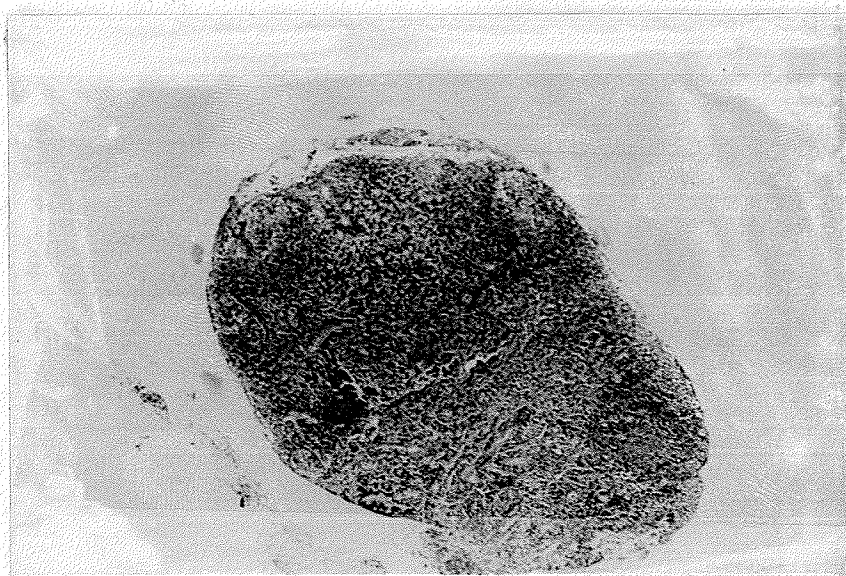

FIGURE 3






FIGURE 4

Illustrated are lymph node changes following BSA stimulation. Distinct germinal centres have developed (compare with Figure 3) (a) 4 days following stimulation (b) 10 days following stimulation. H&E stain. Original magnification 10X.

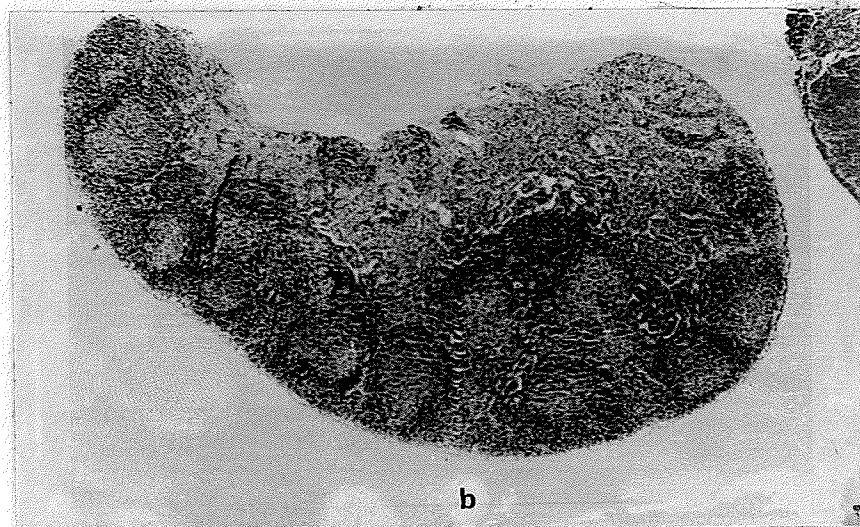
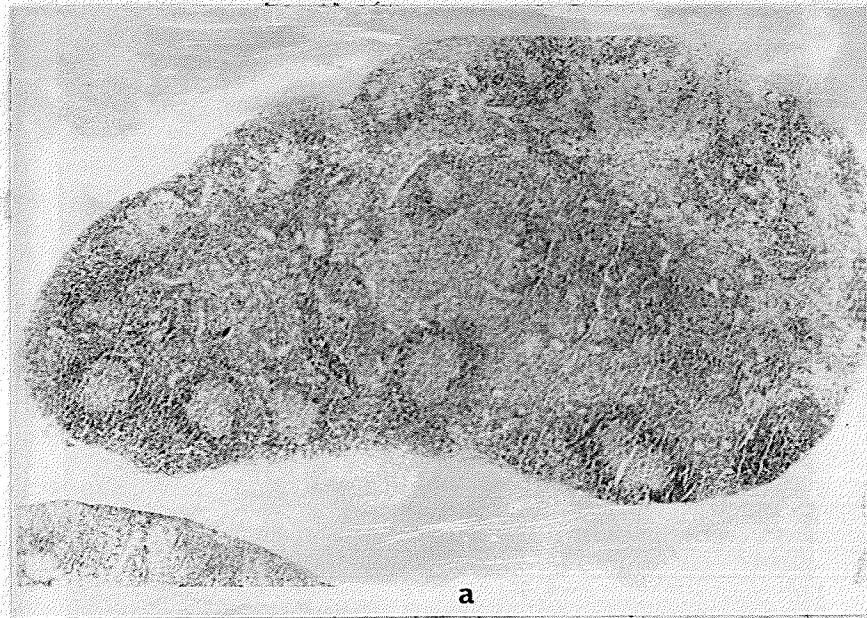

FIGURE 4

At eighteen days there was definite evidence that the germinal centres of the lymph nodules were diminishing in size, allowing a wider band of dense lymphocytes. The medullary sinuses were less densely packed, the predominant cells again being lymphocytes.

Twenty-eight days after primary injection of BSA the cortex of the lymph nodes had returned to the inconspicuous pattern of the normal node. The medullary area however showed excess stromal tissue giving it a "squeezed out" appearance (Fig. 5). Slight enlargement of the nodes was still evident.

Prussian blue Stain: None of the sections cut from the BSA stimulated lymph nodes showed evidence of positive Prussian blue reaction.

CHANGES OBSERVED IN THE SPLEEN

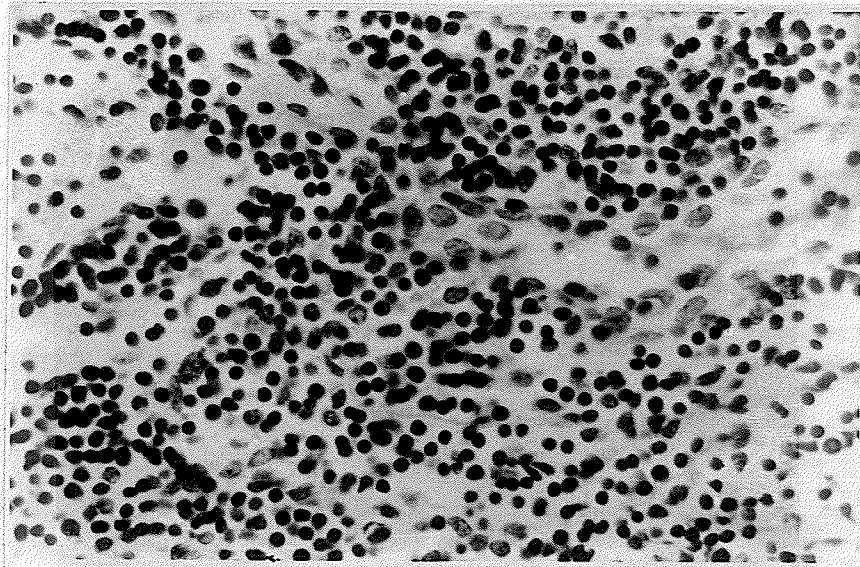
H&E Stain: The spleen sizes of normal and saline injected control animals varied so much that gross changes due to BSA stimulation could not be identified.

The sections of antigenically stimulated spleens were not examined for cellular detail but rather to observe the pattern of histomorphological change during the periods of antibody induction, production and decline following a single primary injection of BSA. The detailed cellular response of the spleen to antigenic stimulation has been reported by Fitch and Wissler (1965).

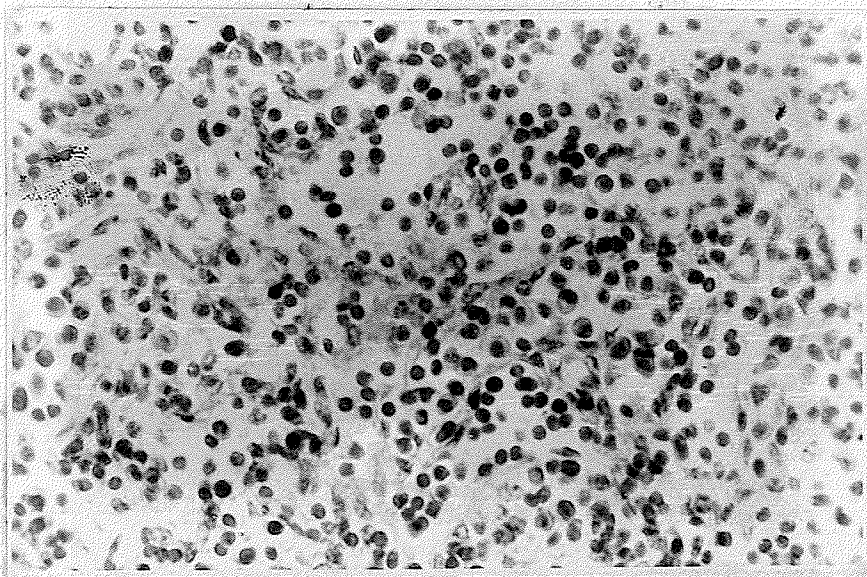
The normal mouse spleen is comprised of roughly equal portions of red pulp and white pulp (Fig. 6). The white pulp forms fairly well definable splenic nodules which are evenly packed with lymphocytes. In the red pulp some plasma cells can be observed but erythrocytes and lymphocytes

FIGURE 5

The medullary area of a BSA stimulated lymph node
(a) 14 days and (b) 28 days following stimulation. Excess
stromal tissue in the 28 days lymph node gives it a "squeezed
out" appearance. H&E stain. Original magnification 155X.



a



b

FIGURE 5

FIGURE 6

In the normal spleen the splenic nodules are seen as fairly well definable structures. H&E stain. Original magnification 10X.




FIGURE 6

form the bulk of the cellular elements. The spleens from saline-injected control animals showed no deviation from the normal.

Four days following primary BSA injection of animals the spleen appeared normal except that the centres of the splenic nodules had been taken up by paler and larger cells (Fig. 7). Some mitotic activity was recognizable in this area.

By ten days the splenic nodules had expanded to such an extent that the red pulp formed only a narrow trabecular network between the enlarged nodules (Fig. 8). The centres of these nodules had again become more densely packed, but this time with plasma cell types and large lymphocytes. After fourteen days the red pulp was almost unrecognizable because of the dense infiltration of lymphocytes into the pulp. This picture remained constant for several days.

A reversal of these changes was observable by 18 days when the red pulp was again more prominent. The splenic nodules were less densely packed, the centres consisting largely of immature pale cells. This trend towards a return to normal continued to 28 days when the white/red pulp ratio was almost normal and the splenic nodules were well-defined and homogeneous.

Prussian blue Stain: The Prussian blue reaction showed some degree of positive staining in most sections of spleen--control and BSA stimulated. In some sections staining was faint and localized, in other sections it was generalized and more intense. The normal presence of mouse ferritin in the spleen of the mouse would account for this observed positive Prussian blue reaction (Pearse, 1960).

FIGURE 7

Four days following BSA stimulation the splenic nodules are enlarged and more distinct. (Compare with Fig. 6). H&E stain. Original magnification 10X.

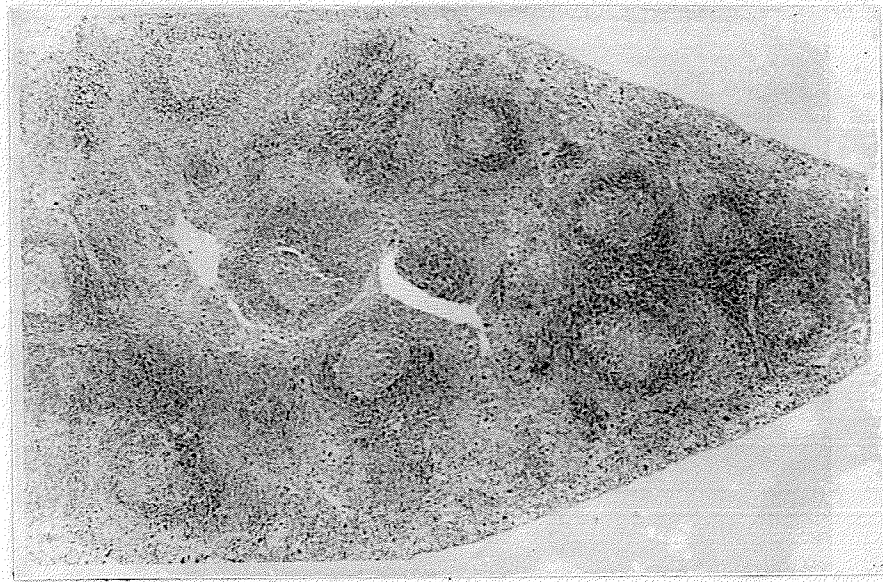


FIGURE 7




FIGURE 8

Greatly enlarged splenic nodules are apparent in the spleen 10 days following BSA stimulation. The red pulp is reduced to a narrow trabecular network. H&E stain. Original magnification 10X.

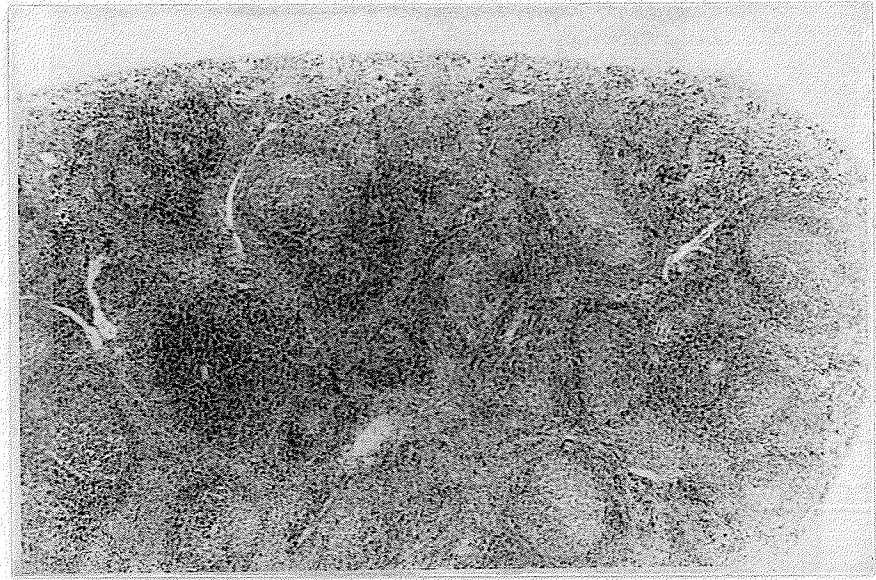


FIGURE 8

LYMPH NODE PREPLASMA CELL COUNTS

The results of the preplasma cell counts made from BSA - stimulated cervical lymph nodes are recorded in Table II and illustrated in Figure 9. The mean count per 1,000 total cells in the control lymph nodes was 4.9 cells. Two days following primary BSA stimulation the mean cell count had dropped slightly but rose to 10.8 preplasma cells per 1,000 cells by day seven. The count dropped down to normal by day ten, then rose steeply to peak at 41.1 preplasma cells/1,000 total cells at fourteen days. Having reached this peak the count again dropped rapidly to near normal by twenty-eight days.

REACTION TO CHALLENGE WITH BSA

The groups of animals receiving the challenge dose at 7, 8, and 10 days following the sensitizing dose showed lymph node and spleen changes similar to corresponding unchallenged sensitized groups. The hemagglutination test for serum antibody was negative.

In groups 12, 13, and 14, when challenged with an injection of BSA, many animals showed signs of distress within 15 minutes. These animals pawed their noses, showed bristling of fur on the back, and went into laboured respiration. Within 2 hours approximately 20% of the animals died.

Examination of the cervical lymph nodes and spleen of the 12, 13, 14 and 18 days animals showed the same features as observed in the corresponding non-challenged sensitized animals. The serum antibody titres in the challenged animals were slightly lower than the titre of the corresponding non-challenged groups. Adsorption of serum anti-BSA by the injected BSA would account for this slightly reduced titre.

TABLE II

The results of preplasma cell counts from smears of BSA stimulated lymph nodes from 2 to 28 days following primary antigen injection. Four counts per smear on three or four smears were done and the mean count and standard error calculated.

TABLE II
 PREPLASMA CELL COUNTS IN PRIMARY B.S.A.
 STIMULATED LYMPH NODES

Days After Stimulation	Preplasma Cells/1000 Total Cells-Smear No.				Mean Count	Standard Error of The Mean
	1	2	3	4		
2	8.9	1.5	1.5		3.9	2.5
4	1.6	6.2	6.2		4.7	1.5
6	8	8	9		8.3	0.3
7	3.9	14.9	5.2	19.2	10.8	3.7
8	4.5	9.3	18	5.3	9.3	3.1
10	1.0	9.2	2.0	7.5	4.9	2.0
12	9	11	9.5		9.8	0.6
14	48.3	35.0	40.0		41.1	3.9
18	18.3	25.6	19.3		21.1	2.3
28	7.3	2.0	1.4		3.6	1.9

Normal Control = 4.9 ± 0.45 Preplasma Cells/1000

FIGURE 9

Preplasma cells in BSA stimulated lymph nodes show an exponential increase between 10 and 14 days following stimulation.

BSA Stimulated Animals: Preplasma Cell Counts
per 1000 Total Cells

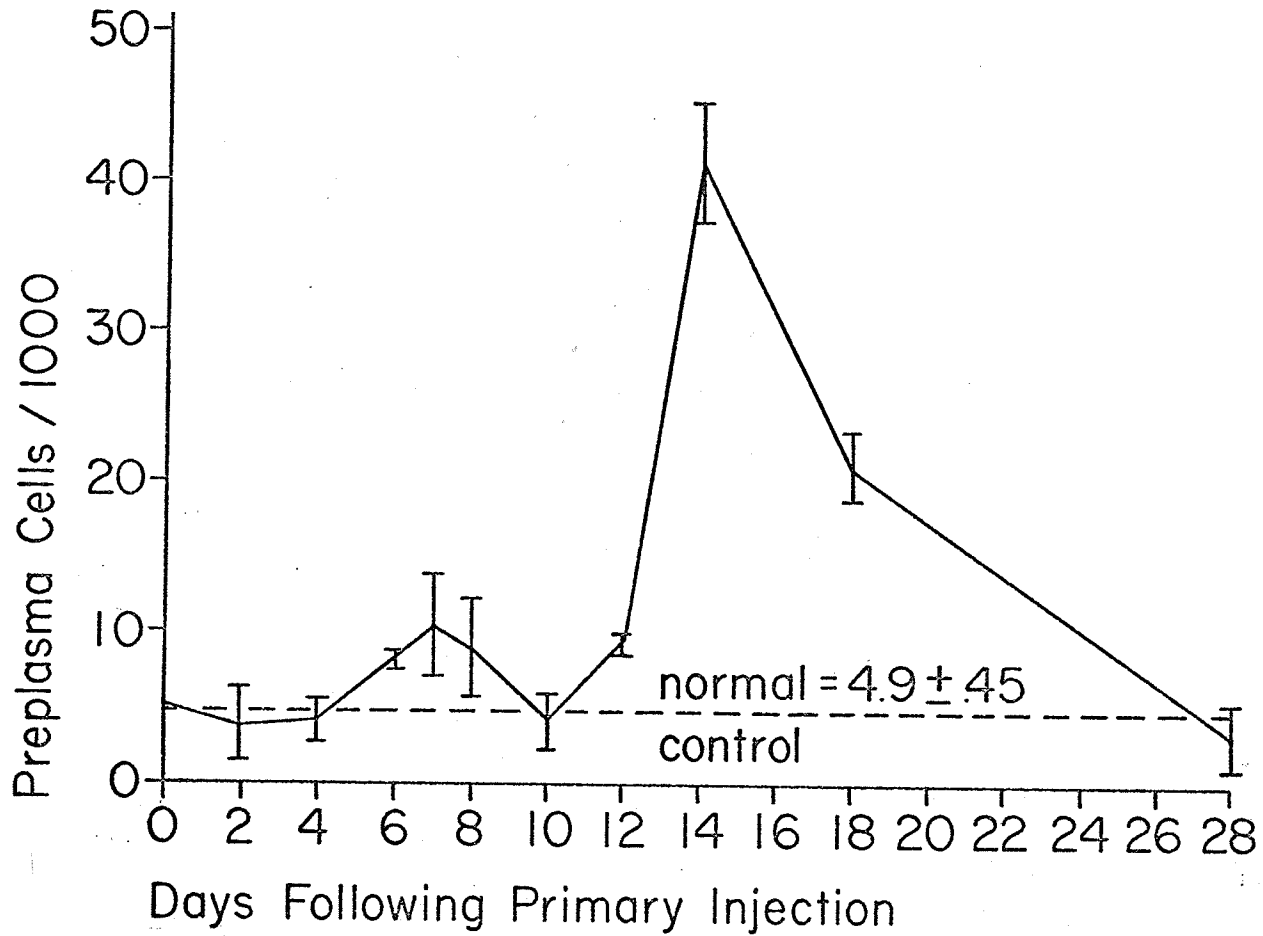


FIGURE 9

The site of injection of the challenge dose was examined only with the naked eye for evidence of inflammation or injury. Within two hours of injection of the challenge dose edema of the local site was evident in the animals in groups 12, 13, and 14. No other sign of injury was observed. The histology of the local injection site was examined in detail in Part III of this thesis.

PRIMARY RESPONSE OF HORSE FERRITIN STIMULATED MICE

SEROLOGY

The serum antibody response of the mice to primary injection of horse ferritin is recorded in Table III and illustrated graphically in Figure 10. The earliest measurable serum antibody titre was obtained 10 days following primary injection of antigen, and then rose rapidly until 14 days. At 16 and 18 days the anti-H Fe titre had dropped considerably, then rose approximately to the 14 day level again by 21 days. Following this second peak a fairly rapid decrease in titre occurred until 28 days which was the last group tested.

LYMPH NODE CHANGES

HGE Stain: The cervical lymph nodes of mice receiving a primary injection of ferritin showed no macroscopic enlargement. Microscopic examination also revealed less conspicuous changes than were observed in the nodes of BSA stimulated mice.

Five days following injection of ferritin the lymph nodes contained a few nodules with enlarged germinal centres, but most of the cortex was composed of ill-defined nodules characteristic of normal lymph nodes. The medulla showed no change from the normal.

TABLE III

This table shows the serum anti-H Fe response, as measured by the hemagglutination technique, in mice from 8 to 28 days following primary injection of H Fe.

TABLE III

PRIMARY SEROLOGICAL RESPONSE TO HORSE FERRITIN

Days Post Inject.	Highest Serum Conc. Tested	Response - No. of Mice Log ₂ - Reciprocal Titre										Total No. of Animals Tested	Mean Titre	S.E.
		0	3.0	4.0	4.5	5.0	6.0	7.0	8.0	9.0	11.0			
8	1:4	6										6		
10	1:16	2		1	1	1		1				6	5.1	.7
12	1:4					1	1			1		3	6.7	1.2
14	1:4								2	2		4	8.5	.3
16	1:8			1		1	1					3	5.0	.6
18	1:4					1	1	1				3	6.0	.6
21	1:4							1	2	2	1	6	8.2	.4
24	1:8						1	2				3	6.7	.3
28	1:8	1	1			1						3	2.7	1.5

FIGURE 10

This graph illustrates the serum antibody response in mice following primary stimulation with horse ferritin.

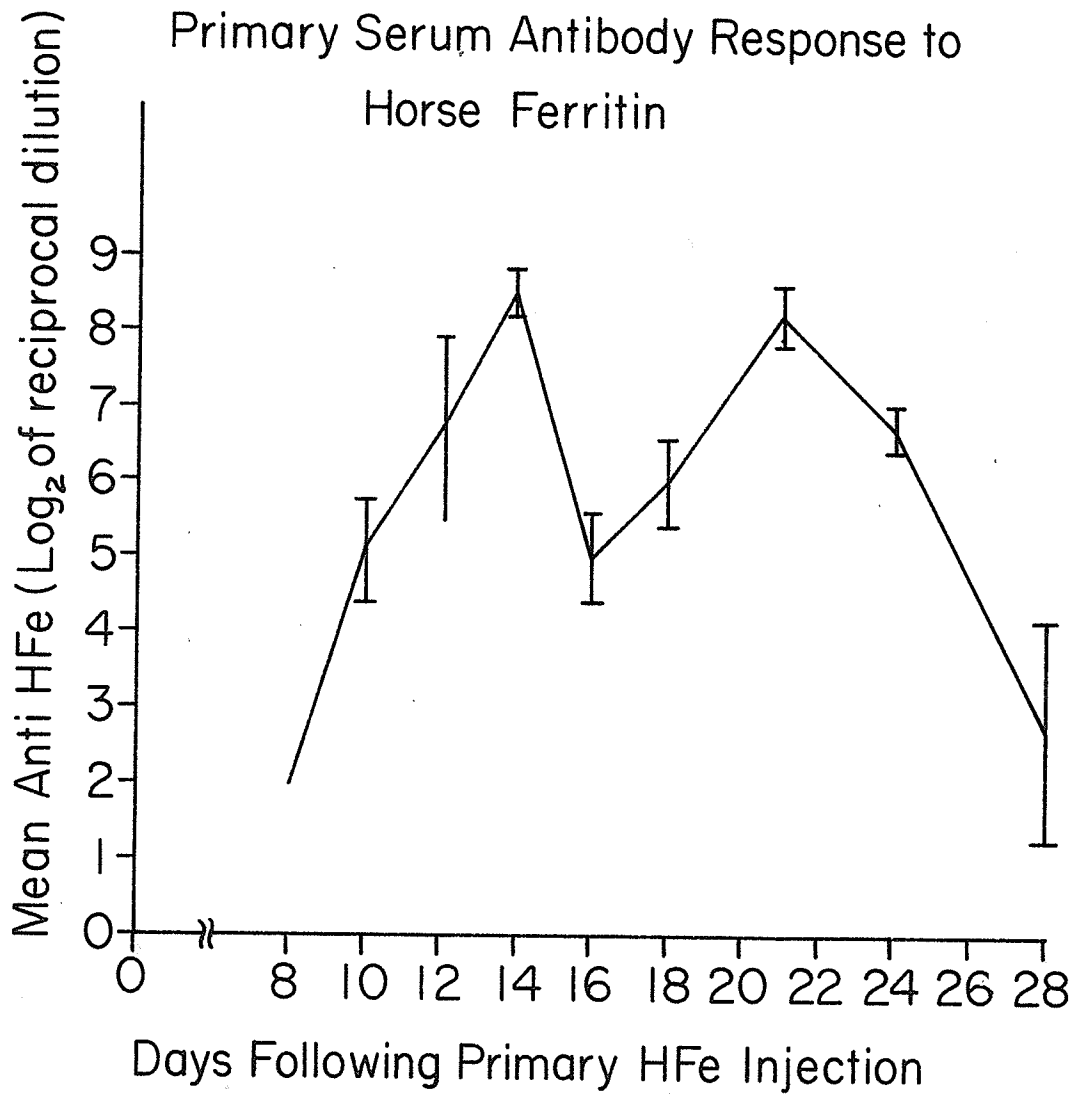


FIGURE 10

At 10 and 12 days there was evidence of more activity in the germinal centres but the medullary area remained unchanged. From 14 to 16 days the lymph nodes appeared to return to normal. However at 18 days there again was evidence of increased activity in the germinal centres. By 28 days a definite trend toward the normal was observed.

Prussian blue Stain: The cervical lymph nodes of primary H Fe injected mice gave a positive Prussian blue reaction from one hour to 7 days following injection (Fig. 11). The stain was heaviest 3 days following injection and was equally intense in the medullary sinuses and in the cortex. In the earlier nodes (1 to 48 hours) the medullary sinuses showed fairly dense Prussian blue staining with the stain in the cortical areas appearing more diffuse. After the third day there was a decrease in staining intensity and was completely absent by the eighth day and thereafter.

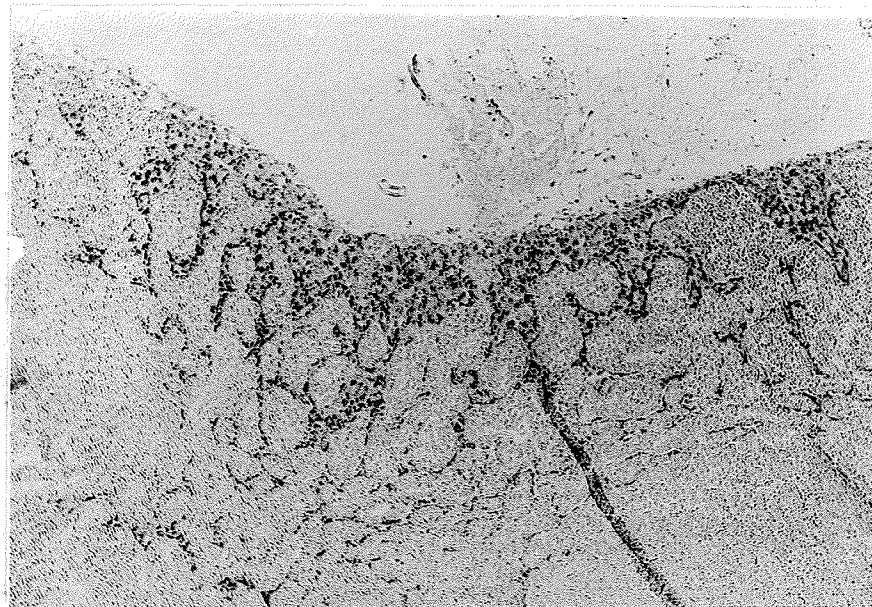
CHANGES OBSERVED IN THE SPLEEN

H&E Stain: The pattern of morphological changes in the Horse Ferritin stimulated spleens followed much the same pattern as described for the spleen of the BSA stimulated animals, however there were some characteristic features. The ferritin-stimulated spleens of the 5 day mice were comparable histomorphologically to the spleens of the 10 day group of BSA stimulated animals. These changes also persisted longer in the H Fe - stimulated spleens, and at 28 days they resembled the 18 day BSA stimulated spleens.

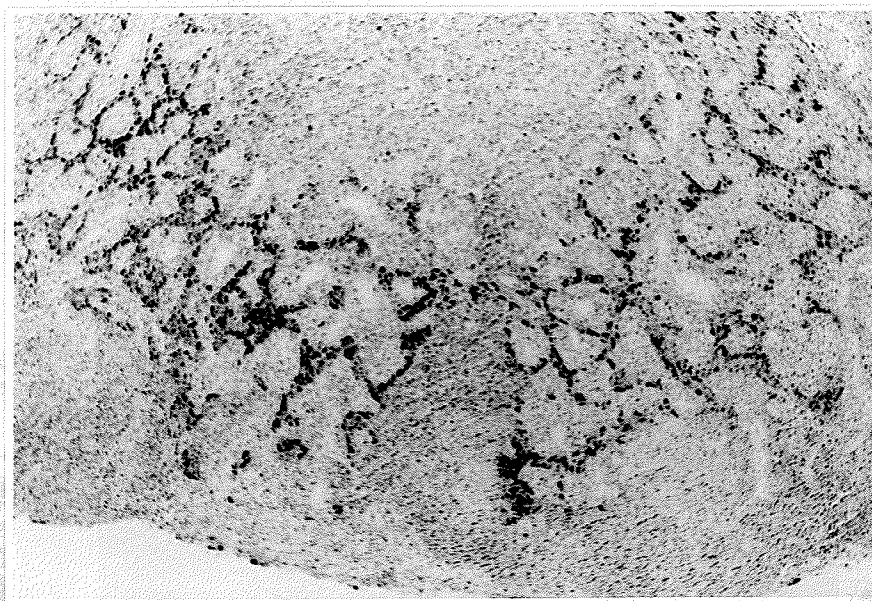
Prussian blue Stain: The Prussian blue stained sections of H Fe stimulated spleens were difficult to evaluate because of the normal

FIGURE 11

(a) Four hours following primary H Fe injection the hilar-medullary area of local lymph nodes showed intense Prussian blue staining. (b) Three days following stimulation the cortex also was heavily stained. Perl's Prussian blue stain. Original magnification 25X.



a



b

FIGURE 11

presence of varying amounts of ferritin in the spleen as indicated by the control sections. There did appear to be more Prussian blue staining in the first group killed following H Fe injection (1 hour) but all the later groups revealed normal or near normal staining.

Figure 12 is an illustration of Prussian blue staining seen in the average normal or control spleens. Figure 13 is the staining observed 1 hour following primary injection of H Fe.

LYMPH NODE PREPLASMA CELL COUNTS

The results of the preplasma cell counts done on lymph node smears of H Fe stimulated mice are recorded in Table IV and illustrated in Figure 14. It is shown that the preplasma cell population in these nodes is lower than normal at 8 and 10 days following stimulation. From 12 to 21 days the preplasma cell count appears to be approximately normal, then decreases again at 28 days following primary H Fe injection.

REACTION TO CHALLENGE WITH HORSE FERRITIN

The hemagglutination test revealed no presence of anti-H Fe in the serum of animals receiving a challenge injection of H Fe seven or ten days following a primary injection. The lymph nodes and spleens showed changes similar to corresponding unchallenged groups, with the exception that traces of Prussian blue staining were observable in the lymph nodes of the challenged animals.

In groups 12, 13, and 14 receiving a challenge injection of H Fe several animals showed some signs of distress within 15 minutes of injection. These signs were pawing the nose, bristling fur on the back, and laboured respiration. Approximately 5% of the animals died within 2 hours of receiving the challenge injection of H Fe.

FIGURE 12

The normal spleen of the mouse shows moderate Prussian blue staining. Perl's Prussian blue stain. Original magnification 25X.

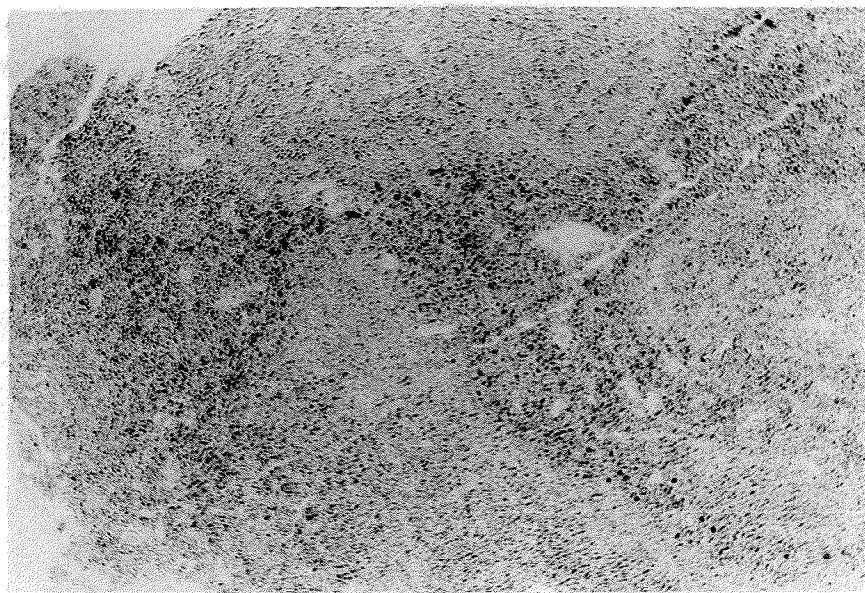


FIGURE 12

FIGURE 13

One hour following intra-mucosal injection of H Fe the spleen shows a marked increase in Prussian blue staining (compare with Figure 12). Perl's Prussian blue stain. Original magnification 25X.

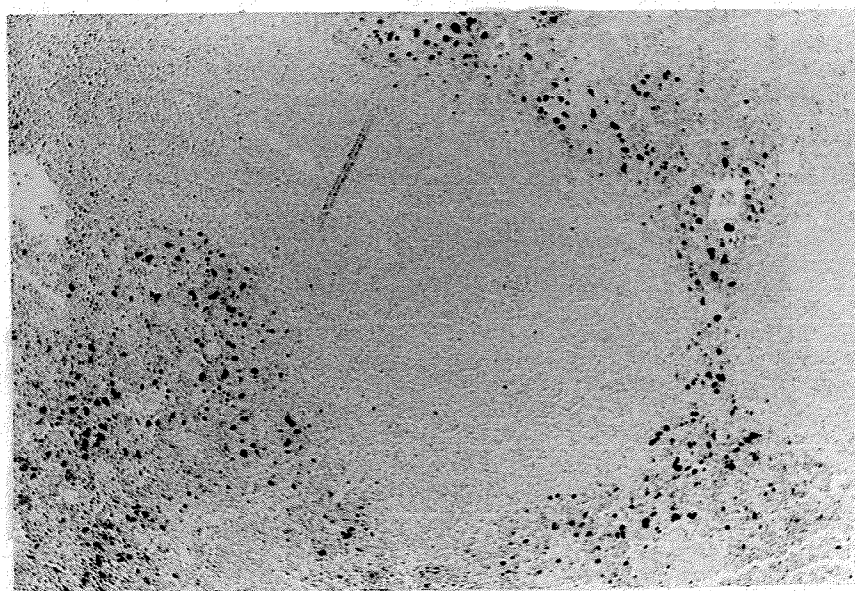


FIGURE 13

TABLE IV

This table shows the results of preplasma cell counts from smears of H Fe stimulated lymph nodes from 2 to 28 days following primary antigen injection. Three or four counts per smear on three or four smears were done and the mean count and standard error calculated.

TABLE IV

PREPLASMA CELL COUNTS IN PRIMARY H Fe
STIMULATED LYMPH NODES

Days After Stimulation	Preplasma Cells/1000 Total Cells-Smear No.				Mean Count	Standard Error of The Mean
	1	2	3	4		
8	2.9	4.6	2.2		3.2	0.7
10	2.6	1.2	2.0		1.9	0.4
12	7.7	4.7	3.5		5.2	1.2
14	2.5	1.5	9.8	2.5	4.1	1.9
18	8.1	3.5	3.2	4.0	4.7	1.1
21	2.7	3.0	2.4		2.7	0.2
28	3.8	1.5	2.1		2.5	0.7

Normal Control = 4.9 ± 0.45 Cells/1000

FIGURE 14

Following horse ferritin stimulation there is no evidence of increased numbers of preplasma cells in the local lymph nodes (compare with Figure 9). The trend towards below normal counts suggests that differentiating blast cells are not being replaced.

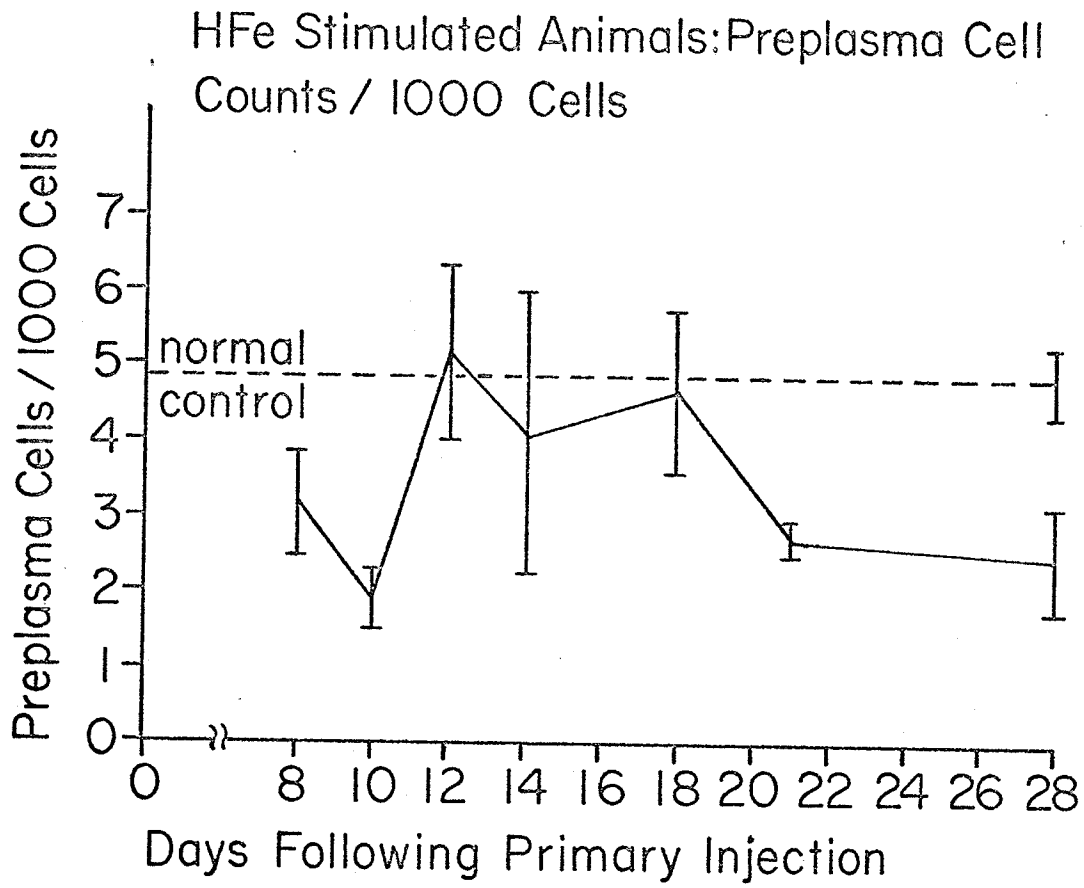


FIGURE 14

The hemagglutination test indicated that the serum anti-H Fe titres of the challenged animals of groups 12, 13, 14 and 18 were similar to the titres of the corresponding unchallenged groups, with a tendency towards being slightly lower than the titres of the corresponding groups.

The H&E stained sections of lymph nodes and spleen from the challenged animals were identical to the corresponding sections of the unchallenged animals.

Prussian blue staining showed an intense positive reaction in the lymph nodes of the animals given a challenge injection of H Fe 13 or 14 days following primary injection. This intense staining was concentrated in the medullary sinuses of these lymph nodes. The spleens showed no deviation of histomorphology or staining properties from their corresponding unchallenged groups.

The local site of challenge injection was observed only for gross clinical evidence of injury. Although obvious edema was present there was no gross evidence of local inflammation.

DISCUSSION

It is generally accepted that the main source of antibody producing cells is the lymph nodes draining the site of antigen injection (Humphrey and White, 1964). If antigen is administered intravenously the spleen becomes the major source of such cells (Fitch & Wissler, 1965). The results of the present study are consistent with these generalizations only in part.

The early gross enlargement of the BSA stimulated lymph nodes and the concomitant histomorphological changes observed suggest the involvement of this tissue in the primary immune response. That the spleen was also participating in the immune response in the BSA and H Fe stimulated animals is suggested by the changes observed in this organ, which are consistent with those described by Fitch and Wissler (1965). The large pale cells appearing in the splenic nodules within several days following antigenic stimulation are characteristic of the splenic response to primary antigen stimulation (Congdon & Makinodan, 1961). These cells are probably primitive reticular cells and with repeated antigen stimulation are entirely replaced by medium sized lymphocytes (Fitch and Wissler, 1965).

The very minimal changes observed in the H Fe stimulated lymph nodes contradict the earlier stated generalization. If the spleen in these animals was the major organ of antibody production one would expect to find more dramatic changes than were observable in the spleens examined in this study. It is significant that although the changes that occurred in the H Fe stimulated spleens were not quantitatively different from the spleens of the BSA stimulated animals, these changes did manifest earlier and remain longer than those seen in the corresponding BSA stimulated spleens. In an organ as large as the spleen, as compared to the size of

the cervical lymph nodes, even relatively minor apparent changes could indicate significant changes in immunologic potential.

The question however remains: If the spleen of the H Fe stimulated animal was the major organ of the immune response, how did it become stimulated by an other than intravenous injection of antigen? Studies on splenectomized rats indicate that splenectomy does not affect immunological response unless the antigen is administered intravenously, suggesting that antigens do not normally reach the spleen if administered by other routes (Humphrey and White, 1964). The highly vascular nature of the oral mucosal and submucosal tissues in the mouse however may mean that antigens injected into these tissues are poorly bound in the tissues and readily enter the large vascular sinuses observed in these tissues. The intense Prussian blue staining observed in the spleen 1 hour following injection of H Fe adds substance to this postulate.

The different morphological response elicited in the BSA and H Fe stimulated cervical lymph nodes was reflected in the results of the preplasma cell counts. The increased cell count in the BSA stimulated lymph nodes was consistent with the picture of plasma cell loading in the medullary sinuses of these nodes during peak antibody production as demonstrated by the serum anti-BSA assay. On the other hand, the results of the preplasma cell counts from H Fe - stimulated nodes suggest that there is even less immune response in these nodes than was suggested by the histological picture. The below normal preplasma cell count during the period of systemic antibody production would lead one to conclude that H Fe is able to stimulate the plasmablast population already present in the cervical lymph nodes of these mice to mature to antibody producing plasma cells, but does not stimulate the differentiation of lymph node

stem cells to plasmablasts.

Ada, et al (1964) labelled a number of antigenic materials, including BSA and H Fe, with radioactive isotopes and traced them to the local lymph nodes. They found that the follicular labelling was similar in BSA and H Fe injected animals and germinal centre formation occurred equally in both. Non-antigenic materials localized mainly in the medulla but in no cases became localized over follicles or caused germinal centre formation.

H Fe has been used extensively by DePetris, et al (1963), for immunological studies. They have found this antigen has consistently produced high titres of precipitating antibodies and causes extensive plasma cell reaction in the lymph nodes of stimulated animals. These authors do not specify whether these reactions are characteristic of secondary responses only, or of primary responses as well.

The lack of agreement between the reported findings and the results of the present study indicate that the response of cervical lymph nodes in white mice to H Fe stimulation needs further investigation. The results of the Prussian blue staining leave no doubt that adequate H Fe is reaching the local lymph nodes to initiate an immune response in these nodes. The lack of such a response, as suggested by the minimal morphological changes and the low preplasma cell counts, suggests that lymph nodes may exercise some selectivity in antigenic response. As the spleen plays a prominent role in iron metabolism it may have a selective advantage also in dealing with foreign ferritin.

The serum antibody response of the test animals to a single primary injection of BSA or H Fe was not inconsistent with the results of similar investigation by other authors, with the exception of the

latent phase of the response. Olson and Wostman (1966), using similar doses of protein antigens in the absence of adjuvant in germfree mice, were able to get measurable serum antibody titre (using a modified Preer technique) from six days onward following primary injection. The peak titre occurred at 8 days. Berlin (1966) injected emulsified influenza virus vaccine into mice and detected gamma M globulins from 3 days, and gamma G globulins from 5 to 34 days following a single primary injection. This investigator found that the titre very rapidly rose to peak, then decreased more gradually.

The timing of the appearance of serum antibody may not be related only to the rate of synthesis of antibody by antibody producing cells. The presence of homologous antigenic material in the tissues may be responsible for masking early antibody production. The antibody synthesized in the early stages would combine with homologous tissue antigen in order to facilitate its clearance from the system. Once the antigen is cleared the newly synthesized antibody would no longer be immediately used up and would be allowed to build up in the serum (Dixon, et al, 1965). By the time the excess antigen is cleared from the tissues the number of plasma cells synthesizing antibody would be greatly increased, resulting in a rapid rise of serum antibody titre. The timing of the first appearance of serum antibody may therefore be closely related to antigenic dose.

The findings of Nossal, Mitchell, and McDonald (1963) underscore the significance of antigenic doses. Their experimental results indicated that, generally speaking, very small doses of antigenic material are effective; that small doses are effective earlier than large doses; and that above a certain limit increase in dose has no effect on the resultant

antibody titre. Nossal, Ada and Austin (1964) found that antigenic flagellin in doses as small as 0.0001 micrograms occasionally resulted in antibody production in rats, and that where normal doses are used only a very small percentage (< 1%) of the injected antigen is directly involved in the immune induction. These investigators emphasize the need to use small antigenic doses in any meaningful study of antigen distribution, localization, behaviour and fate. The fact that in the present study Prussian blue staining was still seen in the lymph nodes seven days after primary injection of H Fe, and the late appearance of serum anti-H Fe suggests that the doses may have been excessive.

Although it is logical that excessive tissue antigen could result in late appearance of serum antibody, this excessive antigen should not affect differentiation of plasmablasts and antibody producing plasma cells. Therefore the preplasma cell counts should reveal an early gradual increase. The results of the present study, however show that rise in preplasma cell counts in the BSA stimulated nodes followed a similar pattern as the serum antibody response and conformed to the normal log phase of antibody production (Vasquez and Makinodan, 1966). These cell counts did indicate a slight early activity between days 6 and 8 following BSA injection. This would normally be interpreted as the period of 19S globulin synthesis which normally precedes the 7S globulin synthesis in the primary response (Nossal, Szenberg, Ada and Austin, 1964). According to Vasquez and Makinodan (1966) however in adult mice antibody synthesis is predominantly of the 19S type throughout the immune response.

The double peak serum anti-H Fe response is difficult to interpret. The small number of samples tested in each group and the inherent danger

of large error in reading double dilution serum titrations, especially at high dilutions, could account for some fluctuation in the curve. However the anti-H Fe titres in groups 16 and 18 (Fig. 10) deviate so markedly from the titres in groups 14 and 21 that error in reading results could hardly be the total explanation.

The histomorphological changes observed in the lymph nodes of the H Fe stimulated animals were consistent with the serological profile, suggesting that the animals in groups 16 and 18 were less reactive to H Fe-stimulation than were the preceding and immediately following groups of animals, or that there was a drop or change of immunologic activity at the particular time interval in all stimulated animals. A possible suggested explanation may be that the change-over from 19S globulin to 7S globulin, if it occurs in mice, occurs at about 16 days following primary injection. The reduced agglutinating property of 7S globulin as compared to 19S globulin could then account for the drop in agglutinin titre at this particular time interval. This could be determined only by analyzing the sera for 19S and 7S globulins.

Although the H Fe stimulated animals produced higher antibody titres than did the BSA stimulated animals the H Fe injected animals appeared not to react as readily to a challenge dose of homologous antigen. This difference in susceptibility to the immune reaction may relate to the different molecular sizes of the two antigens. Cohen & Sapp (1967) found that smaller immune complexes, as determined by the molecular weight of the antigen, caused more severe responses when injected into the tissues of animals. This is so because of the more ready diffusability of the smaller molecules.

SUMMARY & CONCLUSIONS

The primary immune response of male and female adult albino mice to BSA and Horse Ferritin antigens was determined. The response was analyzed in terms of the serum antibody profile, gross and histological changes in the lymph nodes draining the injection site, and histomorphologic changes occurring in the spleen.

Peak serum antibody titres developed 14 days following primary antigen injection in both the BSA and H Fe systems. H Fe induced a higher titre which declined more slowly as compared to the BSA induced antibody titre.

Preplasma cell counts in BSA stimulated lymph nodes rose in conformity with the serum antibody response. H Fe stimulated nodes showed no significant change in preplasmacell counts. Observed histomorphological changes in these lymph nodes were consistent with the results of the preplasma cell counts.

Despite the inconclusiveness of some of the results of this study the following conclusions could be drawn:

1. A single primary injection of 10 mgm. BSA or 5 mgm. H Fe into the mandibular labial sulcus of white mice induced an immune response characterized by serum antibody titres which peak 14 days following primary stimulation.
2. The anti-H Fe titre is considerably higher than is the anti-BSA titre and is maintained at a high level over a longer period of time.
3. The Prussian blue reaction aids in localizing the injected H Fe in the lymph nodes, but is of very limited value in tracing H Fe in the spleen because of the presence of natural ferritin in this organ.

4. A challenge dose of homologous antigen is better tolerated by H Fe sensitized animals than by BSA sensitized animals. Challenge injection of homologous antigen results in edema of the area of injection but does not cause otherwise grossly observable inflammation.

The higher antibody titre produced by H Fe and the longer maintenance of this high titre were desirable features relating to the study planned in Part III. The ability to trace H Fe in the tissues by the Prussian blue reaction was also advantageous. For these reasons it was decided to use H Fe as the main antigen for the studies in Part III, and BSA where heterologous controls were needed. Injection dosages and timing of challenge injections were based on the results of this part of the investigation.

PART III

THE EFFECT OF TRAUMATIC INFLAMMATION
ON THE LOCAL IMMUNE REACTION IN ORAL TISSUES
OF HORSE FERRITIN SENSITIZED MICE

OBJECTS OF THE INVESTIGATION

The hypothesis to be tested was that immune reactions induced with horse ferritin antigen in the maxillary labial sulci of mice would be enhanced by the presence of traumatic inflammation in the local site of the immune reaction. The reaction sites were to be examined and evaluated histologically at intervals from 1 hour to 8 days following challenge injection.

A method was sought by which reproducible local subacute inflammatory lesions could be induced in the oral tissues of mice.

INTRODUCTION

TERMINOLOGY

The hypothesis to be tested is based on the knowledge that inflammation is in large part an expression of increased vascular permeability. This vascular phenomenon sets the stage for a series of reactions, readily initiated by local in vivo immune reactions, which may lead to severe tissue injury (vide infra).

Before entering into the matter in detail it is necessary to clarify several terms which will be used repeatedly in this chapter.

TRAUMATIC INFLAMMATION

Inflammation is the humoral, vascular and cellular response to a noxious stimulus occurring in tissues of vertebrate animals. Different stimuli give rise to varying degrees of inflammation characterized by recognizable differences in vascular and cellular responses. Traumatic inflammation in this thesis, is a tissue response to mechanical injury, as opposed to allergic injury.

ALLERGIC INFLAMMATION

One consequence of local in vivo antigen-antibody reactions is tissue injury and inflammation. When humoral precipitating antibodies are present, local injection of homologous antigen may produce injury manifesting as an inflammatory reaction.

SENSITIZATION AND CHALLENGE

Appropriate injection of animals with antigenic substances will induce specific antibody synthesis. The presence of such antibodies primes the animal for a defensive response to reintroduction of homologous antigen. Such a "primed" animal is sensitized to the particular antigen and reinjection of such antigenic material constitutes a challenge.

ALLERGIC INFLAMMATION

In allergic inflammation the inflammatory reaction is considered to be mediated by the release of pharmacologically-active substances from a few cells initially damaged. These substances may then trigger a sequential chain of reactions resulting in the cellular and vascular changes associated with the classical inflammatory response. This sequential "chain reaction" is reminiscent of that which occurs when blood coagulates and it is likely that many if not all of the steps are enzyme initiated. The inflammatory reaction resulting from antigen-antibody reactions appears to possess additional features relating to platelet aggregation, mast cell degranulation, chemotaxis of polymorphonuclear neutrophils and fixation of various elements of the complement system.

PLATELET AGGLUTINATION

Siqueira and Nelson (1961) demonstrated in vitro that guinea pig or rabbit platelets are agglutinated by antigen-antibody complexes in the presence of serum complement. It was suggested by these authors that the immune complexes attached to distinct receptor substance on platelet surfaces thereby forming a lattice of complexes and platelets. This platelet-agglutinating property of immune complexes was also demonstrated by Barbaro (1961), Mustard (1964), and Uriuhara and Movat (1964). These authors found that platelet aggregation was associated with the release of some chemical mediators, histamine in particular. Uriuhara and Movat (1964) concluded that tissue damage in the Arthus reaction was probably a phenomenon secondary to ischemia resulting from vessel plugging initiated by immune complexes.

DEGRANULATION OF MAST CELLS

It is commonly recognized that the mast cell may be the main source of tissue histamine. The importance of histamine in mediating the early local anaphylactoid reaction was demonstrated by Benacerraf, et al (1954). Small doses of histamine were injected subcutaneously in sensitized guinea pigs followed by an intravenous injection of homologous antigen plus dye. A local allergic reaction occurred at the site of histamine injection, suggesting histamine can cause local fixation of antibody to tissues. Some allergic reactions may therefore be at least partly initiated by factors causing histamine release through mast cell degranulation.

Mota (1961) by the use of in vivo and in vitro methods showed that soluble immune complexes do not act by releasing histamine from mast cells, but that certain non-precipitating antibodies do (Mota, 1961a). He sensitized rats to an antigen (which he does not name) using Freund's adjuvant in one group and pertussis in another. The rats sensitized with Freund's developed a high titre of precipitating antibody and challenging with homologous antigen did not seem to cause a high degree of mast cell degranulation. On the other hand the pertussis sensitized rats produced a low precipitating antibody titre, and challenge was accompanied by a high degree of mast cell degranulation. Mota (1961a) concluded that in rats precipitating antibodies were not responsible for mast cell damage and histamine release occurring in anaphylaxis, but that in some instances a particular factor or type of antibody was produced, along with the precipitating antibody, which was mast cell lytic and therefore responsible for mast cell damage.

POLYMORPHONUCLEAR LEUKOCYTE CHEMOTAXIS

The presence of polymorphonuclear leukocytes (PMNs) in the site of tissue injury is determined by the presence of factors attracting these cells to the site of injury, and having arrived at the site, the ability of the PMNs to cross the vascular wall to gain entrance into the tissues. Increased vascular permeability is at least in part thought to be a result of mast cell degranulation and release of chemical mediators and enzymes. Although injury usually attracts some PMNs, immune complexes have been demonstrated to be particularly chemotactic towards PMNs (Boyden, 1962).

The significance of immune complexes and PMNs in the allergic inflammatory reaction have been adequately documented. Cochrane and Weigle (1958) produced inflammatory lesions that went on to tissue necrosis and sloughing by injecting large doses of antigen-antibody complexes. Microscopically these lesions showed diffuse infiltration of leukocytes and frequent necrosis of blood vessel walls. Injection of homologous antigen into sensitized animals caused more severe reactions with much smaller doses. Infiltration of leukocytes occurred earlier (5--8 hours) and was more marked. These authors suggested that the marked reaction was due to the enhanced release of physiologically active substances from tissue and body fluids when antigen and antibody combined *in vivo*.

By the use of *in vitro* methods Boyden (1962) determined that immune complexes were not in themselves chemotactic to PMNs but that the supernate from such complexes was. He theorized that a soluble constituent of these complexes served to activate an inactive enzyme. This activated enzyme acted on a precursor of a chemotactic substance to make it chemotactic.

The findings of Ward and Cochrane (1964) implicated serum complement in the immune inflammatory reaction. In rats with experimentally reduced complement challenge injection of antigen did not produce accumulation of PMNs and vascular inflammation did not result. Restoration of complement in these animals led to local fixation of complement, infiltration of PMNs and development of typical Arthus vasculitis.

The role of PMNs per se in the developing allergic lesion is not entirely clear. That they have a phagocytic function is unquestionable (Deams and Oort, 1962; Uriuhara and Movat, 1964). The PMN cell contains intracytoplasmic lysosomes containing a number of potential phlogistens with widely differing modes of action (Seegers and Janoff, 1966).

Deams and Oort (1962) examined PMNs from allergic inflammatory sites electronmicroscopically and observed that PMNs which contained phagocytosed immune complexes were devoid of lysosomes. Whether these lysosomes had been lost to the extracellular environment or had formed digestive phagosomes was not stated. The experiments of Uriuhara and Movat (1964) suggest that phagocytosing PMNs involved in the Arthus reaction release a substance which increases vascular permeability. Movat, et al (1964) agranulocytosed experimental animals with nitrogen mustard and found that Arthus or Schwartzman reactions did not become clinical in such animals. In normal animals addition of cytoplasmic PMN granules to the challenge antigen dose served to greatly enhance the resulting inflammatory reaction. These authors concluded that phagocytosis of immune complexes by PMNs was accompanied by release of a permeability factor which was responsible for the severe inflammatory reaction.

Seegers and Janoff (1966) identified the presence of a mast cell rupturing component in lysosomes from rabbit PMNs. This component appeared

not to be present in a preformed or active state in circulating PMNs but required an activating step provided by the exudative environment. Thus mast cell degranulation in allergic inflammation is influenced by the presence of phagocytic PMNs on the one hand, and lytic or inhibitory antibodies and antigens on the other.

The ability of antigen-antibody complexes, per se, to cause tissue injury was investigated by Movat, et al (1963). They injected such complexes into avascular cornea of rabbits. Although polymorphs appeared to phagocytose the injected material, no tissue injury resulted. When the same complexes were injected into a vascularized cornea severe damage resulted. It is clear that allergic inflammatory tissue damage is not due directly to antigen-antibody complexes, but rather a result of vascular changes induced by these complexes. It is apparent that increased vascular permeability is one of the key links determining the severity of the allergic reaction.

It follows then that the presence of traumatic inflammation (characterized by increased vascular permeability) in the site of an experimentally induced allergic reaction could greatly enhance the resultant allergic reaction. The differences between a simple allergic reaction and an allergic reaction occurring in already inflamed tissues should be readily observable histologically. A number of considerations however complicate the experimental induction and interpretation of such differences.

1. If the traumatic inflammatory lesion is too severe it may be difficult to differentiate degrees of increased severity resulting from added injury. Simple injection of antigen material into such a site may

set off a reaction equally as severe as inducing an allergic reaction in the same site. Therefore it was necessary to maintain at least a moderate homeostatic potential in the site of traumatic inflammation.

2. If the serum antibody titre is high, or if the tissue of the test animal reacts severely to the presence of small amounts of in vivo immune complexes the same problem arises as discussed above. It was therefore necessary to so balance the serum antibody level with the reactivity of the animal as to retain a moderate homeostatic potential in the site of the induced immune reaction in normal (as opposed to traumatically inflamed) tissue.
3. Antigenic materials, per se, have phlogistic properties which must be taken into account when evaluating the contribution of the immune reaction to local inflammation. If the differences in inflammatory lesions occurring as a result of injection of antigen into sensitized and non-sensitized animals is slight, it may mean that the immune reaction contributes little to the total lesion.
4. Differences in inflammatory lesions resulting from different types and degrees of injury may be evident only in terms of one or several component factors, rather than as a total histological picture. Evaluation of these inflammatory lesions must therefore be done in terms of the individual inflammatory components.

The following experiments were planned and executed in a manner best suited to giving recognition to the above-stated considerations.

MATERIALS & METHODS

GENERAL PLAN AND LESION CLASSIFICATION

The mice used in this study were of the same species and within the age and weight range of animals used in the study in Part II. They were maintained in the same animal house under similar environmental conditions as previous groups.

Preliminary studies were carried out to determine which method of injury would be best suited to the needs of planned experiments. The oral labia of mice were injected with very small doses of corn oil, turpentine or dissolved methyl cellulose. In other mice a drop of corn oil or turpentine was placed on the surface of the labial mucosa and the mucosa scratched with a sharp sterile needle.

All of these methods resulted in acute local inflammatory reactions not suited to our needs.

In another group of animals injury was induced by a series of punctures made with a sterile 25 gauge needle. In one group 12 punctures were made in the left labial mucosae, the right labia served as normal controls.

These animals were killed two days later, the tissue dissected out, processed, stained with hematoxylin and eosin (H&E) and examined histologically. Similarly other animals received a series of puncture injuries at 2 days following the first, and at 2 and 4 days following the first injury. All tissues were examined 2 days following the last injury. As a result of this study it was determined that the inflammatory lesion resulting from the series of three traumatic injuries most nearly represented chronic inflammation. The lesion will be referred to as "traumatic inflammation".

Groups of adult albino mice were prepared as indicated in Figure 15. Sensitization in group 2 was accomplished by injecting 5 mgm. of H Fe into the mandibular labial sulcus and allowing 14 days for peak anti-H Fe titre to develop. Traumatic inflammatory lesions (vide supra) were induced in the left maxillary labial sulci of both groups. Treatments were so timed that when the traumatic inflammatory lesions were fully developed the sensitized groups were at peak anti-H Fe titres.

At this stage animals in groups 1 and 2 (Fig. 15) received an injection of .05 mgm. H Fe into each of the left and right maxillary labial sulci. The resulting lesions were classified as indicated, that is: (e) "Traumatic Inflammation + Primary H Fe", (f) "Primary H Fe", (g) "Traumatic Inflammation + Challenge", and (h) "Challenge". Tissue samples representing each of these lesions were obtained at 1, 6, 12, 24, 48 hours and 4, 6, and 8 days following H Fe injection. Histological examinations were made using fluorescent staining, H&E, Prussian blue and carbol fuchsin-Wright's stains. For purposes of control, "normal" tissue and "traumatically inflamed" tissue (Fig. 15) from both sensitized and non-sensitized animal groups were prepared and similarly stained.

The details concerning preparation of animal subgroups, tissue methodology and histological examination will be dealt with in detail below.

PREPARATION OF ANIMAL SUB-GROUPS

NON-SENSITIZED ANIMALS: LOCAL REACTION SITE

Traumatic Inflammation (Fig. 15): Two groups of 4 animals each were used. Traumatic inflammation was induced in maxillary left labial sulci. Two days following the last injury the animals were killed by an overdose of ether. The left and right sulcus tissues were dissected in

FIGURE 15

The flow chart illustrates the division of experimental mice into sub-groups according to treatment and lesion classification (boxed): a, Traumatic Inflammation; b, Normal; c, Traumatic Inflammation (sensitized); d, Normal(sensitized); e, Traumatic Inflammation + Primary H Fe; f, Primary H Fe; g, Traumatic Inflammation + Challenge; h, Challenge.

ANIMAL PREPARATION

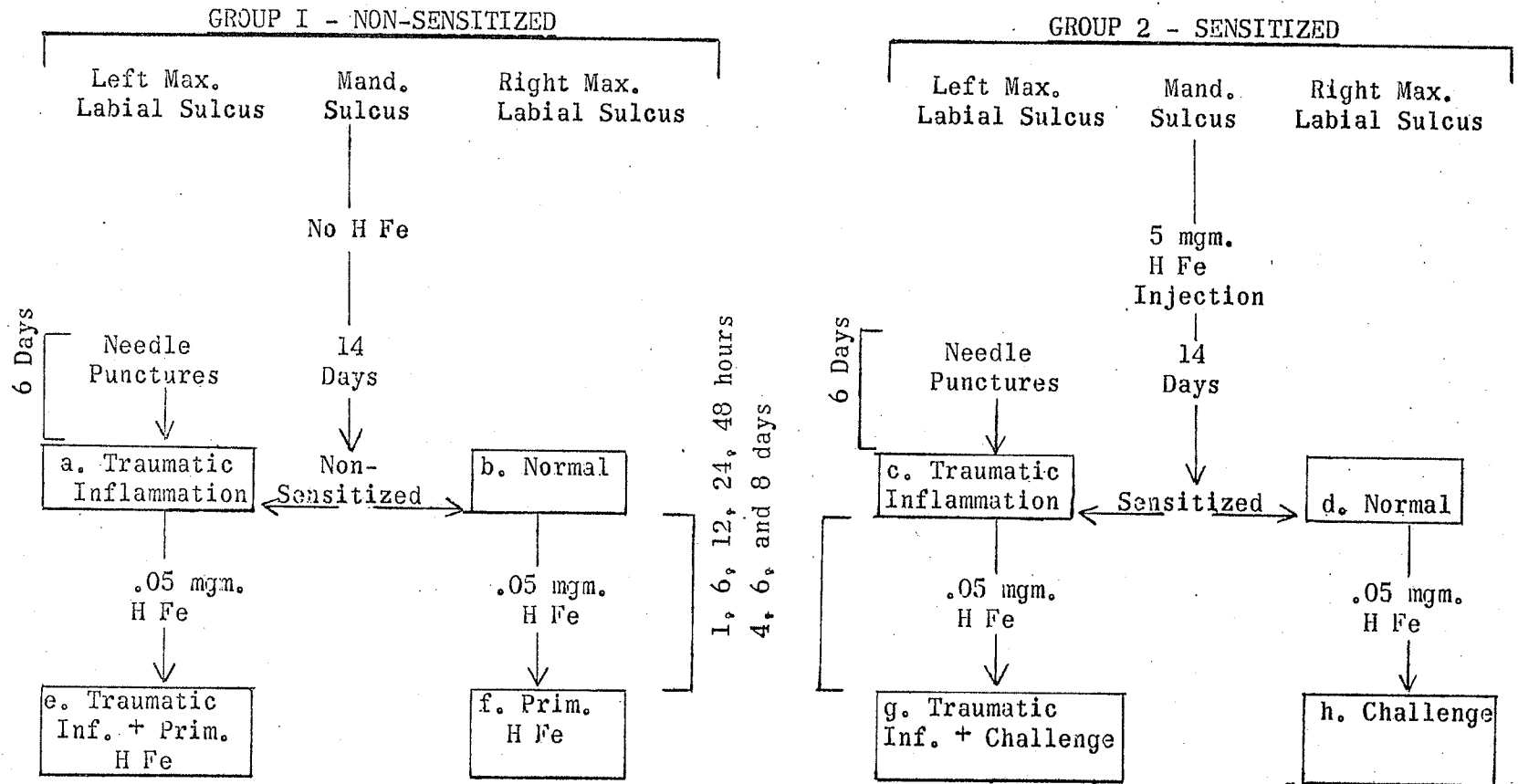


FIGURE 15

the fresh state from four animals for fluorescent staining, the tissues from the other four animals were fixed and prepared with H&E, Prussian blue and carbol fuchsin-Wright's stains. The maxillary right sulcus tissues in both groups served as normal controls.

Primary H Fe and Inflammation + Primary H Fe (Fig. 15): Six groups of four animals each were prepared by inducing inflammation in the maxillary left labial sulci with a series of needle punctures as described. Two days following the last injury both left and right maxillary sulci were injected with 0.05 ml. of 1:1000 H Fe (0.05 mgm.) in normal saline. Animal groups were killed by an overdose of ether at 1, 6, 12, 24 hours; 2 and 4 days after injection. Two animals in each group provided tissue for histological preparation with H&E, Prussian blue and carbol fuchsin-Wright's stains.

SENSITIZED ANIMALS: LOCAL REACTION SITE

Traumatic Inflammation (Fig. 15): Two groups of 4 animals each were sensitized to H Fe. Eight days following the sensitizing H Fe injections the series of needle punctures in the maxillary left labial sulci were begun and followed through as previously described. Fourteen days following primary H Fe injection the animals were in a sensitized state, with traumatic inflammation in the left sulci. The animals were killed by partial exsanguination under ether anaesthesia. The sera were separated from the clots and tested for anti-H Fe. The left and right maxillary labial sulcus tissues of one group of animals were prepared for fluorescent staining, the other group of animals provided tissue for preparation with the usual histological stains.

Challenge and Inflammation + Challenge (Fig. 15): Eight groups of 4 animals each were sensitized and traumatic inflammation induced in the usual manner. Fourteen days following primary injection of H Fe each animal was in a sensitized state and had an inflamed maxillary left labial sulcus. At this time a challenge dose of H Fe was injected into the left and right sulcus tissues. One group of animals each was killed at 1, 6, 12, 24 hours; 2, 4, 6 and 8 days following challenge injection. Killing was done by exsanguination under ether anaesthesia. The sera were tested for presence of anti-H Fe. Half the animals in each group provided tissues for fluorescent staining, the sulcus tissues from the remaining animals were prepared with the usual stains for histological examination.

PRUSSIAN BLUE CONTROLS

The non-specific nature of the Prussian blue reaction made it necessary to determine whether hemorrhage in allergic inflammatory lesions contributed to the Prussian blue reaction. A group of 10 mice were sensitized to BSA as in Part II. Traumatic inflammation was induced in the left labial sulci and a challenge dose of BSA given in left and right sulci at the height of anti-BSA titre (14 days). Two animals each were killed at 6, 24, 48 hours and 4 days post challenge. Tissue preparations from the left and right labial lesions were stained with H&E and Prussian blue.

TISSUE METHODOLOGY

SEROLOGY

The whole blood from exsanguinated mice was allowed to clot overnight at 4-5°C before separation of the serum was attempted. Qualitative assay only for serum anti-H Fe was done using the precipitin ring test (Kabat and Mayer, 1964). Approximately 0.1 ml. of undiluted serum was placed in

a 10 x 75 mm. glass test tube. An equal volume of 0.1% H Fe was carefully layered over the serum. A distinct white ring forming at the serum - H Fe interface can be interpreted as a positive result. According to Kabat and Mayer (1964) this ring constitutes antigen-antibody complexes.

PREPARATION OF SOFT TISSUE SECTIONS

Immediately following death of the animal the total snout was removed by enlarging the oral opening to extend to the temporo-mandibular joints, then extending the cut dorsally through the anterior cranium. Tissues to be used for fluorescent staining were dissected in the fresh state. An incision was made along both lateral borders of the palate extending from the central incisor to the molar area. A blunt instrument was then used to dissect the soft tissue free from the maxillae. The mesial and distal vertical cuts through the freed soft tissue were made with sharp pointed scissors. A block of tissue measuring approximately 4 x 3 x 3 mm. in its greatest dimensions was thus obtained, containing the central area of experimental injury.

Fluorescent Staining: The fresh tissue specimen obtained above was immediately placed on the stage of a Sartorius (Model 27) freezing microtome. Ten sections 8--12 microns in thickness were cut from each specimen and floated onto a clean glass slide. After drying at room temperature these sections were examined under a light microscope and the three thinnest sections were chosen for fluorescent staining. An attempt was made to choose slides very nearly representing the range of the 10 sections cut.

The chosen sections were stained with fluorescein-conjugated rabbit-anti-mouse-globulin globulin (Microbiological Associates Inc.,

Bethesda) according to the method of Coons and Kaplan (1950) and examined under ultraviolet light on a Zeiss Photo microscope.

Because evaluation of fluorescent staining is complicated by tissue autofluorescence and change of staining intensity with time, it is necessary to use adequate controls. In order to minimize errors in evaluation of staining characteristics the killing schedules of test animals were so planned that all tissue specimens relating to a particular study became available at the same time and could be processed simultaneously. In this way it was possible to compare staining characteristics of control and test tissue preparations and to interpret staining in terms of the controls.

Snouts with tissues to be used for histological examination were fixed in toto in 10% neutral formalin for a minimum of 48 hours. Following fixation the left and right labial tissues comprising the site of injury were dissected from the snout with a sharp razor blade, processed for normal histology and paraffin imbedded separately.

Fifteen sections, 5-7 microns thick, were cut from each tissue specimen in the bucco-lingual plane. These sections were divided into three groups of five slides each, every third slide going to a particular group. Tissue preparations for histological examinations were stained with H&E, Prussian blue, and carbol fuchsin-Wright's stains.

Haematoxylin and Eosin Preparations: The H&E sections were examined for general histological-pathological changes in the experimentally induced lesions. Particular attention was directed at evaluation of the PMN response and vascular changes in injured tissues. The quantitative presence of PMN's was recorded as "+" where infiltration was mild, and

"++++" where tissue PMN infiltration was severe. Intermediate degrees of PMN infiltration were represented by "++" or "+++". Where blood vessels were packed with PMNs to a degree inconsistent with tissue infiltration the phenomenon was recorded as a vascular change.

Blood vessel changes were recorded as "+" to "++++" depending upon the severity of the response, and were divided into responses as represented by thrombus formation, PMN margination, increased vascularity, and vessel wall degeneration. Hemorrhage and edema were similarly evaluated and recorded. Other relevant observations were noted for recording as written but not tabulated results.

Prussian blue Preparations: The Prussian blue reaction (Pearce, 1960) was intended to reveal the presence of H Fe in the tissues. As the reaction is not specific for H Fe (vide supra Part II) a careful search of all the Prussian blue stained sections was made to determine staining characteristics in normal and injured tissues.

Prussian blue staining, where present, was seen intracellularly in association with macrophages, extracellularly and/or intravascularly. The degree of staining in these three areas was evaluated and recorded separately using one to four +'s to indicate severity of staining. For purposes of statistical analysis and correlations the mean value of the total reaction was used (tables VIII and IX).

Carbol fuchsin-Wright's Preparations: The third group of 5 slides was stained specifically for mast cells according to the method of Dienststein (1966). Two good representative slides were chosen and the number of mast cells per field at 200 magnification were counted in four

to six areas. Mast cell counts varied considerably from field to field, depending on whether the centre or the periphery of the lesion was being examined. For this reason two mast cell counts per tissue specimen were recorded, the first representing the average count at the centre of the inflammatory lesion, the second number representing the average count in peripheral fields. For purposes of consistency these double mast cell counts were converted to the "+" to "++++" measure by averaging the two counts and placing the result into the appropriate class interval (Table V).

VALIDITY OF OBSERVATIONS

It is agreed that the more objective one can be in interpreting histological material in the first place, the more valid will be the results of later comparisons and correlations. Because of the type of material examined in this study objectivity of analysis was a constant problem. Care was therefore exercised to ensure that tissue preparations adequately represented the lesion under study. Traumatic inflammation was induced in the mucosa of the mouse just medial to the maxillary labial thickening which projects into the space between the incisor and the first molar. H Fe injections were given in the same site. This landmark allowed the reaction site to be precisely identified and dissected out. The number of animals in each group and the sacrifice intervals of animals in these groups were planned to provide sufficient tissue specimens to allow reliable longitudinal evaluation of the lesion.

It can be seen from the methods used that as far as was possible bilateral controls were used on all lesions in the series. This was especially necessary because of the variable serum antibody response in different animals (Table III). This approach facilitated making reliable cross-comparisons of lesions arising from different injury.

In order that cross-correlations of inflammatory components could be readily made it was considered advantageous to evaluate and record these components according to a scale which would have enough latitude within each category to allow for subjective evaluation, and yet allow for a fine enough division of the reaction range in each instance that sufficient data for making correlations became available. The "+" to "++++" scale was found to adequately fulfill these requirements.

Because the initial observations were almost totally subjective there was some question concerning the validity of the histological observations and interpretations. To test this validity 32 tissue preparations were randomly chosen representing the various inflammatory lesions. Identification labels were covered up and the slides read and scored for a total of 86 observations. It was found that the original results were 87% reproducible two months after the original analysis had been done.

STATISTICAL METHODS

If certain components of the inflammatory reaction are dependent on or related to each other, statistically significant correlations between such components should be demonstrable. Simple correlations to determine the degree of association between tissue fluorescence and Prussian blue staining, tissue fluorescence and PMN response; Prussian blue staining and PMN response; and mast cell degranulation and PMN response were done using accepted statistical methods (Smart, 1963).

Analysis of covariance was done between appropriate significant correlations found within the "challenged" and "inflamed + challenged" lesions. Significant correlation within groups, but not between groups,

was interpreted as indicative of the influence of the variable (traumatic inflammation) on the developing lesions.

RESULTS

NORMAL TISSUE

The epithelial covering of the maxillary lateral labial sulcus area in the normal mouse is 4 or 5 cell layers thick, shows a distinct stratum granulosum and a moderately heavy layer of surface keratin. Rete ridges are absent. The submucosa consists of moderately mature fibrous connective tissue with fibroblasts polarized parallel to the epithelial surface. Subjacent to this submucosa bundles of striated muscles are divided by connective tissue sheaths and larger areas of loose areolar tissue. Moderate vascularity is seen with large venous type vessels present in the deeper areolar tissue.

Hematoxylin and Eosin prepared sections show eosinophil-like cells scattered at random in the various subepithelial tissue components. These cells are similar in size to PMNs but the homogeneously eosinophilic cytoplasm is agranular and the basophilic nucleus forms an irregular peripheral intracytoplasmic 'doughnut'.

This cell is probably a variant of the polymorph group. It was not present consistently enough to suggest significance.

Fairly numerous are large, irregular, lightly basophil granular cells with centrally located nuclei. These are mast cells which are numerous in gingival-oral tissues of the mouse (Ham 1953). Pale tissue macrophages are present in relatively small numbers.

The mast cell count in normal tissue revealed 50-70 cells per field (Table V). These cells stained very deeply with Wright's stain, appearing as sacs of densely packed coarse granules. The nucleus was often obscured by the stained granules. Occasionally these cells appeared to be spilling their granular contents into the surrounding tissues.

The mast cells were sparsely scattered in the more superficial intermuscular connective tissue with counts as low as ten per field in these tissues. In the deeper tissues they were much more abundant, usually confined to intermuscular tissue planes and areolar tissue.

Subjecting sections of normal tissue to fluorescein-conjugated rabbit-anti-mouse-globulin resulted in generally dull, diffuse, non-specific tissue fluorescence. Hair follicles generally became brightly fluorescent and in thicker tissues muscle bundles contributed more to the background fluorescence than did other tissue elements. In some instances the endothelial lining of arterioles was seen as a distinct fluorescent line.

In no cases was evidence of a Prussian blue positive reaction seen in normal tissue preparations.

NON-SENSITIZED ANIMALS: LOCAL REACTION SITE

TRAUMATIC INFLAMMATION (TABLE VII, CONTROL)

The series of needle puncture injuries resulted in a macroscopic pebbled appearance of the mucosal surface overlying the area of injury. Microscopically acanthosis with uneven thickening of the epithelium was seen. The submucosa was considerably thicker than in the normal tissue and considerably more vascular. Fibroblastic activity was suggested by the increase in fibroblasts.

Inflammatory cells in the submucosa were confined to several foci of moderate lymphocyte infiltration and some apparently non-viable PMNs. The deeper areolar tissue was diffusely infiltrated with lymphocytes, occasional plasma cells, normal macrophages, and remnants of PMNs. Some eosinophil-like cells were observed but appeared not to be as numerous

as in normal tissue. The mast cell population was very much reduced from the normal.

Fluorescent staining was similar to that seen in normal tissue preparations. No Prussian blue staining was seen.

The results of the mast cell counts in all inflammatory lesions are recorded in Table V. A rapid reduction in numbers of mast cells occurs in inflammation with their complete absence in severely inflamed areas. Return to normal numbers is delayed even after histologically apparent complete return to normal of the injured tissues.

PRIMARY H Fe (TABLE VI)

HGE Preparations: One hour following injection of H Fe the only deviation from the normal was that the blood vessels showed PMN-margination and these cells were also found in moderate numbers in the surrounding tissues. By six hours this picture had reversed with diffuse infiltration of the deeper areolar tissue with PMN cells and normal blood vessels. No disruption of tissue histomorphology was apparent.

Lymphocytes and a few plasma cells had entered the tissues by 12 hours. Several foci of PMN cells with pyknotic nuclei were present. By 24 hours these had been replaced by macrophages and fibroblasts. A complete return to normal had taken place by 48 hours after H Fe injection into normal tissue. At no time had the inflammation spread beyond the site of injection.

Prussian blue Preparations: Tissue sections removed from animals one hour following the primary injection of H Fe showed only minimal Prussian blue staining. Some small macrophages with intracytoplasmic staining were observed. Pale Prussian blue staining was seen among the erythrocytes packing several of the larger blood vessels, and extracellularly in the connective tissue and areolar tissue.

TABLE V

Individual mast cell counts were done at the centre and at the periphery of the experimental lesions. The mean of the tissue counts was converted to the + to ++++ measure in accord with the limits of the class intervals.

TABLE V

MAST CELL COUNTS

Group	Time	Cell Count	Mean	Class Value
Normal Control	-	50 - 70	60	++++
Traumatic Inflam.	-	20 - 50	35	+++
Primary HFe	1 hr.	30 - 50	40	+++
	6 hr.	5 - 10	8	+
	12 hr.	0 - 10	5	+
	24 hr.	5 - 10	8	+
	48 hr.	30 - 40	35	+++
	4 day	30 - 60	45	+++
	6 day	50 - 60	55	++++
Inflam. & Prim. HFe	1 hr.	15 - 40	28	++
	6 hr.	10 - 10	10	+
	12 hrs.	5 - 10	8	+
	24 hrs.	5 - 15	10	+
	48 hrs.	5 - 20	13	+
	4 day	15 - 50	33	+++
	6 day	50 - 70	60	++++
Challenge	1 hr.	15 - 20	18	++
	6 hr.	15 - 20	18	++
	12 hr.	20 - 40	30	++
	24 hr.	20 - 40	30	++
	48 hr.	40 - 60	50	+++
	4 day	50 - 70	60	++++
	6 day	50 - 70	60	++++
	8 day	50 - 70	60	++++
Inflam. & Challenge	1 hr.	10 - 10	10	+
	6 hr.	0 - 25	13	+
	12 hr.	5 - 20	13	+
	24 hr.	5 - 30	18	++
	48 hr.	40 - 40	40	+++
	4 day	20 - 60	40	+++
	6 day	30 - 70	50	+++
	8 day	40 - 1000	70	++++

Class Intervals: No. of Cells	Class Value
0 - 15	+
16 - 30	++
31 - 50	+++
51 - 70	++++

TABLE VI

The lesions designated as "Primary H Fe" were evaluated in terms of the components appearing in the table. The severity of each response was measured and recorded according to + to ++++ measure.

TABLE VI

TISSUE RESPONSE TO PRIMARY HORSE FERRITIN INJECTION (PRIM. H Fe)

	Hours Post-Injection				Control
	1	6	12	24	
Ring Test	-	-	-	-	-
PMNs	+	++	+*	-	-
Hemorrhage	-	-	-	-	-
Edema	-	-	-	-	-
Blood Vessel Response:					
thrombosis	-	-	-	-	-
margination	+++	+	-	-	-
increased vascularity	-	-	+	-	-
degeneration	-	-	-	-	-
Fluorescence:					
intravenous	-	-	-	-	-
aggregates	-	-	-	-	-
diffuse	+	+	+	+	+
Prussian blue					
extracellular	+	-	-	-	-
intracellular	+	+	-	-	-
intravascular	+	-	-	-	-

* Fragmented or pyknotic

Control - normal tissue

The six-hour tissue preparations revealed a reduced number of small macrophages with pale Prussian blue staining. A large hematoma was present in one of the 4-day tissue specimens and these sections also failed to show a positive Prussian blue reaction.

Tissue Fluorescence: A diffuse background tissue fluorescence was seen in all of the traumatically inflamed tissue preparations. This however was consistent with the staining characteristics of normal tissue.

INFLAMMATION + PRIMARY H FE (TABLE VII)

H&E Preparations: Dense perivascular infiltration of PMNs had occurred within an hour following H Fe injection into the previously inflamed tissue site. There was little evidence of diffuse infiltration of the PMN cells into the surrounding tissues where mononuclear inflammatory cells were seen. Although many PMNs were present among the erythrocytes that packed the large blood vessels margination was not seen, suggesting sluggish flow through these vessels. Evidence of microscopic hemorrhage was observed in several areas in the injection site.

Six hours following H Fe injection the PMNs were more diffusely scattered throughout the tissues with a resultant mixture of PMNs and mononuclear inflammatory cells. The large blood vessels were less densely packed with erythrocytes, and PMNs were generally absent from the lumina. No evidence of hemorrhage was seen.

The only change that had taken place by 12 hours was a marked increase in fibroblastic activity giving the tissues a dense cellular appearance. Lymphocytes were observed at 24 hours and the polymorphs

TABLE VII

The lesions designated as "Inflammation + Primary H Fe" were evaluated in terms of the components appearing in the table. The severity of each response was measured and recorded according to the + to ++++ measure.

TABLE VII

RESPONSE OF TRAUMATICALLY INFLAMED TISSUE TO PRIMARY
HORSE FERRITIN INJECTION (INFL. + PRIM. H Fe)

	Hours Post-Injection					96	Control
	1	6	12	24	48		
Ring Test	-	-	-	-	-	-	-
PMNs	+	++	++	+#	-	-	+#
Hemorrhage	+	-	-	-	-	-	-
Edema	+	-	-	-	-	-	-
Blood Vessel Response:							
thrombosis	-	-	-	-	-	-	-
margination	+	-	-	-	-	-	-
increased vascularity	++	++	++	+	-	-	+
degeneration	-	-	-	-	-	-	-
Fluorescence:							
intravenous	-	-	-	-	-	-	-
aggregates	-	-	-	-	-	-	-
diffuse	+	+	+	+	+	+	+
Prussian blue:							
extracellular	+	+	-	-	-	-	-
intracellular	+	+	+	+	+	-	-
intravascular	+	+	-	-	-	-	-

* Fragmented or pyknotic

Control - Traumatic inflammation only

remaining had pyknotic nuclei. Normal tissue was observed in the 48 hour tissue preparations.

Prussian blue Preparations: Moderate numbers of small elongated macrophages with intracytoplasmic Prussian blue staining were observed in the 1 hour tissue preparations. The nuclei of these cells remained distinctly eosinophilic. There was little evidence of extracellular Prussian blue staining except within a number of small blood vessels.

The number of macrophages with intracytoplasmic staining had decreased by six hours following H Fe injection. An area of previous hemorrhage showed pale extracellular Prussian blue staining. Diffuse pale staining was still present in the lumina of erythrocyte-packed venules and capillaries.

The 12 hour and later tissue preparations showed no evidence of extracellular or intraluminal Prussian blue staining. A diligent search of the tissue sections revealed the presence of a few stained macrophages. This picture remained constant in the remaining groups of test animals.

Tissue Fluorescence: No deviation from the staining characteristics of normal tissue was observed in traumatically inflamed tissues receiving a primary injection of H Fe.

SENSITIZED ANIMALS: LOCAL REACTION SITE

A reliable criterion for determining if the test animals in the challenge groups were sensitized was to observe the facial edema of challenged animals. The injection of the H Fe solution caused slight bulging of the lateral labia which in non-sensitized animals returned to normal within an hour. In sensitized animals the edema continued to

increase for several hours until in many animals the facial contours were considerably distorted. Animals failing to show at least moderate edematous reaction following challenge were removed from the group and replaced by reacting animals.

The precipitin ring tests on sera from such reacting animals were all positive with the exception of some of the early groups (1-24 hours). The adsorption of serum antibody by injected H Fe would account for this early negative result in sensitized animals (vide supra).

TRAUMATIC INFLAMMATION

The traumatically inflamed tissues of sensitized animals in all respects were similar to similarly inflamed tissues of non-sensitized animals. In several instances fluorescent stained tissue sections showed some areas with a speckled fluorescence. Because of the inconsistency of this staining characteristic its significance could not be determined.

CHALLENGE (TABLE VIII)

HGE Preparations: Sensitized mice receiving a challenge injection of homologous antigen developed moderate edema of the snout within 15 minutes following challenge. This edema increased gradually for several hours, then began to recede within six hours following challenge.

Microscopically the tissue removed 1 hour after injection showed fibrinoid edema with some separation of the deeper muscle bundles. The blood vessels were packed with red blood cells and PMNs. Some larger venous-type vessels were partly occluded by fibrinoid clot. Inflammatory cells were not present in the tissues except for some perivascular infiltration.

TABLE VIII

The lesions designated as "Challenge" were evaluated in terms of the components listed in the table. The severity of response was measured and recorded according to the + to ++++ measure. To find the mean response of the fluorescence and Prussian blue staining components the number of pluses appearing in the fluorescence or Prussian blue columns were added and divided by 3.

TABLE VIII

TISSUE RESPONSE TO CHALLENGE INJECTION OF HORSE FERRITIN (CHALLENGE)

	Hours Post-Injection							
	1	6	12	24	48	96	144	192
Ring Test	-	-	-	+	++	++	++	++
PMNs	+	++	++	+*	--	-	-	-
Hemorrhage	-	-	-	-	--	-	-	-
Edema	+++	++++	++	-	-	-	-	-
Vascular: thrombosis margination increase degeneration	Plugging PMN	+	++	+	-	-	-	-
		-	-	-	--	-	-	-
		-	-	+	+	-	-	-
		-	-	+	-	-	-	-
Fluorescence: intravenous aggregates diffuse mean + value	- - +++ 1	+ +++ # 1.66	++ +++ + 2	++ ++ + 1.66	++ + ++ 1.66	+ + + 1	- - + .33	- - + .33
Prussian blue extracellular intracellular intravascular mean + value	+++ - - 1	+++ ++ ++ 2.33	++ ++ ++ 2	++ ++ ++ 2	+ + + 1	+ + + 1	+ + - .66	- - - 0

* Fragmented or pyknotic

By six hours the edema was more severe and extended from the deeper tissues into the dermis where collagen fibres were separated and swollen. The muscle bundles and muscle layers were separated and in places indistinct. Interstitial fibrin was abundant. Many blood vessels were collapsed by the edema. Those that remained patent showed a variable histologic picture. Some were normal, others partially occluded by clumps of red cells in fibrin mesh. Many capillaries and venules appeared blocked by blood thrombi.

Although PMNs had infiltrated the tissues they did not dominate the cellular picture. Very conspicuous were many large oval or round macrophages with tan-coloured granular cytoplasm (injected H Fe ?). Some lymphocytes had infiltrated the tissues and there was some evidence of increased fibroblastic activity. An abnormal number of the eosinophil-like cells was not observed.

In sections removed 12 hours following challenge the edema was very much reduced with a resultant concentration of inflammatory cells in the tissue planes. Fragmented muscle fibres were especially conspicuous in the more superficial tissues but reorientation of tissue-elements appeared in progress. Many small blood vessels and capillaries were occluded with clumps of disintegrating and fused red blood cells characteristic of red blood cell thrombus.

The 24 hour tissue section histology was dominated by fibroblastic proliferation as evidenced by the presence of many immature fibroblasts. Some of the blood vessel thrombi showed hyalinization. Many small blood vessel walls were swollen with indistinct structure.

Lymphocytes and plasma cells were observed, especially in the areolar tissues. PMNs were fragmented or contained pyknotic nuclei.

Macrophages and granular cells were diffusely scattered in the loose connective tissue.

Fibroblastic proliferation was still dominant in the 48 hour tissue sections. The blood vessels appeared normal. Lymphocytes and plasma cells were present in increased numbers. PMNs were not seen. By 4 days there was evidence of a trend towards normal tissue morphology and histology followed by complete healing without scar tissue in the 6 day tissue sections.

Prussian blue Preparations: The preparations of tissue samples removed 1 hour following challenge showed a strong Prussian blue reaction in the immediate vicinity of the injection site. The staining appeared in relation to lymphatic and vascular channels but was not observed intracellularly or intravascularly.

By six hours following challenge the staining had diffused from the injection site throughout the tissue specimen, excepting the epithelium, and appeared mostly as extracellular stained granular aggregates on a pale blue background stain. Densely stained macrophages were numerous. Prussian blue staining was also observed within many blood vessels.

These staining characteristics remained fairly constant in the 12 and 24 hour sections. By 48 hours the staining was decidedly less intense and less diffuse extracellularly. Small macrophages with intracytoplasmic staining were present. Pale staining was also seen in some small, apparently plugged, vessels. The Prussian blue staining decreased gradually over the next several days and was entirely absent in the 8 day tissue preparations.

Tissue Fluorescence: The animals receiving a challenge dose of H Fe showed similar staining characteristics in right ("Challenge") and

and left ("Infl. + Challenge") tissue specimens.

Tissues removed one hour following H Fe challenge showed variable patterns of fluorescence throughout the tissue preparation. The connective tissue septae dividing muscle bundles in several areas showed bright clumped fluorescence with no fluorescence observed within the muscle bundles themselves. Fluorescent staining was not present in blood vessel but was seen perivascularly. In areolar tissues the fluorescence surrounded the vacuoles, giving them a more ragged outline than seen in normal tissue.

The 6 and 12 hour sections showed less diffuse fluorescent staining, but staining appeared to have been concentrated into large brightly fluorescing clumps. Although most of these clumps appeared not to be related to specific tissue structures some were obviously within blood vessels. Other clumps appeared as fluorescent fragments adherent to blood vessel walls.

By 24 hours fluorescent clumps were still very obvious but appeared to be present less generally distributed. While some areas showed large aggregates of fluorescent material other areas appeared almost normal. Fluorescing material was seen adhering to blood vessel walls. The general tissue morphology was more distinctly patterned than in the 12 hour preparations, suggesting a return to more normal tissue morphology.

By 48 hours the fluorescent clumps had broken up and appeared fragmented in the tissues. Many large blood vessels showed fluorescing fragments on their endothelial surface.

Over the next 48 hours these fluorescing fragments had become smaller and more indistinct. The six-day tissue preparations were similar to control sections.

INFLAMMATION + CHALLENGE (TABLE IX)

In some animals the macroscopic edema following challenge was somewhat more pronounced on the left side (the previously inflamed side) than on the right, but this was not consistently so.

H&E Preparations: Sections removed from animals challenged one hour earlier showed moderate widespread edema and mild hemorrhage and PMN infiltration into connective tissue and muscle bundles. Blood vessels were difficult to distinguish because of the edema and hemorrhage. Concentrations of mononuclear cells formed inflammatory foci in the connective tissue adjacent to the central lesion. Large macrophages were seen in large numbers.

The six hour tissue sections revealed a severe hemorrhagic, acute inflammatory reaction obscuring much of the tissue morphology. Small blood vessels were collapsed or obscured, the large vessels at the periphery of the inflammatory site had empty lumina. Separation of muscle bundles and fibres was extensive.

A dramatic improvement was evidenced in the tissue sections removed 12 hours following H Fe injection. Very little evidence of previous hemorrhage was present, the PMNs appeared condensed into dense strands between muscle fibres, muscle bundles and in the areolar tissues. Muscle disorientation was less conspicuous although many fibres appeared shredded and swollen. Fibroblasts were present among the muscle bundles.

Larger venous type vessels with indistinct vessel walls appeared thrombosed with agglutinated erythrocytes. Small blood vessels were difficult to distinguish because of the high cellularity in the tissues. Several arteriols showed severe occlusion.

TABLE IX

The lesions designated as "Inflammation + Challenge" were evaluated in terms of the components listed in the table. The severity of response was measured by the + to ++++ scale. To determine the mean Fluorescence response or the mean Prussian blue response, the total pluses appearing in the respective columns were added, then divided by 3.

TABLE IX

RESPONSE OF TRAUMATICALLY INFLAMED TISSUE TO CHALLENGE
 HORSE FERRITIN INJECTION (INFL. + CHALLENGE)

	1	6	Hours Post-Injection				144	192
			12	24	48	96		
Ring Test	-	-	-	+	++	++	++	++
PMNs	+++	++++	+++	++*	+	-	-	-
Hemorrhage	++	++++	+	-	-	-	-	-
Edema	+++	++++	++	+	-	-	-	-
Vascular: thrombosis	-	-	++	+	+	-	-	-
margination	-	+	-	-	-	-	-	-
increase	+	+	+	++	++	++	-	-
degeneration	-	-	+	++	-	-	-	-
Fluorescence: intravenous aggregates	-	+	++	++	++	+	-	-
diffuse	-	+++	+++	++	+	+	-	-
mean + value	+++	+	+	+	++	+	+	+
	1	1.66	2	1.66	1.66	1	.33	.33
Prussian blue extracellular	++	+++	+++	++	++	++	+	+
intracellular	+++	++	+	+	+	+	+	+
intravascular	++	++	++	++	+	+	-	-
mean + value	2.33	2.33	2	1.66	1.33	1.33	.66	.66

* Fragmented or pyknotic

Fragmentation and pyknosis of PMNs had occurred by 24 hours. Lymphocytes and fibroblasts were present in the area of previous injury. There was no evidence of tissue necrosis. Fibrinous edema still appeared to separate muscle fibres.

In a number of areas larger pools of agglutinated and partly hyalinized red blood cells could be seen with vessel walls absent or very indistinct. Several of these thrombi had been invaded by fibroblasts suggesting that organization of the thrombi had begun. This phenomenon was also observed in several of the venous sinuses surrounding the deeper hair follicles.

The presence of fibroblasts, lymphocytes and some plasma cells dominated the picture in the 48 hour sections. Separation of muscle fibres was less noticeable but evidence of fragmentation of muscle fibres was still present. The vascular structures appeared more normal, with normal capillary vessels and little evidence of thrombosis left.

Reparative connective tissue was moderately mature and very extensive throughout the tissue sections 4 days following H Fe injection. Some muscle fibres present in the reparative tissue appeared frayed and crenated as if one end of the fibre had lost its attachment. The extensive intermingling of reparative connective tissue and normal tissue constituents contributed to a general disorderly appearance of the tissue sections. Vascularity did not appear to be above normal. Mononuclear inflammatory cells were conspicuous as nests of cells in the connective tissue and areolar tissue.

Over the next several days gradual architectural improvement in the site of injury was observed. By 8 days healing appeared to have been completed with minimum scar tissue formation. Cellular constituents appeared normal except for the persisting presence of widespread nests

of mature plasma cells and scattered lymphocytes.

Prussian blue Preparations: The one hour tissue preparation showed many deeply Prussian blue stained plump macrophages in the areolar and connective tissues, and what appeared as extracellular staining in the walls of several large blood vessels. Pale staining was seen in association with small vessel walls and diffusely in the fibrinous exudate. The areas of dense PMN infiltration were generally devoid of Prussian blue staining.

The six hour sections showed little change except that pale Prussian blue staining was observed in many blood vessels.

A significant change had occurred by 12 hours. Although some macrophages were still observed with intracytoplasmic Prussian blue staining, the bulk of the stained material appeared as extracellular aggregates in the connective and areolar tissues. Some of these granular aggregates were observed in the blood sinuses surrounding the hair follicles. Stained red blood cell thrombi were also present. These staining properties were also characteristic of the 24 hour tissue preparations.

A decided decrease in Prussian blue staining was seen in the 48 hour sections. Small Prussian blue stained macrophages were still present and the granular aggregates appeared fragmented and more diffuse in the tissues. Stained thrombi were observed in small vessels.

The 4 and 6 day sections showed a gradual confinement of Prussian blue staining in the tissues. Eight days following challenge H Fe injection in an inflamed tissue site minimal extracellular Prussian blue staining was still present but was faint and limited to small foci.

Tissue Fluorescence: The fluorescent staining in traumatically inflamed + challenged tissues was similar to normal challenged tissues (vide supra).

PRUSSIAN BLUE CONTROLS

Tissue sections from BSA induced allergic inflammatory lesions gave a faint background positive Prussian blue reaction 1 and 6 hours following BSA challenge in both normal and traumatically inflamed lesions. The remainder of the "challenge" lesions (24 and 48 hour, 4 day) showed no evidence of positive Prussian blue staining.

Mild intracytoplasmic and extracellular Prussian blue staining, was observed in the 48 hour and 4 day sections of "inflamed + challenged" lesions. The stained macrophages were confined to the centre of the inflammatory lesions. Granular aggregates of Prussian blue stained material were not seen in any of the sections.

DISCUSSION

THE VALIDITY OF THE IMMUNE REACTION

Before proceeding into an analysis and discussion of the results, as they relate to the tested hypothesis, it is necessary to establish that the "challenge" and "inflammation + challenge" lesions were in fact a product of an immune reaction.

ANIMAL SENSITIZATION

It has been shown in Part II of this thesis that injection of 5 mgm. H Fe into the oral mucosa of mice will regularly induce a measurable level of serum anti-H Fe between 12 and 24 days following injection (Table III). Peak anti-H Fe level occurs at 14 days. As the oral tissues of mice are relatively resistant to the Arthus reaction (Freund & Stone, 1956) challenge injections of H Fe throughout Part III^{*} were given at peak titre. That animals receiving a challenge injection of H Fe were in fact in a sensitized state at the time of challenge was supported by the development of gross edema in the injection site, and the results of the serum precipitin ring tests (Tables VIII and IX).

INTERPRETATION OF PRUSSIAN BLUE STAINING AND FLUORESCENCE

As has already been mentioned, because of the non-specific staining properties of the Prussian blue reaction and the fluorescein conjugated anti-globulin, one must be cautious about interpretation of the observed results. How can the observer be sure when positive Prussian blue staining represents H Fe as antigen, as antigen-antibody complex, or as non-specific tissue ferric molecules? Similarly, when does fluorescent staining represent antibody, antigen-antibody complexes, or non-specific tissue staining and fluorescence? These problems were dealt with as follows.

Prussian blue staining: The consistent lack of Prussian blue staining in normal tissue sections (Table VI) was adequate evidence that no components were present in normal tissue which gave rise to a positive Prussian blue reaction. Similarly, by consistent absence of Prussian blue staining in traumatically inflamed tissues, (Table VII) it was concluded that inflammatory components present in such tissues did not contribute to staining.

Following injection of H Fe into normal tissues moderate Prussian blue staining was observed in the 1 hour tissue preparations extracellularly in the tissues, in the cytoplasm of the macrophages, and in the blood vessels. By 6 hours all the H Fe had apparently been removed from the tissues, for Prussian blue staining was present only in the cytoplasm of small numbers of macrophages. This rapid clearing phenomenon of H Fe from normal oral tissue of mice is consistent with observations made in Part II where one hour following primary injection of H Fe excessively heavy Prussian blue staining was present in both the local lymph nodes and the spleen.

Primary H Fe injection into a traumatically inflamed tissue site also results in rapid clearance (Table VII) but Prussian blue stained macrophages linger in the tissues beyond 48 hours. It can be seen from Table VII that in these tissues there was also microscopic evidence of mild hemorrhage in the one hour tissue sections. The delayed presence of stained macrophages could therefore represent a gradual breakdown of tissue red blood cells and uptake of ferric breakdown products by macrophages. On the other hand the inflammatory lesion may function to retain injected H Fe longer by virtue of lymphatic blockage phenomena.

From these observations it is reasonable to conclude that positive Prussian blue staining in the studied tissues of non-sensitized mice is to a high degree representative of H Fe present in the tissues. In discussing the staining characteristics arising from H Fe injection into tissues of sensitized animals the consideration of immune complexes needs to be introduced. This will therefore be dealt with a little later.

Fluorescent Staining: It is recognized that to date the best method of demonstrating the presence of specific antigen or anti-globulin in tissues is to use the methods described by Humphrey & White (1964), whereby the test tissue, is, if antibody is sought, first flooded with the specific antigen to allow union of specific tissue antibody with antigen. Washing the preparation will remove all but specifically bound antigen. This bound antigen can be identified by subjecting it to fluorescein-conjugated specific antibody. As far as we were aware such specific fluorescein-conjugated antiglobulins are not available commercially. Because our laboratory is not equipped to prepare such materials the commercially available rabbit-anti-mouse-globulin globulin was used.

A diffuse background fluorescence was present in normal tissue (Table VI), in non-sensitized H Fe injected tissues (Table VI), in traumatically inflamed tissues of non-sensitized animals (Table VII) and sensitized animals and in the non-sensitized tissue preparations representing H Fe injection into traumatically inflamed tissue sites. In all of these tissues excepting one, there is no basis for suggesting that the fluorescence represented anything but autofluorescence, background fluorescence and/or non specific globulin fractions. In the traumatically inflamed sensitized tissue sections it would not be unreasonable to

expect increased fluorescence due to the presence of antibody binding in inflammatory sites (Benacerraf, et al, 1954; Brandtzaeg & Kraus, 1965). However the non-specific nature of the fluorescent stain used and the thickness of the tissue sections made it possible to observe only greater quantitative changes in fluorescence characteristics. Thus the present method may have identified such antibody binding in mice with high levels of serum antibody. It will be recalled that the sensitized animals in the present investigation were intentionally provoked to a relatively low serum antibody response.

It was thus concluded that the presence of traumatic inflammation in the tissues of non-sensitized and sensitized animals did not give rise to fluorescent staining characteristics noticeably different from those observed in normal tissue.

The Presence of Antibody and Antigen as Immune Complexes: The presence of specific immune complexes in tissues is difficult to "prove" incontrovertably; rather their presence can be assumed only when enough circumstantial evidence is put forth upon which to base such a conclusion. Accepted evidence is demonstration that (i) the animal was in a sensitized state at the time of antigenic challenge, (ii) the presence of antigen can be demonstrated in the tissues of the reaction site, (iii) the presence of specific antibody can be demonstrated in the tissues of the reaction site, (iv) antigen and antibody are present in relationships that will in no way contradict the conclusion that they are present as complexes.

(i) The results in Part II are ample evidence that animals receiving a primary H Fe injection (5 mgm.) were 14 days later in a sensitized state. The results of the ring tests on the sera of challenged mice in this

study are consistent with these findings. The local gross edema following challenge H Fe injection in the labial mucosae of test animals left no doubt that we were dealing with animals sensitized to H Fe.

(ii) It has been established that when Prussian blue staining was present in the non-sensitized tissues it represented injected H Fe which was rapidly cleared from the tissues. From Table VIII it can be seen that when a similar dose of H Fe is injected into the labial tissues of sensitized mice the tissue preparations show a marked increase in Prussian blue staining which is retained in the tissues for a considerable period of time (6 days). No evidence of hemorrhage in any of the observed tissue sections was present, ruling out the possibility that the Prussian blue stain represents stained blood breakdown products. That the tissue, per se, does not react with Prussian blue to produce staining has been established. It can therefore be concluded that the Prussian blue staining in the challenged tissue sections represented the injected H Fe.

Table IX shows the Prussian blue staining characteristics found in traumatically inflamed tissues receiving a challenge H Fe injection. In these tissues as well the Prussian blue reaction was much more intense and prolonged than in comparable non-sensitized tissues. The assumption that this staining is representative solely of injected challenge H Fe cannot be made, in light of the hemorrhagic reaction which developed in the injection site within six hours.

The results of the Prussian blue control test (BSA induced allergic inflammations) indicate that in the sections taken after 48 hours following challenge a proportion of the intracytoplasmic Prussian blue staining

seen was not attributable to the presence of H Fe. Blood breakdown products associated with hemorrhage probably account for this staining. However the staining in the control sections was relatively mild. Corrected mean values would thus not be appreciably different from the mean values recorded in Table IX, representing the presence of antigen in the tissues.

(iii) The marked increase of fluorescence in sensitized tissues following H Fe challenge demonstrated the marked increase of serum globulins in these tissues. Because the fluorescein conjugate was not specific for anti-H Fe it cannot be conclusively stated that the increased fluorescence represented only increased anti-H Fe in the tissues. However the fluorescent results of the various control tissues, the demonstrated presence of serum anti-H Fe in sensitized mice, and the logic of the systemic response to local injection of homologous antigen provide adequate circumstantial evidence that increased fluorescence in challenged tissues was predominantly representative of anti-H Fe.

(iv) What evidence is there to support the conclusion that in challenged tissues the antigen and antibody moieties are present as immune complexes? Observation of the characteristics of the Prussian blue staining in challenged tissues suggests that some factor(s) is/are operating to block the rapid dissemination of the injected H Fe. In non-sensitized tissues injected H Fe rapidly disappeared. In challenged tissues there is evidence of intracytoplasmic antigen, but the bulk of the antigen appears to be retained in the tissues as extra-cellular aggregates. Furthermore, these aggregates are similar in appearance to the fluorescent aggregates seen in the fluorescein stained challenged tissue lesions.

Correlations of the Prussian blue reaction and fluorescence results in challenged tissues add further support to the assumed presence of antigen and antibody as complexes in these tissues. These correlations are illustrated in Figure 16.

Figure 16a shows that in "challenged" tissues there is a direct relationship between the fluorescent staining and the Prussian blue reaction observed in these tissues. The coefficient of correlation (0.85) and the p value (< 0.01) support the thesis that such a close relationship must be dependent upon their presence in tissues as complexes.

Figure 16b illustrates the results of a similar correlation of fluorescence and Prussian blue staining in "traumatically inflamed + challenged" mouse tissues. Although the correlation coefficient is not as high (0.70) as in the "challenge" tissues (0.85) the correlation is still significant ($p < 0.05$). Again, this argues in favour of the presence of H Fe and anti-H Fe in these tissues as complexes.

In Figure 17 the correlation graphs from Figure 16 have been superimposed on each other to give an indication of the overall difference in fluorescence - Prussian blue response between "challenged" and "inflamed + challenged" tissue specimens. It can be seen that the two graphs are almost parallel and very close together. Statistical correlation of the two groups of results indicated that there was no significant difference between the groups ($p > 0.10$). From these results and the earlier histological observations (Table VIII and IX), it was concluded that immune complexes were present equally in "challenged" and in "inflamed + challenged" tissues.

FIGURE 16

The graphs illustrate the correlation between tissue fluorescence and Prussian blue staining in (a) "challenged" and (b) "traumatically inflamed + challenged" tissues. The dots on the graphs represent the mean value of tissue fluorescence and Prussian blue staining (Tables VIII and IX) at various times from 1 hour through 8 days following H Fe challenge.

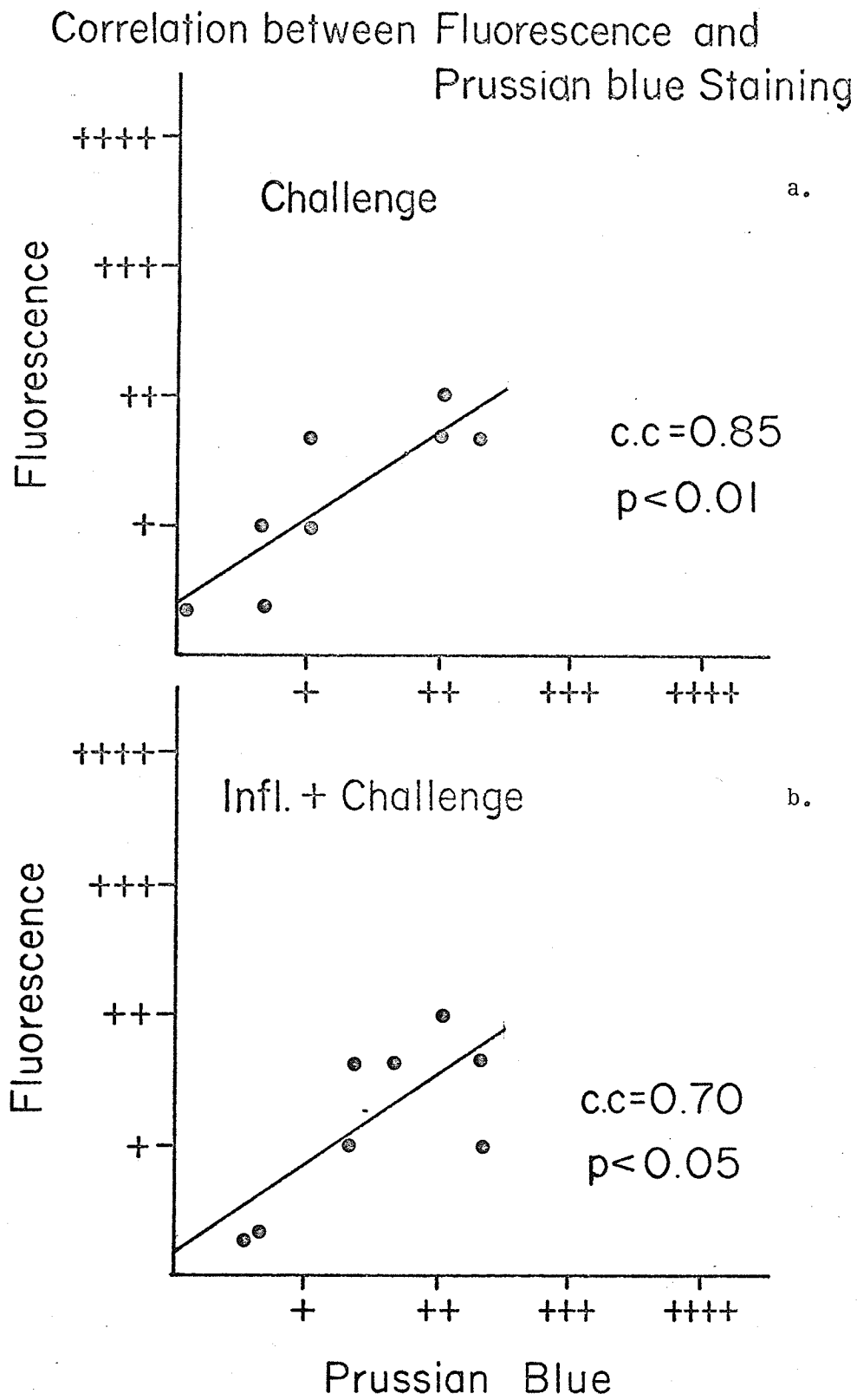


FIGURE 16

FIGURE 17

An analysis of covariance on the two regression lines in Figure 16 indicates that they are not significantly different.

Correlation of Fluorescence-Prussian blue in Challenged and Inflammation+ Challenged Tissues.

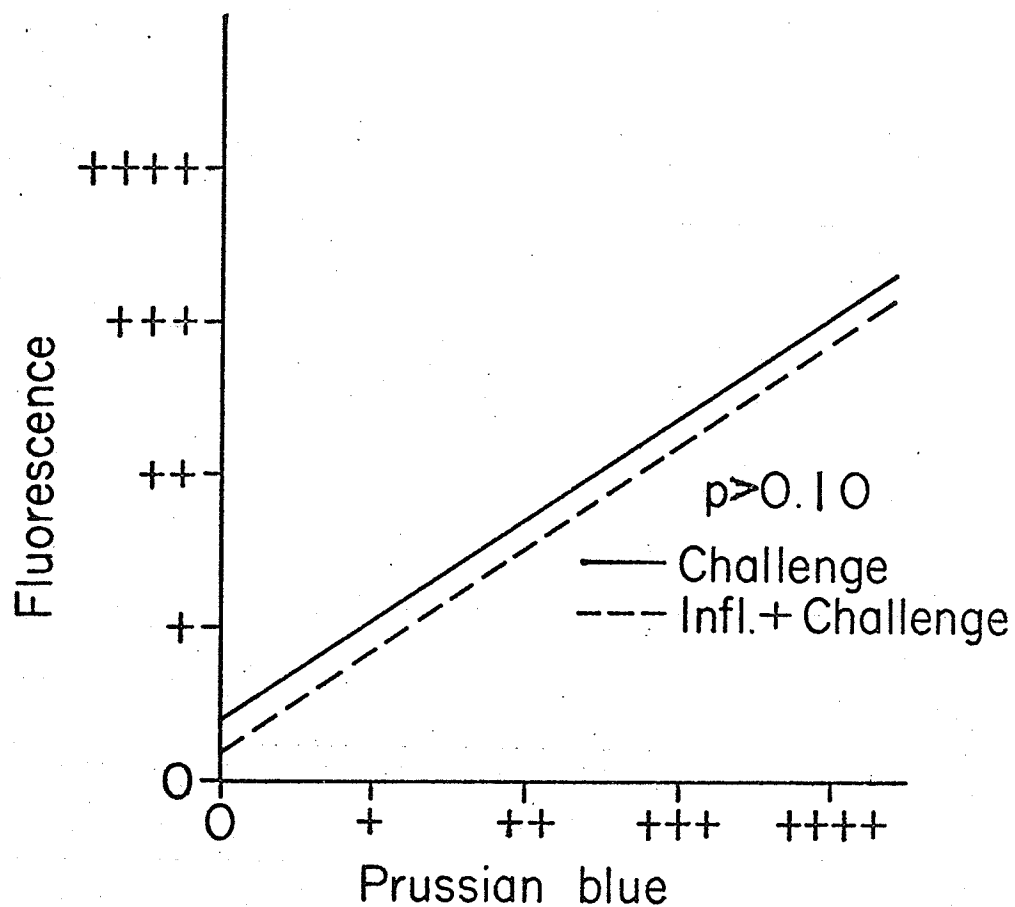


FIGURE 17

The discussion thus far therefore brings us to the following conclusions:

1. The animals used in the "challenge" and "inflammation + challenge" groups were, in fact, H Fe sensitized animals.
2. Prussian blue staining was largely representative of H Fe in the stained tissues.
3. The fluorescence in fluorescein-stained tissues was to a high degree representative of the presence of anti-H Fe.
4. H Fe injection into the tissues of H Fe-sensitized mice gave rise to the presence of H Fe - anti-H Fe complexes in the site of injection.
5. Quantitatively the presence of immune complexes was similar in "challenged" and "traumatically inflamed + challenged" tissues.

THE ALLERGIC INFLAMMATORY LESION

The role of immune complexes in inflammation has been discussed. As stated earlier, their main influence appears to be related to platelet agglutination, mast cell degranulation and PMN chemotaxis.

PLATELET AGGLUTINATION

The methods used in studying our tissue sections did not allow for a direct examination of platelet activity. By inference however our results would support the work of Siqueira & Nelson (1961) and Uriuhara and Movat (1964). In the "challenged" and "inflamed + challenged" tissues red blood cell thrombi were moderately frequent findings suggesting active clot formation. Many of these thrombi were seen to undergo

degeneration and hyalinization. These characteristics were observed only in tissues in which immune-complexes were present.

MAST CELL DEGRANULATION

Figure 18 illustrates the mast cell response in injured tissues. It can be seen that the smallest decrease in mast cell counts occurs following "challenge". Even in "inflamed + challenged" tissues mast cell degranulation appears to be less severe than in "primary H Fe" or "inflammation + primary H Fe" lesions. This would indicate that the H Fe - anti-H Fe complexes do not enhance mast cell degranulation. This is consistent with the findings of Mota (1961, 1961a), for we are dealing predominantly with humoral precipitating antibodies in our system.

If immune complexes do not enhance mast cell degranulation, it would seem from our findings that they may suppress degranulation, that is, H Fe - anti-H Fe as a complex is less effective in causing degranulation than is H Fe alone. This is supported by a comparison of Figure 18b with Figure 18d. The difference in mast cell degranulation in tissues of the two animal groups must be attributed to the different effect on mast cells of H Fe over H Fe-anti-H Fe.

The difference in mast cell response between "inflamed + challenged" tissues, and "inflamed + primary H Fe" tissues (Fig. 18a and Fig. 18c) is not evident in the early lesions (1 - 6 hours) but becomes more obvious in the later lesions. This must be attributed to the reduced numbers of mast cells in these tissues prior to H Fe injection as a result of the traumatic inflammation. The presence of free H Fe in such inflamed tissues causes further degranulation. In sensitized tissues the injected H Fe combines with anti-H Fe with resultant less severe degranulation.

FIGURE 18

This graph illustrates that horse ferritin injection into non-sensitized tissues (c and d) causes more mast cell degranulation than a similar injection into sensitized tissues (a and b). The probable explanation is that in sensitized tissues the injected H Fe combines with humoral anti-H Fe, and is less mast cell lytic as a complex than as free H Fe.

Mast Cell Response to Tissue Injury

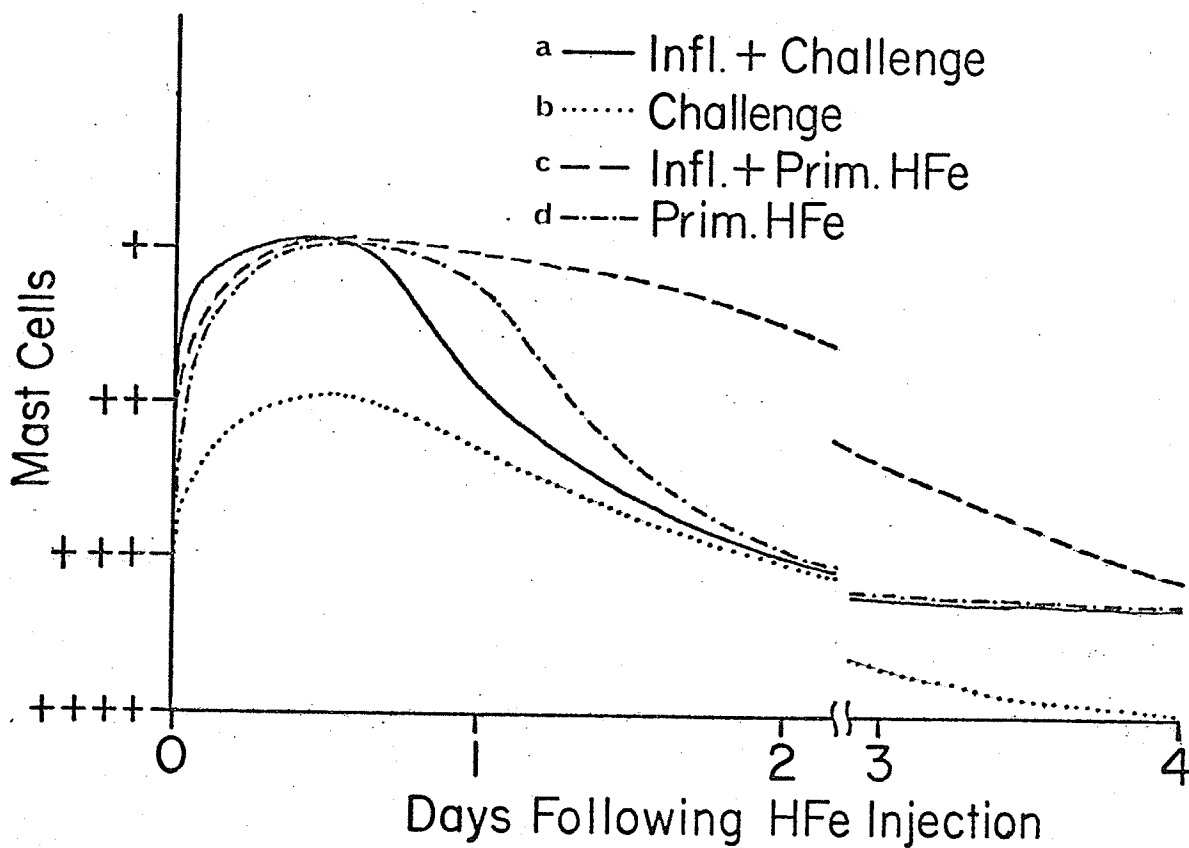


FIGURE 18

PMN RESPONSE

Figure 19 illustrates the PMN response in the various injured tissues. The difference in response in traumatically inflamed tissues, (sensitized, Fig. 19a; non-sensitized, Fig. 19c) following injection of H Fe is striking. As the only variable in these two groups of animals was sensitization, the difference in PMN response must be attributed to the presence of H Fe - anti-H Fe in the "inflamed + challenged" tissues.

The difference in PMN response in "challenge" (Fig. 19b) and in "primary H Fe" (Fig. 19d) lesions is not nearly as striking, the only difference being that the presence of PMNs is prolonged in "challenged" tissues. Examination of the histological sections representing these lesions however clarifies this inconsistency. In "primary H Fe" injected tissues the blood vessels show PMN margination (Table VI). However in the challenged tissues the blood vessels show extensive PMN plugging (Table VIII). This suggests that the PMNs were attracted to the site of injury (where immune-complexes were present) but were not able to cross the vessel wall to gain entrance to the tissues.

The effect of H Fe - anti-H Fe complexes on the PMN response can be more precisely determined by correlating the presence of these components in the allergic inflammatory lesion from the time of induction until healing has occurred. Figure 20 illustrates such correlations with the fluorescence representing the immune complexes. Figure 21 is a similar correlation with the Prussian blue reaction representing the complexes.

It can be seen that both in the "challenged" and "inflamed + challenged" lesions (Fig. 20) there is a high degree of correlation between the quantitative presence of PMNs and fluorescence in these tissues

FIGURE 19

This graph illustrates the relative tissue PMN response to the various types of injury (a, b, c and d).

Polymorphonuclear Response to Injury

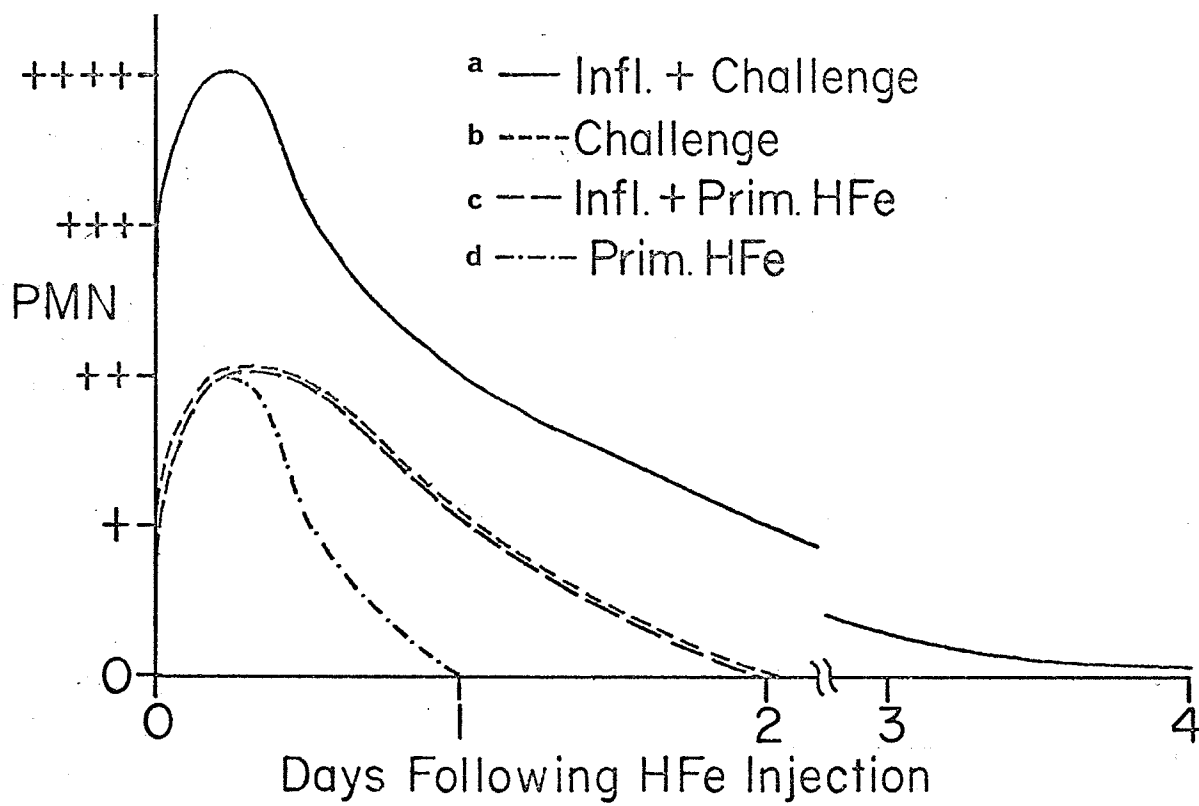


FIGURE 19

FIGURE 20

The graphs illustrate the correlation between the presence of immune complexes (fluorescence) and tissue PMNs in "challenged" and "inflamed + challenged" lesions from 1 hour through 8 days post challenge. The dots represent values from Tables VIII and IX.

Correlation Between Tissue Fluorescence and PMN Response.

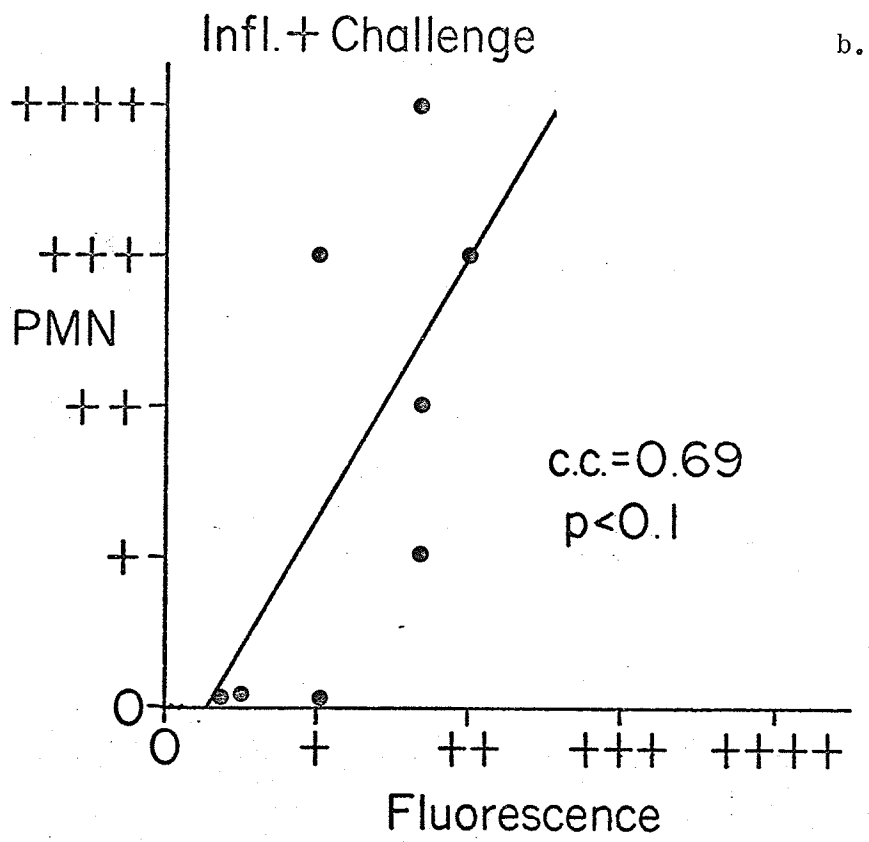
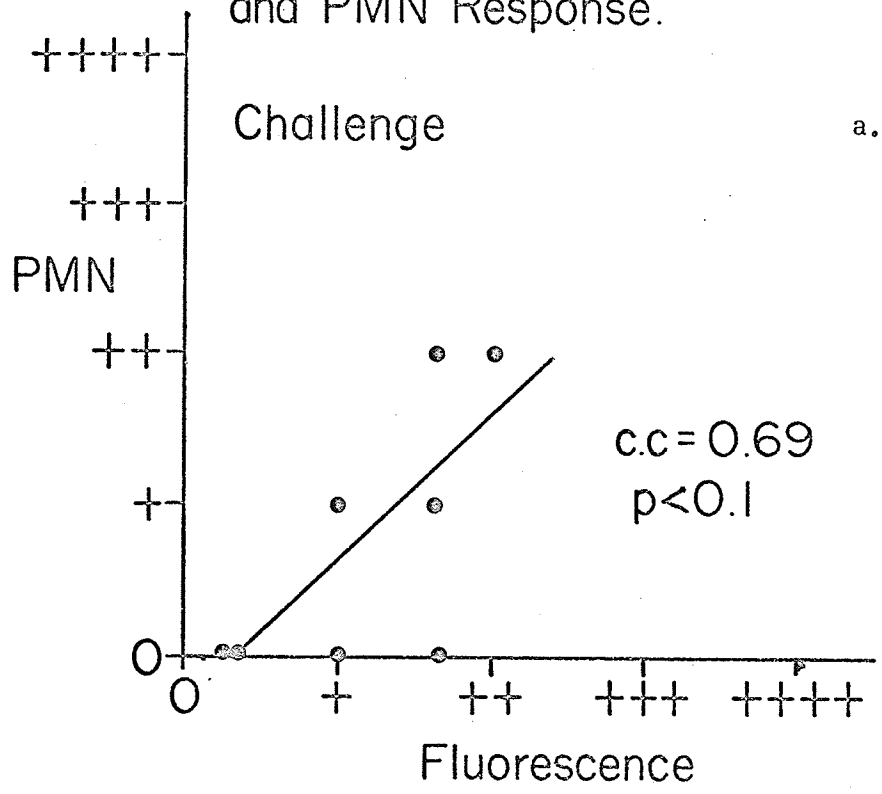


FIGURE 20

(C.C. = 0.69 and 0.69 respectively, $P < 0.1$). When immune complexes are represented by the more specific Prussian blue staining (Fig. 21) the correlation coefficients are 0.87 ($p < .01$) in the "challenged" tissues, and 0.93 ($p < .01$) in "inflamed + challenged" tissues.

These findings are consistent with those of other investigators (Cochrane & Weigle, 1958; Boyden, 1962; Ward & Cochrane, 1964). It is therefore concluded that the PMN response in H Fe challenged tissues was directly related to the presence of H Fe - anti-H Fe complexes in these same tissues.

THE ROLE OF POLYMORPHONUCLEAR LEUKOCYTES

The phagocytic function of PMNs (Deams & Oort, 1962; Uriuhara & Movat, 1964) is directly related to an attempt at clearance from the tissues of foreign material. The effect of concomitant release of mast cell lytic substances from these cells (Seegers and Janoff, 1966) and blood vessel permeability factor (Movat, et al 1964) is somewhat more difficult to explain. It is not unrealistic to postulate that the permeability factor and histamine release through mast cell degranulation are specifically geared towards increased vascular permeability to facilitate the entrance of the immune-complex-attracted phagocytes into the tissues.

In an attempt to determine whether a relationship actually existed between tissue PMNs and decreased numbers of mast cells (degranulation) these two components were correlated in the various tissue sites of injury.

It was found that in inflammatory lesions arising from "primary H Fe" injection (Fig. 22a) and "inflammation + primary H Fe" injection (Fig. 22b) no significant correlation could be found. However in the

FIGURE 21

The graphs illustrate the correlation between the presence of immune complexes (Prussian blue) and tissue PMNs in "challenged" and "inflamed + challenged" lesions from 1 hour through 8 days post challenge. The dots represent values from Tables VIII and IX.

Correlation of PMN Response to Prussian blue Staining

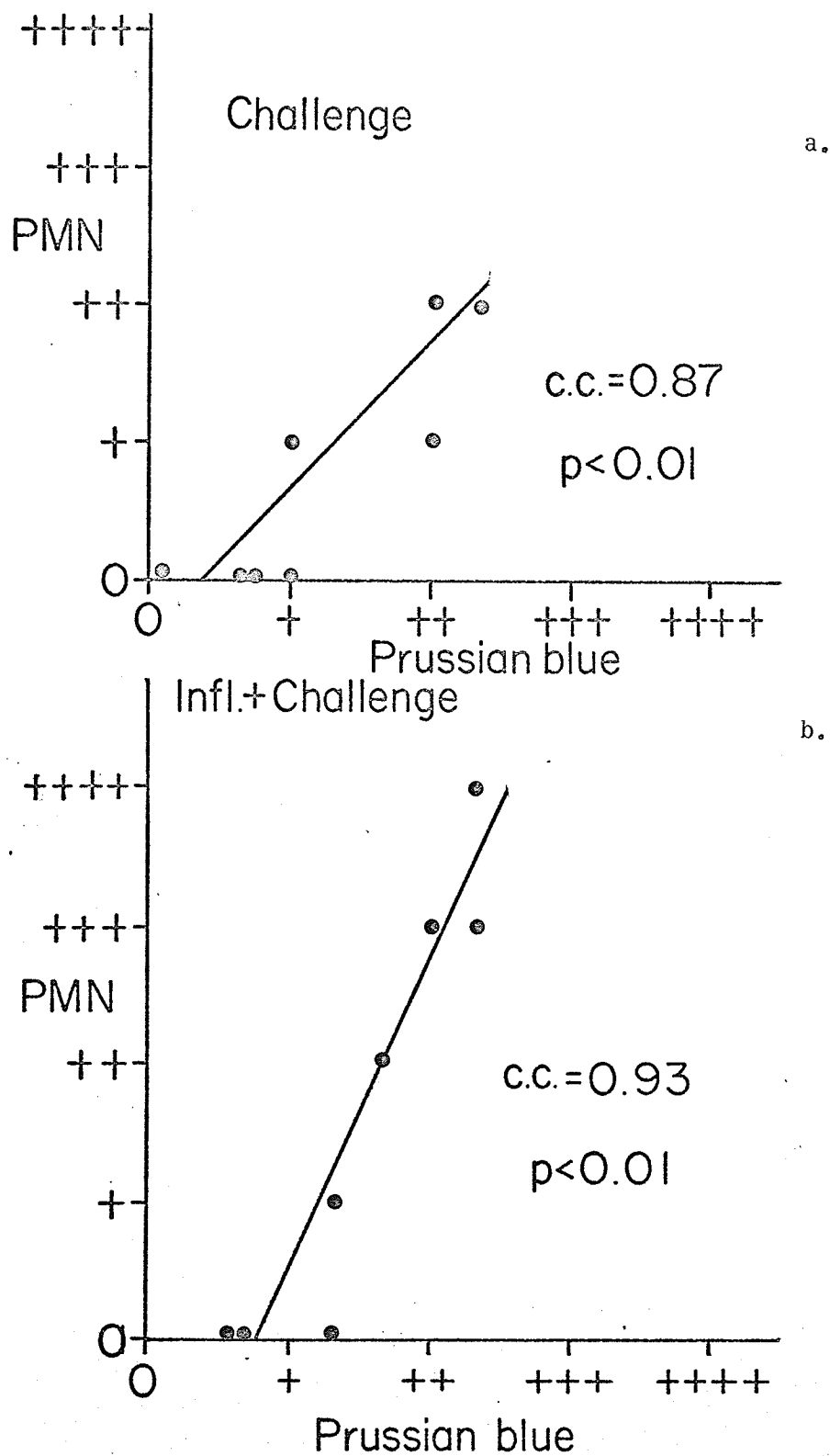


FIGURE 21

FIGURE 22

The graphs illustrate the lack of correlation between tissue PMNs and mast cell degranulation in non-sensitized tissues. The dots represent values taken from Tables V, VI and VII.

Correlation of PMN Response and Mast Cell Degranulation.

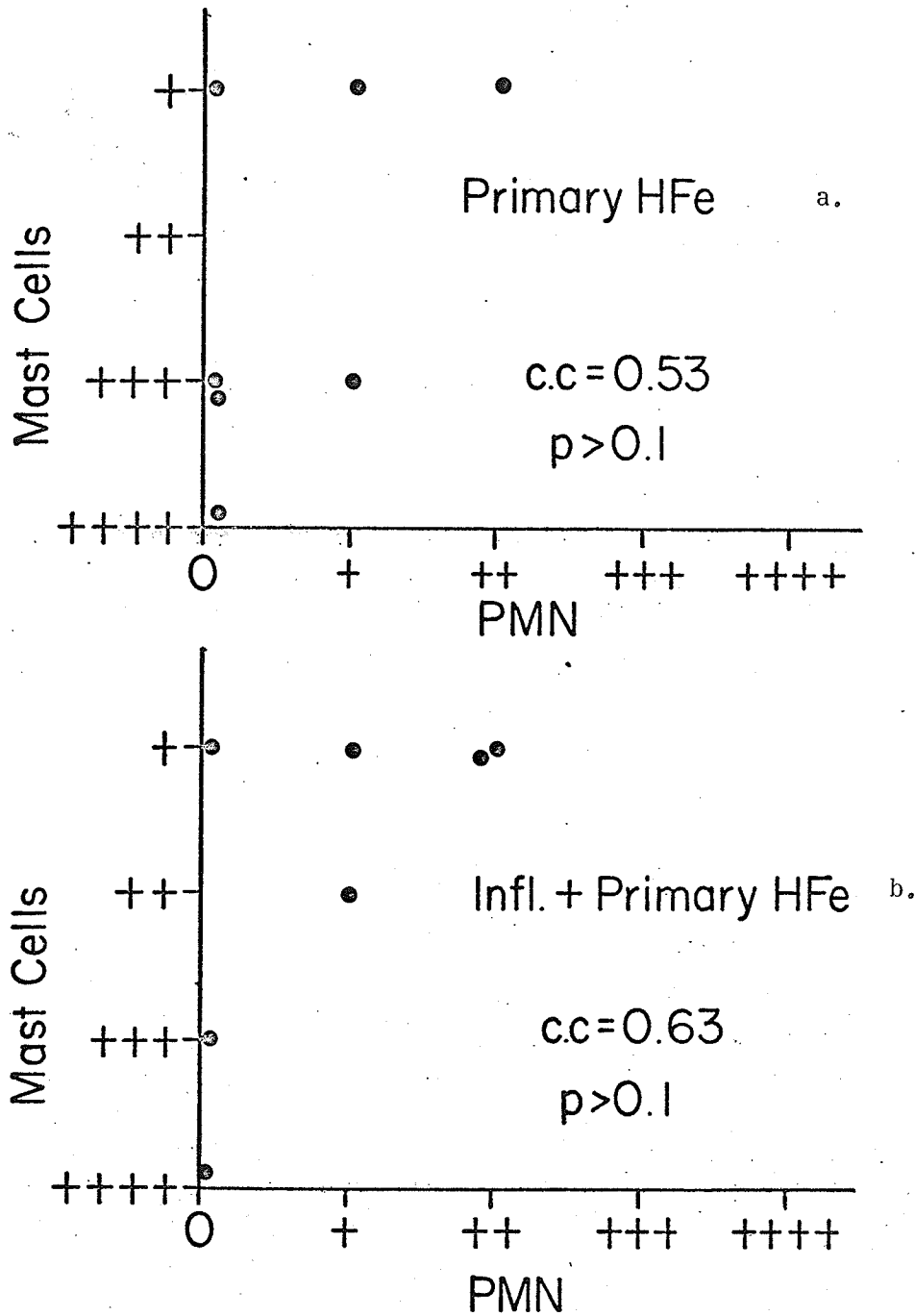


FIGURE 22

allergic inflammatory lesions (Fig. 23 a and b) there was found to be a very significant relationship between mast cell degranulation and the presence of PMNs (C.C. = 0.83 $p < 0.02$ in "challenge" tissues, C.C. = 0.94 $p < .01$ in "inflamed + challenged" tissues).

The fact that a relationship between the two cell types appears to exist in these lesions still leaves us to speculate about the meaning of such a relationship. It is apparent from the presence of PMN plugged vessels in the "challenged" lesion (Table VIII) that in normal tissues the entrance of PMNs into the tissues, where they can best perform their function, is blocked by the blood vessel walls. This suggests that mast cell degranulation and release of pharmacologically active amines is in some way associated with increased permeability and PMN infiltration. The mast cell lytic substance and permeability factor released by phagocytosing PMNs may merely be part of a feed-back mechanism to ensure that PMNs are allowed into the tissues as long as their presence is needed. Initial mast cell degranulation would be the direct result of injury to the tissues. The sensitivity of the mast cells to injury is illustrated by their rapid disappearance from relatively mildly injured tissues (Table V).

THE EFFECT OF TRAUMATIC INJURY ON THE ALLERGIC INFLAMMATORY REACTION

Reference has been made earlier to the different intensity of the PMN response between sensitized and non-sensitized animals (Fig. 19). In non-sensitized animals the PMN response to traumatic inflammation + primary H Fe injection (Fig. 19c) is not more intense but only somewhat prolonged compared to the response in primary H Fe injected tissues (Fig. 19d). This difference represents nothing more than the PMN characteristic in traumatically inflamed tissues (Table VII control). That is, the PMN

FIGURE 23

The graphs illustrate significant correlations between tissue PMNs and mast cell degranulation, in "challenge" and "inflamed + challenged" lesions from 1 hour through 8 days following H Fe challenge. The values (represented by dots) are taken from Tables V, VIII and IX.

Correlation of PMN Response and Mast Cell Degranulation.

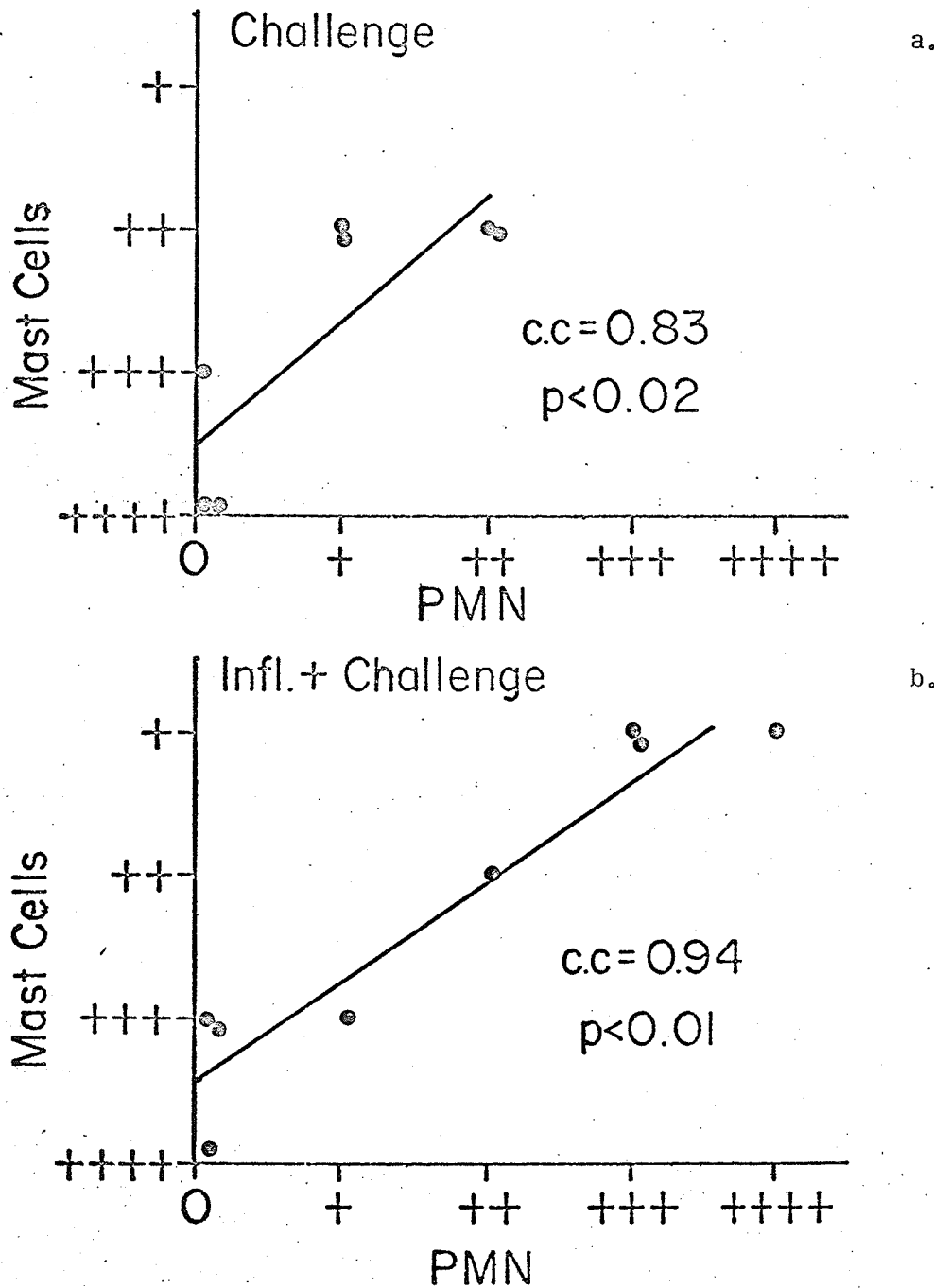


FIGURE 23

response in "traumatic inflammation + primary H Fe" (Fig. 19c) is the sum of the response in the individual lesions (Table VII control and Fig. 19d).

When we examine the reaction in the sensitized tissues the effect of the traumatic inflammatory state is seen to have a more pronounced effect. In "inflamed + challenged lesions" (Fig. 19a) the PMN response is approximately double that observed in challenged tissues (Fig. 19b) both quantitatively and in terms of time. The difference in response is much more than can be accounted for by the simple presence of PMNs in traumatically inflamed tissues prior to challenge injection.

That the traumatic inflammatory lesion has the effect of dividing the challenge response in normal and inflamed tissues into two distinct systems can be shown from the statistical analysis. Figure 24 is the result of superimposing the correlation graph between tissue fluorescence and PMN response in "challenged" tissues (Fig. 20a) upon the similar correlation in "inflamed + challenged" tissues (Fig. 20b). The two graphs are not statistically related ($p > 0.1$). When similar correlations are made between PMN response and Prussian blue staining (Fig. 21) the result again is two linear correlations that are not significantly related (Fig. 25).

The PMN response, relative to the presence of immune complexes, is always greater when the immune reaction site has been conditioned by traumatic inflammation prior to challenge H Fe injection (Figs. 19, 24 and 25). This enhanced PMN response appears to be related to a phenomenon of altered vascular permeability.

Further evidence that the inflammatory response in "challenged" tissues is significantly different from the response in "inflamed +

FIGURE 24

An analysis of covariance on the correlations between tissue fluorescence and PMN response in "challenged" (Figure 20a) and "inflamed + challenged" (Figure 20b) lesions indicated that the PMN response in "inflamed + challenged" lesions was significantly greater than in "challenged" lesions. The fluorescence (representing immune complexes) is similar in both lesions.

Correlation between PMN-Fluorescence
Response in Challenged and Inflamed +
Challenged Tissues.

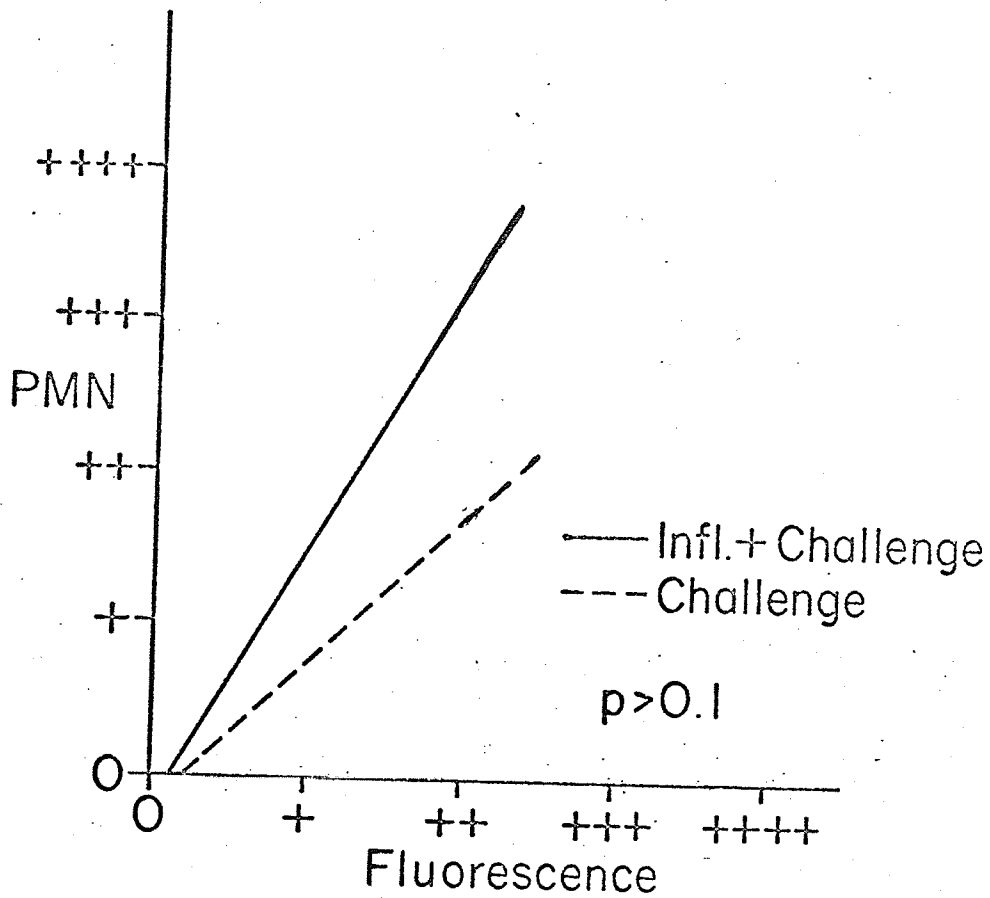


FIGURE 24

FIGURE 25

This graph represents the graphs in Figure 21 superimposed upon each other. The PMN response to presence of immune complexes (Prussian blue) is significantly different in "challenged" and "inflamed + challenged" lesions.

Correlation between PMN- Prussian blue
Response in Challenged and Inflamed +
Challenged Tissues.

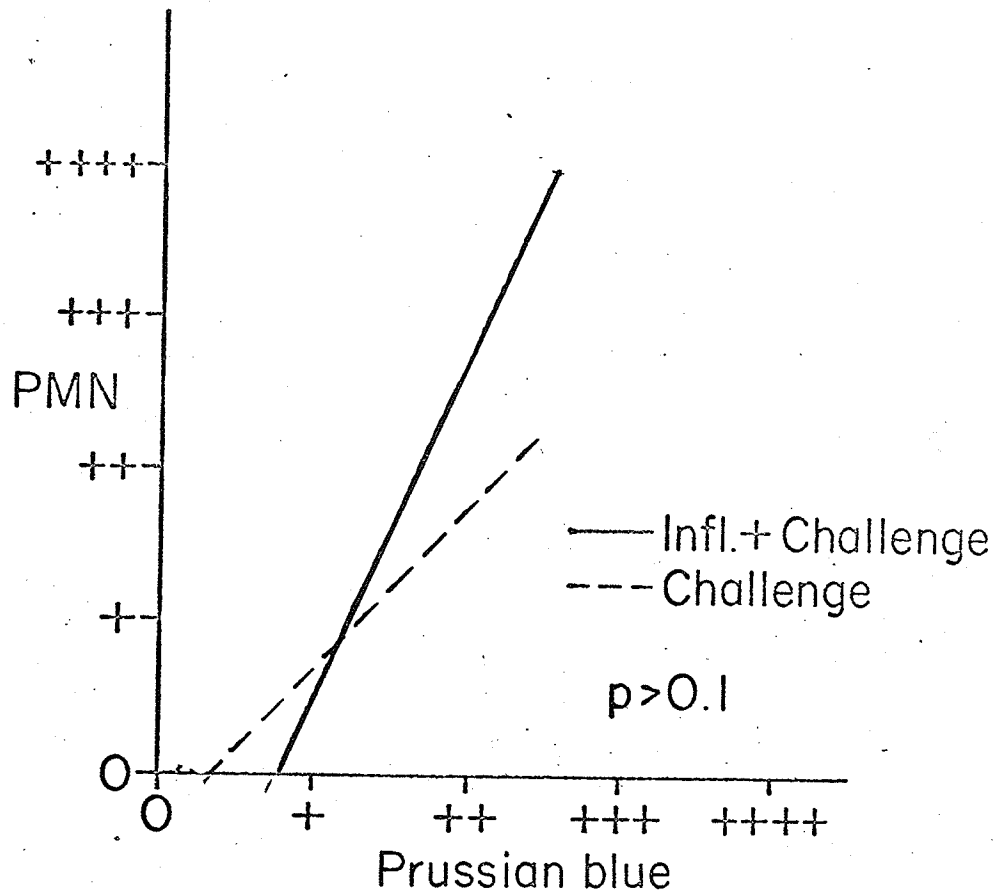


FIGURE 25

"challenged" tissues is the PMN - mast cell response in the two groups of lesions. Fig. 26 superimposes these correlated responses (Fig. 23 a and b) one upon the other. There is no significant statistical relationship between the two groups of responses ($p > 0.1$). Again this can be attributed to the presence of traumatic inflammation in one group of challenged tissues. When traumatic inflammation is present the immune-complex-attracted PMNs enter the tissues and cause almost total mast cell degranulation. Challenge in normal tissue is not accompanied by high PMN concentration in the tissues and thus mast cell degranulation is much less severe.

Figure 27 is a schematic representation of the role of immune complexes in the developing allergic inflammatory lesion (Benacerraf, et al, 1954; Cochrane and Weigle, 1958; Barbaro, 1961; Siqueira and Nelson, 1961; Mota, 1961, 1961a; Boyden, 1962; Deams and Oort, 1962; Gabbioni and Nielsen, 1964; Movat, et al, 1964; Mustard, 1964; Uriuhara and Movat, 1964; Ward and Cochrane, 1964; Schwartz and Vardinon, 1966; Seegers and Janoff, 1966; Wasi, et al, 1966). It has been shown that the findings of the present study support and are supported by the findings of these authors.

Furthermore, the results of the present study suggest that the traumatic inflammatory lesion enhances the reactions indicated on the flow chart by maintaining a tissue environment which is characterized by a state of increased vascularity on the one hand (Table VII, control) and increased vascular permeability on the other. This is borne out by a number of observations. First, the vascular plugging with PMNs in "challenged" tissues (Table VIII) indicates that PMNs are attracted

FIGURE 26

This graph shows the graphs of Figure 23 superimposed upon each other. An analysis of covariance of the two separate regression lines found a significant difference between the response in "challenged" and "inflamed and challenged tissues".

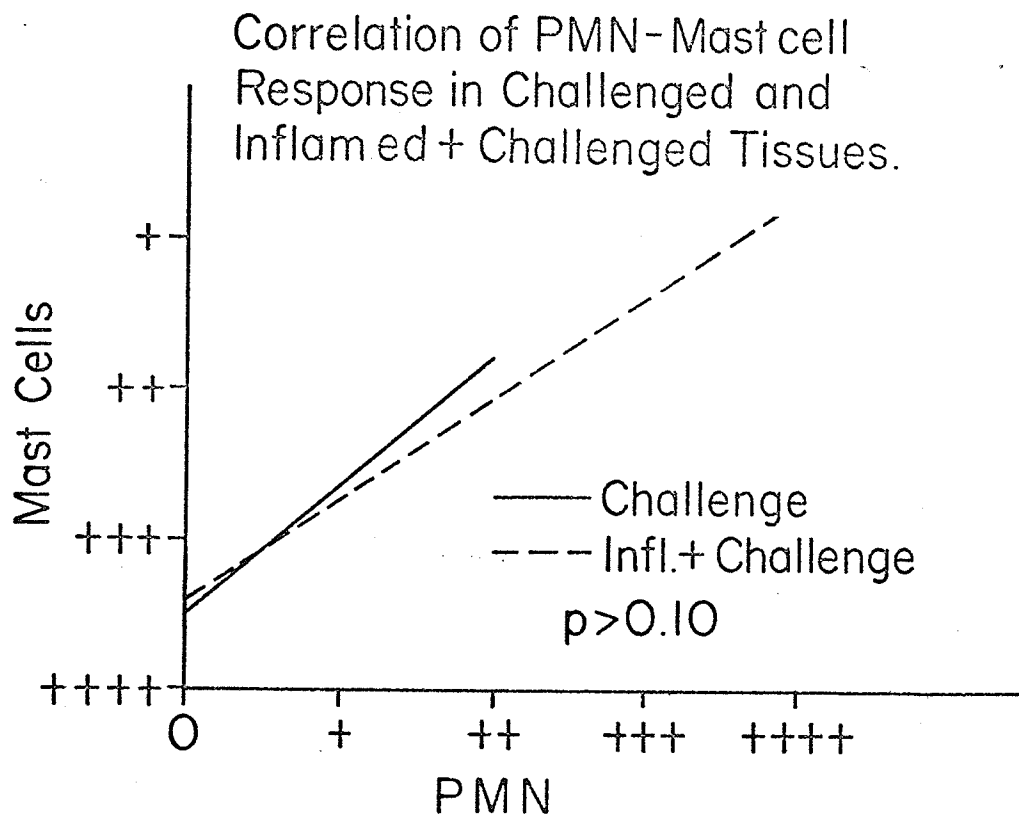


FIGURE 26

FIGURE 27

The flow chart is meant as a summary of the effect of soluble immune complexes on the local tissue constituents. The bold letters indicate where the presence of inflammation in the reaction site may enhance the immune reaction (see text).

Schematic Representation of the Role of Immune Complexes in Allergic Inflammation

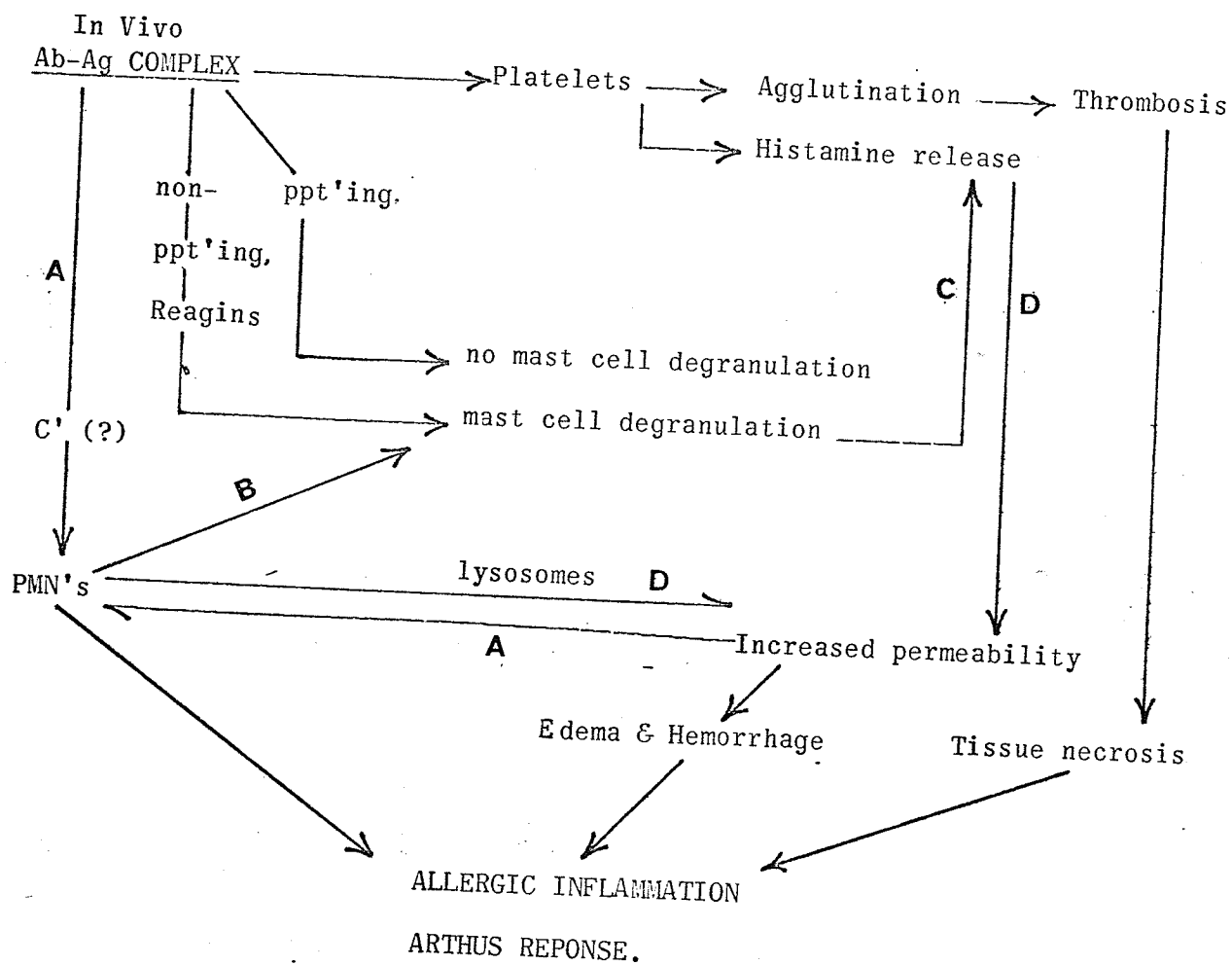


FIGURE 27

to the site of injury but cannot readily leave the blood vessels. Secondly, moderate hemorrhage is a characteristic observed only in early "inflamed + challenged" tissues. Thirdly, the severe PMN response in "inflamed + challenged" tissues is accompanied by dilated and "empty" blood vessels in these sites.

The increased permeability phenomenon characteristic of traumatic inflammation could enhance the allergic reaction in several ways. Firstly, the chemotactic effect of antigen-antibody complexes on PMNs could be enhanced (Fig. 27A). This, as has been shown, results in increased PMNs entering the tissues. Although this would serve to increase the rate of antigen-antibody phagocytosis it would also raise the tissue level of mast cell lytic substances (Seegers and Janoff, 1966) and permeability factor (Movat, et al, 1964). These factors would lead to further mast cell degranulation (Fig. 27B), with a resultant rise in tissue histamine level (Fig. 27C). The increase in tissue histamine and lysosome level manifest in further increased vascular permeability (Fig. 27D). The summation of the entire cycle is manifest as the Arthus response characterized by concentrated PMN infiltration, edema and hemorrhage, thrombosis and possible tissue necrosis.

Thus the results of this study give evidence that non-specific (traumatic) inflammation in the oral tissues of mice do indeed enhance the effects of an immune reaction induced in these same tissues. Although an acute inflammatory reaction occurred in the "challenged" tissues, only in the "traumatically inflamed + challenged" tissues did a characteristic Arthus reaction develop. This is interpreted to mean that the presence of inflammation in the studied tissues so conditioned these tissues that an immune reaction, which would normally fulfill its intended homeostatic function, is overactivated and becomes responsible for tissue injury.

SUMMARY & CONCLUSION

The hypothesis that the presence of non-specific (traumatic) inflammation in oral tissues of adult albino male and female mice enhances the severity of an Arthus inflammatory response has been affirmed. A total of 82 animals made up the control and experimental groups. The test animal selected served well in the chosen model, presenting no handling problem and reacting with acceptable consistency to experimental treatment.

The sensitization of animals with a single primary injection of BSA or H Fe proved adequate in approximately 60% of animals, using the criterion of prolonged gross edema of the snout following a challenge injection of homologous antigen. A greater percentage of animals may have responded favourably had adjuvant or multiple injections been used in the sensitizing procedure.

The horse ferritin has proven a valuable antigen for the following reasons:

- (a) The primary anti-H Fe response was sufficiently high to be measured by the hemagglutination technique.
- (b) Challenge of H Fe sensitized animals resulted in a local immune reaction as determined grossly, histologically and by fluorescent studies.
- (c) Tracing H Fe in tissues with the Prussian blue reaction is particularly beneficial in evaluating the tissue and immune response to antigenic ferritin.

The fluorescent globulin labelling technique was limited by the inability to cut consistently thin sections on the equipment available. However because it was not necessary for our purposes to rely on cellular definition in fluorescent localization, our method did prove acceptable. It was of course not possible to demonstrate the antibody binding in inflamed tissues as has been reported by other investigators.

Statistical methods proved to be a useful tool, and greatly

facilitated the evaluation of the raw data and in illustrating the findings. The danger inherent in evaluating subjective data by objective methods was recognized.

Because of the heretofore lack of conclusiveness in understanding the mediation of inflammation and the definitive role of individual cellular constituents involved, it is admitted that interpretations of the results is based partly on conjecture.

It is recognized that the findings presented by the present author cannot be extrapolated directly to explain the role of immune reactions in the pathogenesis of periodontal disease. The results, as interpreted and presented, do direct us to consider that the inflammatory mechanism and the immune mechanism may in some circumstances operate synergistically in disease production.

APPENDIX

A. Modification of Stavitsky's (1954) Haemagglutination Technique:

It was our experience that cells tanned with a 1:20,000 dilution of tannic acid prior to antigen adsorption were fairly "sticky", resulting in autoagglutination of control cells. This difficulty was partially overcome by using a 1:30,000 tannic acid dilution in place of the 1:20,000 dilution.

Autoagglutination in control cells appeared also to be related to incomplete removal of heterophile agglutinins from the mouse sera by double adsorption with washed sheep red blood cells at 24°C. It was found that single adsorption for 30 minutes at 35°C resulted in more complete adsorption of the heterophile agglutinins. These modifications resulted in settling patterns from which it was easy to distinguish between positive and negative results.

B. Staining of Lymph Node Smears:

1. Air dried slides were fixed in methanol for 5 minutes.
2. Fixed slides washed in saline-phosphate buffer (pH 6.8) for 30 minutes.
3. Place washed slides directly into freshly made Giemsa stain, made as follows, for four minutes:

47 mls. distilled water

3 mls. glycerine

7 mls. Giemsa stock solution

4. Wash thoroughly in distilled water and air dry.
5. Mount smears with Permount.

BIBLIOGRAPHY

- Ada, G.L., Nossal, G.J., Pye, J. & Abbot, A. (1964): "Antigens in Immunity. I. Preparation and Properties of Flagellar Antigens From Salmonella Adelaide". Aust. J. Exp. Biol. Med. Sci. 42: 267-282.
- Antapol, W. and Chrysanthan, C. (1964): "The Schwartzman Phenomenon Mechanism: Newer Concepts". Arch. Path. 78: 313.
- Baer, P.N. and Lieberman, J.E. (1960): "Periodontal Disease in Six Strains of Inbred Mice". J. Dent. Res. 39: 215-225.
- Baer, P.N. and Newton, W.L. (1960) "Studies on Periodontal Disease in the mouse". Oral Surg., Oral Med. & Oral Path. 13: 1134-1144.
- Barbaro, J.F. (1961): "The Release of Histamine From Rabbit Platelets by Means of Antigen-Antibody Precipitates. I. The Participation of the Immune Complex in Histamine Release". J. Immunol. 86: 369-376.
- Beagrie, G.S. and Skougaard, M.R. (1962): "Observation on the Life Cycle of the Gingival Epithelial Cells of Mice as Revealed by Autoradiography". Acta Odont. Scand. 20: 15-30.
- Benacerraf, B., Biozzi, G., Halpern, B.N. (1954): "The Effect of Histamine Upon the Local Fixation of Antibodies in the Skin of the Guinea Pig". J. of Immunol. 73: 318-321.
- Bennick, A. and Hunt, A.M. (1967): "Collagenolytic Activity in Oral Tissue". Arch. Oral Biology 12: 1-9.
- Berlin, B.S. (1966): "Early Antibody Response of Mice Given A Single Injection of Emulsified Influenza Virus Vaccine". J. Immunol. 96: 424-429.
- Beutner, E.H., Triftshauser, C., Nisengard, R. and Drinnan, A.J. (1966): "Gingival Hypersensitivity Reactions: An Experimental Model For Studies of Periodontal Diseases". I.A.D.R. Program Abstracts 44th General Meeting. Abstract #327.
- Bibby, B.G. (1953): "The Role of Bacteria in Periodontal Disease". Oral Surg., Oral Med., Oral Path. 6: 318-327.
- Birn, H. (1966): "The Vascular Supply of the Periodontal Membrane". J. Perio. Research 1: 51-68.
- Boyden, S. (1962): "The Chemotactic Effect of Mixtures of Antibody and Antigen on Polymorphonuclear Leukocytes". J. Exp. Med. 115: 453-466.
- Brandtzaeg, P. (1966): "Local Factors of Resistance in the Gingival Area". J. Perio. Research 1: 19-42.

- Brandtzaeg, P. and Kraus, F.W. (1965): "Autoimmunity in Periodontal Disease". Odont. Tidskrift. 73: 285-393.
- Brandtzaeg, P., Mann, W.V. Jr. (1964): "A Comparative Study of the Lysozyme Activity of Human Gingival Pocket Fluid, Serum and Saliva". Acta Odont. Scand. 22: 441-455.
- Brill, N. (1959): "Removal of Particles and Bacteria From Gingival Pockets by Tissue Fluid". Acta Odont. Scand. 17: 431-440.
- Brill, N. (1962): "The Gingival Pocket Fluid". Acta Odont. Scand. 20: Suppl. 32.
- Brill, N., Bjorn, H. (1959): "Passage of Tissue Fluid Into Human Gingival Pockets". Acta Odont. Scand. 17: 11-21.
- Brill, N., Bronnestam, R. (1960): "Immuno-electrophoretic Study of Tissue Fluid From Gingival Pockets". Acta Odont. Scand. 18: 95-100.
- Burnett, G.W. and Scherp, H.W. (1962): "Oral Microbiology and Infectious Disease". Williams & Wilkins, Baltimore, 2nd Edition.
- Carpenter, P.L. (1965): "Immunology & Serology". W. B. Saunders Co. Second Edition.
- Carranza, F. A., Itoiz, M.E., Cabrini, R.L. and Dotta, C.A. (1966): "Study of Periodontal Vascularization in Different Animals". J. Perio. Research 1: 120-128.
- Chapman, L.F., Goodell, H. (1964): "The Participation of the Nervous System in the Inflammatory Reaction". Ann. N.Y. Acad. Sci. 116: 990-1017.
- Cobb, C.M. and Brown, L.K. (1967): "The Effects of Exudate From the Periodontal Pockets on Cell Culture". Periodontics 5: 5-18.
- Cochrane, C.G. and Weigle, W.O. (1958): "The Cutaneous Reaction to Soluble Antigen-Antibody Complexes. A Comparison With The Arthus Phenomenon". J. Exp. Med. 108: 591-604.
- Cohen, S.G. and Sapp, T.M. (1967): "Experimental Eosinophilia X. Relation of Antigen-Antibody Complex Size and Protein Molecular Weight to Cell Responses". Proc. Soc. Exp. Biol. Med. 124: 1034-1038.
- Congdon, C.C., Makinodan, T. (1961): "Splenic White Pulp Alteration After Antigen Injection. Relation to Time of Serum Antibody Production". Am. J. Path. 39: 697-709.
- Coons, A.H., Kaplan, M.H. (1950): "Localization of Antigen in Tissue Cells II. Improvements in a Method for the Detection of Antigen by Means of Fluorescent Antibody". J. Exp. Med. 91: 1-13.

- Courant, P.R., Paurio, I., Gibbons, R.J. (1965): "Infectivity and Hyaluronidase Activity of Debris from Healthy and Diseased Gingiva". Arch. Oral Biol. 10: 119-125.
- Culling, C.F.A. (1963): "Handbook of Histopathological Techniques". Butterworths, London. Second Edition.
- Deams, W.T. and Oort, J. (1962): "Electron Microscopic and Histochemical Observations on Polymorphonuclear Leukocytes in the Reversed Arthus Reaction". Exp. Cell Res. 28: 11-20.
- DePetris, S., Karlsbad, G. and Pernis, B. (1963): "Localization of Antibodies in Plasma Cells by Electron Microscopy". J. Exp. Med. 117: 849-862.
- Dienstein, B. (1966): "Mast Cells in Gingival Tissue. I. A Standardized Method for Fixing and Staining of the Mast Cell in Human Gingival Tissue". J. Dent. Research 45: 1821.
- Dixon, F.J., Vasquez, J.J., Weigle, W.D. and Cochrane, C.G. (1965): "Pathogenesis of Serum Sickness". Arch. Path. 65: 18-29.
- Egelberg, J. (1963): "Cellular Elements in Gingival Pocket Fluid". Acta Odont. Scand. 21: 283-287.
- Egelberg, J. (1966): "The Blood Vessels of the Dento-Gingival Junction". J. Perio Research 1: 163-179.
- Ehrlich, W.E. (1952): "Nature of Collagen Diseases". Am. Heart J. 43: 121-156.
- Ellison, S.A. (1962): "Tissue Resistance in Periodontal Disease". J. Dent. Research, 41: 279-287.
- Ellison, S.A. and Mandel, T.P. (1963): "Serologic Measures in the Prevention of Periodontal Disease". J. Dent. Research 42: 502-507.
- Fitch, F.W. and Wissler, R.W. (1965): "Histology of Antibody Production". Immunological Diseases. Little Brown & Co. Boston, pp. 65-86.
- Freund, J. and Stone, S.H. (1956): "Arthus Reaction in the Mouse and the Rat After Intralabial Injection of Antigens". J. Immunol. 76: 138-145.
- Gabbioni, G. and Nielsen, K. (1964): "Anaphylactoid Inflammation and Mastopexis". Arch. Path. 78: 626-632.
- Gibbons, R.J. (1964): "Some Aspects of the Bacteriology of Periodontal Disease". Int. Dent. J. 14: 407-410.

- Gomori, G. (1936): "Microtechnical Demonstration of Iron. A Criticism of its Methods". Am. J. Path. 12: 655-663.
- Gorlin, R.J., Stallard, R.E. and Shapiro, B.L. (1967): "Genetics and Periodontal Disease". J. of Periodontology 38: 5-10.
- Gottlieb, B. and Orban, B. (1938): "Biology and Pathology of the Tooth and Its Supporting Mechanism". The MacMillan Co.
- Ham, A.W. "Histology". J. B. Lippencott Company (1957). Third Edition, pp. 232-236.
- Havas, H.F. and Andre, S. (1955): "A Study of the Enhancing Effect of Adjuvants on Antibody Formation in Mice". Brit. J. Exp. Path. 36: 171-174.
- Humphrey, J.H. and White, R.G. (1964): "Immunology for Students of Medicine". Blackwell Scientific Publications, Oxford. Second Edition.
- Jancso, N. (1961): "Inflammation and the Inflammatory Mechanism". J. Pharmacy & Pharmacology 13: 577-594.
- Johnson, C.M., Westwood, J.C.N. and Beaulieu, M. (1964): "A Continuous-Flow Micro Double Diffusion Technique With Cellulose Acetate". Nature 204: 1321-1322.
- Julian, E. (1957): "Can Periodontosis Be Caused by Extrinsic Allergies?" Dent. Abstract 2: 649.
- Kabat, E.A. and Mayer, M.M. (1964): "Experimental Immunochemistry". Charles C. Thomas, Springfield, Illinois. Second Edition.
- Karshan, M. (1952): "Systemic Factors in Periodontal Disease". J.A.D.A. 44: 656-662.
- Kerr, D.A. (1962): "Relations Between Periodontal Disease and Systemic Disease". J. Dent. Research 41: 302-304.
- Kindlova, M. (1967): "Vascular Supply of the Periodontium in Periodontitis". Int. Dent. J. 17: 476-489.
- Leung, S.W. (1962): "The Relation of Calculus, Plaque and Food Impaction to Periodontal Disease". J. Dent. Research 41: 306-311.
- Litt, M. (1964): "Eosinophils and Antigen-Antibody Reactions". Ann. N.Y. Acad. Sciences 116: 964-985.
- Lucas, R.B. and Thonard, J.C. (1955): "The Action of Oral Bacteria on Collagen". J. Dent. Research 34: 118-122.

- McDonald, J.B. and Gibbons, R.J. (1962): "Relationships of Indigenous Bacteria to Periodontal Disease". J. Dent. Research 41: 320-326.
- Mergenhagen, S.E. and DeAraujo, W.C. (1965): "Antibody to Leptotrichia Buccalis in Human Sera". Arch. Oral Biol. 10: 29-33.
- Mergenhagen, S.E. and Rizzo, A.A. (1961): "Allergic Response of Oral Mucosa to Foreign Protein". I.A.D.R. 39th General Meeting, p. 29, Program Abstracts.
- Mergenhagen, S.E., Zipkin, J. and Varah, E. (1962): "Immunological and Chemical Studies on an Oral Veillonella Endotoxin". J. of Immunol. 88: 482-487.
- Mota, I. (1961): "Mechanism of Action of Antigen-Antibody Complexes. Their Effect on Mast Cells". Nature 191: 572-573.
- Mota, I. (1961a): "Mast Cell Lytic Antibodies". Nature 192: 1201.
- Movat, H.Z., Fernando, N.V., Uriuhara, T. and Weiser, W.J. (1963): "Allergic Inflammation. III. The Fine Structure of Collagen Fibrils at Sites of Antibody-Antigen Interaction in Arthus Type Lesions". J. Exp. Med. 118: 557-564.
- Movat, H.Z., Uriuhara, T., Macmorine, D.L. and Burki, J.S. (1964): "A Permeability Factor Released From Leukocytes After Phagocytosis of Immune Complexes and Its Possible Role In the Arthus Reaction". Life Science 3: 1025-1032.
- Mulvihill, J.E., Susi, F.R., Shaw, J.H. and Goldhaber, P. (1967): "Histological Studies of the Periodontal Syndrome in Rice Rats and the Effects of Penicillan". Arch. Oral Biol. 12: 733-741.
- Mustard, J.F. (1964): "Antibody-Antigen Complexes and Platelet Aggregation". Fed. Proc. 23: 548.
- Nossal, G.J.V., Ada, G.L. and Austin, C.M. (1964): "Antigens in Immunity. II. Immunogenic Properties of Flagella, Polymerized Flagellin and Flagellin in the Primary Response." Aust. J. of Exp. Biol. Med. Sci. 42: 283-294.
- Nossal, G.J.V., Mitchell, J. and McDonald, W. (1963): "Single Cell Studies on the Primary Response". Aust. J. Exp. Biol. Med. Sci. 41: 423-436.
- Nossal, G.J.V., Szenberg, A., Oda, G.L. and Austin, C.M. (1964): "Single Cell Studies on 19S Antibody Production". J. Exp. Med. 20: 485-500.
- Novotny, J., Wagner, W., and Maly, V. (1950): "Proof of the Presence of Auto-Antibodies in Cases of Inflammatory Periodontal Disease". Paradontologie 4: 119-127.

- Olson, G.B. and Westman, B.S. (1966): "Cellular and Humoral Immune Response of Germfree Mice Stimulated with 7S, H.G.G. or S. Typhimurium". J. Immunol. 97: 275-286.
- Orban, B.J. (1940): "Eosinophilic Leukocytes in the Pulp and Gingiva". J. Dent. Research 19: 537-543.
- Pearse, A.G.E. (1960): "Histochemistry". J. & A. Churchill Ltd., London, Second Edition, pp. 683-686.
- Platt, D., Crosby, R.G., Dalbow, M.H. (1967): "Studies on Immuno-Unresponsiveness in Mouse Gingival Tissue to a Synthetic Glycoprotein Antigen". I.A.D.R. Program Abstract, 45th General Meeting, Abstract #322.
- Ramfjord, S. (1952): "Local Factors in Periodontal Disease". J.A.D.A. 44: 647-655.
- Rizzo, A.A. and Mergenhagen, S.E. (1964): "Histopathologic Effects of Endotoxins Injected Into Rabbit Oral Mucosa". Arch. Oral Biol. 9: 659-670.
- Rizzo, A.A. and Mergenhagen, S.E. (1965): "Studies on the Significance of Local Hypersensitivity in Periodontal Disease". Periodontics 3: 271-274.
- Rizzo, A.A. and Mitchell, C.T. (1966): "Chronic Allergic Inflammation Induced by Repeated Deposition of Antigen in Rabbit Gingival Pockets". Periodontics 4: 5-10.
- Roseburg, T., MacDonald, J.B., Clark, A.R. (1950): "Bacteria in Periodontal Pockets". J. Dent. Research 29: 718-731.
- Rovin, S., Costich, E.R. and Gordon, H. (1966): "Bacterial Influence in Periodontal Inflammation. A Germfree Study". I.A.D.R. Program Abstracts, 44th General Meeting, Abstract #475.
- Schneider, T.F., Toto, P.D., Garguilo, A.W. (1966): "Specific Bacterial Antibody in the Inflamed Human Gingiva". Periodontics 4: 53-57.
- Schultz-Hautd, S.D. (1964): "Microbiology of Periodontal Disease. Biochemical Aspects of Periodontal Disease". Int. Dent. Journal 14: 398-406.
- Schultz-Hautd, S.D. and Aas, E. (1960): "Observations on the Status of Collagen in Human Gingiva". Arch. Oral Biol. 2: 131-142.
- Schultz-Hautd, S.D. and Lundqvist, L.D.S. (1962): "The Biochemistry of Periodontal Disease". International Dent. Journal 12: 180-193.

- Schultz-Haudt, S.D. and Scherp, H.W. (1955): "Lysis of Collagen by Human Gingival Bacteria". Proc. Soc. Exp. Biol. & Med. 89: 697-700.
- Schultz-Haudt, S.D., Solna, J. (1966): "Dynamics of the Inflammatory Reaction". J. of Perio Research 1: 205-211.
- Schultz-Haudt, S.D., Waerhaug, J., From, S.H., and Altramadol, A. (1963): "On the Nature of Contact Between the Gingival Epithelium and the Tooth Enamel Surface". Periodontics 1: 103-108.
- Schwartz, J., and Vardinon, N. (1966): "In-vitro Prevention of Direct Mast Cell Disruption by Specific Antibody". Int. Arch. Allergy 30: 67-74.
- Seegers, W. and Janoff, A. (1966): "Mediators of Inflammation in Leukocyte Lysosomes VI. Partial Purification and Characterization of a Mast Cell-Rupturing Component". J. Exp. Med. 124: 833-849.
- Shaw, J.H. (1962): "The Relation of Nutrition to Periodontal Disease". J. Dent. Research 41: 264-274.
- Silverstein, A.M. and Prendergast, R.A. (1963): "What Is Immunologic Competence? An Attempt to Find the Attributes of Immunologically Functioning Cells". Blood 22: 770-774.
- Siqueira, M. and Nelson, R.A. Jr. (1961): "Platelet Agglutination By Immune Complexes and Its Possible Role in Hypersensitivity". J. Immunol. 86: 516-525.
- Smart, J.V. (1963): "Elements of Medical Statistics". Staples Press, London, First Edition.
- Smith, D.J. (1962): "The Chemical Structure of the Periodontium". J. Dent. Research 41: 250-258.
- Sorrin, S. (1960): "The Practice of Periodontics". McGraw-Hill Book Co. Inc.
- Spouge, J.D. and Cutler, B.S. (1963): "Hypersensitivity Reactions in Mucous Membranes". Oral Surg., Oral Med., Oral Path. 16: 539-550.
- Stavitsky, A.B. (1954): "Procedure and General Applications of Hemagglutination and Hemagglutination-Inhibition Reactions With Tannic Acid and Protein Treated Red Blood Cells". J. Immunol. 72: 360-367.
- Stetson, C.A. (1951): "Similarities in the Mechanisms Determining the Arthus and Shwartzman Phenomena". J. Exp. Med. 94: 347-358.

- Stetson, C.A. and Good, R.A. (1951): "Studies on the Mechanism of the Shwartzman Phenomenon. Evidence for the Participation of Polymorphonuclear Leukocytes in the Phenomenon". J. Exp. Med. 93: 49-64.
- Stirn, B.D. (1967): "Collagen Solubility of Normal and Inflamed Human Gingiva". Periodontics 5: 167-171.
- Taichman, N.S., Freedman, H.L. and Uriuhara, T. (1966): "Inflammation and Tissue Injury. I. The Response to Intradermal Injections of Human Dento-Gingival Plaque in Normal and Leukopenic Rabbits". Arch. Oral Biol. 2: 1385-1392.
- Terner, C. (1965): "Arthus Reaction in the Oral Cavity of Laboratory Animals". Periodontics 3: 18-22.
- Thonard, J.C., and Dalbow, M.H. Jr. (1965): "Local Cellular Antibodies. I. Plaque Formation by Sensitized Oral Mucosa Cells From Conventional Animals". J. of Immunol. 95: 209-213.
- Triftshauer, C., Beutner, E.H. and Hagen, S.P. (1966): "Studies of a Collagenase-Like Enzyme Found in Human Gingival Tissues". I.A.D.R. Program Abstracts, 44th General Meeting, Abstract #325.
- Trott, J.R. and Gorenstein, S.L. (1963): "Mitotic Rates in the Oral and Gingival Epithelium of the Rat". Arch. Oral Biol. 8: 425-434.
- Uriuhara, T. and Movat, H.Z. (1964): "Allergic Inflammation IV. The Vascular Changes During the Development and Progression of the Direct Active and Passive Arthus Reactions". Lab. Investigation 13: 1057-1079.
- Vasquez, J.J. and Makinodan, T. (1966): "Cytokinetic Events Following Antigen Stimulation". Fed. Proc. 25: 1727-1733.
- Waerhaug, J. (1966): "Anatomy, Phsyiology, and Pathology of the Gingival Pocket". Revue Belge de Medécine Dentaire 21: 9-15.
- Waerhaug, J. (1967): "Current Basis for Prevention of Periodontal Disease". Int. Dent. Journal 17: 267-281.
- Ward, P.A., Cochrane, C.G. (1964): "A Function of Bound Complement in the Development of Arthus Reactions". Fed. Proc. 23: 509.
- Wasi, S., Murray, R.K., MacMorraine, D.R. and Movat, H.Z. (1966): "Studies on the Proteolytic Activity of PMN-Leukocyte Lysosomes of the Rabbit". Br. J. Exp. Path. 47: 411-423.
- Wakesman, B.H. (1960): "The Distribution of Experimental Auto-Allergic Lesions". Am. J. Path. 37: 673-693.
- Weinman, J.P. (1941): "Progress of Inflammation Into the Supporting Structures of the Teeth". J. Periodontology 12: 71-82.

- Wellensiek, H.J. and Coons, A.H. (1964): "Studies on Antibody Production. IX. The Cellular Localization of Antigen Molecules (Ferritin) in the Secondary Response". J. Exp. Med. 119: 685-696.
- Wheatcroft, M.G. (1957): "A Comparative Study of Human Serum and Salivary Antibody Titres in Cases of Brucella Melitensis Infection". J. Dent. Res. 36: 112-117.
- Winer, R.A., Cohen, M.M., and Chauncey, H.H. (1967): "Antibiotic Therapy in Periodontal Disease". Dental Abstracts 12: 307.