

Dentin Preservation in the pericervical area after preflaring with Gates-Glidden or X-Gates drills. An ex vivo micro CT study.

Bryan Wong BSc (Dent) ¹; Rene Chu DDS MSc ²; Isabel Mello DDS MSc PhD³; Luciana Louzada Ferreira DDS MSc PhD²; Aldo de Carpio-Perochena DDS MSc PhD²; Rodrigo Sanches Cunha DDS MSc PhD ²

1- BSc (Dent) student, College of Dentistry, University of Manitoba, Canada

2- Division of Endodontics – College of Dentistry, University of Manitoba, Canada

3- Division of Endodontics – Dallhousie University , Canada

Abstract

Introduction: This study compared the dentin preservation in the distal wall of mesial canals in mandibular molars after preflaring with X-Gates (XG, Dentsply Tulsa Specialities, Tulsa, OK) or Gates-Glidden (GG) drills (Dentsply Tulsa Specialites). **Methods:** Sixty mesial canals of mandibular molars were evenly allocated into two balanced groups for preflaring procedures: group XG – canals were preflared with a single XG drill or group GG - Drill series (n.1, 2, 3 and 4). With the aid of a micro-computed tomography scanner, dentin removal towards the furcation was measured at 3 levels: furcation (0 mm), 1mm, and 2mm apically. A paired *t*-test was performed to assess differences before and after procedures in the same group and one-way ANOVA was performed to assess differences between the groups. **Results:** Significant decrease in dentin thickness was found in the distal area of mesial roots after preflaring procedures in both groups ($P < .0001$). No significant difference ($P > .05$) was observed between XG and GG with regard to dentin preservation. Regarding the level where preflaring was done, significant difference ($P < .05$) was only detected in the mean values of dentin thickness between 0 mm (411.6 μ m) and 2mm (251.4 μ m) in the XG group. **Conclusion:** Both XG and GG groups resulted in significant decrease in dentin thickness but no difference was observed between the XG drill group and GG drill group in dentin removal towards the “danger zone”.

Introduction


Traditionally, an important factor to a successful endodontic treatment is appropriate coronal flaring of the canal to achieve a straight-line access. Straight-line access to the apical region is important for both operator control and instrumentation.^{1,2} By enlarging the coronal third, it allows for better penetration of irrigating solutions^{1,3}. Appropriate canal flaring will also allow better access for spreader/plugger penetration and ultimately result in a better obturation.⁴

While there are numerous benefits to flaring the canal, there has been a shift in dentistry and endodontics to a greater emphasis on minimally invasive treatment. Gluskin et al. emphasizes that endodontics should be performed in a manner that causes the least amount of change in the dental hard tissues. This preserves the strength and function of endodontically treated teeth.⁵ Krishan et al. compared a traditional molar access with a more minimally invasive access and found that less dentin removal resulted in a greater fracture resistance.⁶ Furthermore, over-cutting the circumference within molars in the “danger zone” of the root canal walls can cause stripping or perforations.⁷ The “danger zone” of mandibular molars have been repeatedly shown to be the distal surface of a mesial root.^{8,9,10} These perforations negatively affect the prognosis of the tooth and can lead to pain, sensitivity, chronic inflammation and exudate potentially requiring either non-surgical or surgical repair.¹¹ Another consequence of excessive dentin removal during treatment can result in vertical root fractures due to excessive forces such as in chewing or in the obturation stage from forces generated in vertical and lateral condensation.^{12,13,14}

Historically, the common instrument of choice for the flaring and preparing of the coronal portion is the Gates-Glidden series. Typically, the Gates-Glidden drills are six burs used together to create the flared access. In 2005, Dentsply Tulsa Dental Specialties (Tulsa, OK, USA) have released a single drill for the purpose of coronal flaring named “X-Gates drill”. The manufacturer states that the X-Gates can replace the Gates-Glidden #1-4 for the purpose of creating radicular access.¹⁵ This creates several advantages as a single bur would make the process of coronal flaring more convenient and less time consuming. Furthermore, a single bur could be more conservative as less cutting strokes would be required. To date, there has been no study designed to assess the efficacy of the X-gates compared to the Gates-Glidden drills in coronal flaring.

This study aims to compare the dentin removal in the “danger zone” during coronal flaring between the X-Gates and Gates-Glidden series though micro-CT imaging.

Figure 1. Scanning Electron Microscope image of X-Gates and Gates-Glidden #2.



Materials and Methods

This study was approved by the University of Manitoba Health Research Ethics Board (protocol number H2014:120).

Sample Selection and Preparation

Using statistical power analysis, the sample size for the number of teeth was determined for each group. It was generated using a standard significance level of 0.05, effect magnitude of 0.8 and power magnitude of 0.9.

Thirty extracted mandibular molars were used in this study. The teeth were screened radiographically and stored in distilled water. Inclusion criteria stipulated that teeth must have fully formed roots, two separate canals in the mesial root classified as Weine type II or type III, and no previous endodontic treatment. Coronal access was performed in conventional manner using a #4 round bur and Endo Z bur (Dentsply Tulsa Dental Specialties). Each canal was negotiated with a #10 K-File to working length to ensure burs would be able to reach minimum penetration depth. Flores et al. determined minimum penetration depth to be 2mm apical to the furcation.¹⁹ The mesial canals were randomly distributed into two groups using a computer algorithm (<http://www.random.org>). The first to be instrumented by the Gates-Glidden bur (GG group) and the other instrumented by the X-Gates Bur (XG group). A pre-instrumentation micro-CT scan was taken at this point. The GG group canals were instrumented using Gates-Glidden #1-4 and the XG group was instrumented by the X-Gates bur to minimum penetration depth following manufacturer's instructions. To ensure that burs would appropriately reach the minimum penetration depth, rubber stops were set so that burs could engage 2mm apical to the furcation based on micro-CT measurements.

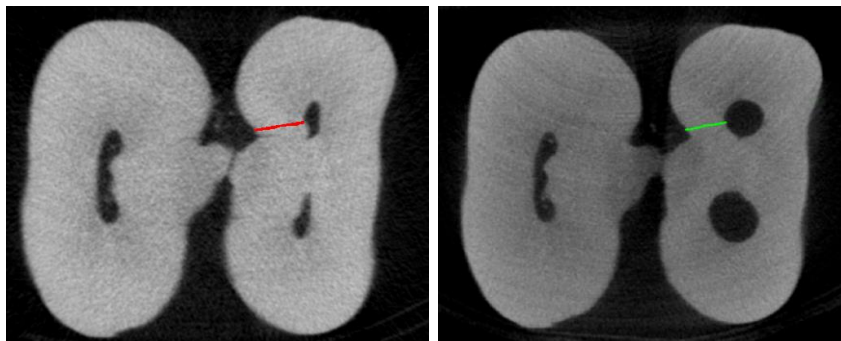
Micro-CT Analysis

Before scanning, individual custom jigs were fabricated to ensure that specimens were able to be scanned in the exact same position for pre- and postinstrumentation. Micro-CT imaging was performed to allow for non-destructive, quantitative assessment of the effects of instrumentation at the level of furcation and at the 1mm and 2mm section. The SkyScan 1176 micro-CT system (Bruker Micro-CT, Bruker, Aartselaar, Belgium) was used to scan all teeth and parameters were kept constant for both pre- and postinstrumentation scans (parameters: source voltage: 80 kV, current 313 μ a, resolution, filter, exposure time, rotation step, 360 acquisition, reconstruction reduction factor and beam hardening).

Direct comparison of equivalent pre- and postinstrumentation images allows for quantitative assessment of dentin thickness in the distal direction (towards the “danger zone”). There are three slices of interest for this study: at the level when the furcation is no longer visible (0mm mark), at 1mm (56 slices apical), and at 2mm (112 slices apical).

One examiner, blinded to which canals belonged to each group took measurements from cross sectional images using DataViewer (Skyscan). The method of determining measurements used was adapted by Gergi et al., which measured the shortest distance from the periphery of the canal to the periphery of the root. From the examiners measurements, the final mean values for remaining dentin thickness and dentin removal were calculated.²¹

Figure 2. Images taken from DataViewer illustrating method for measurement of dentin thickness on Micro-CT scans.



Statistical Analysis

The Student's *t*-test was used to assess significant differences between GG and XG groups in mean remaining dentin thickness and mean dentin removal with significance set at $P < .05$. A one-way analysis of variance was used to compare differences in dentin thicknesses within each group.

Results

Significant decrease in dentin thickness was found in the direction towards the furcation after preflaring procedures in both groups ($P < .0001$, Table 1).

Table 1. Mean values in dentin thickness (in μm) and standard deviation (SD) towards the furcation before and after preflaring with either Gates-Glidden or X-Gates at 0, 1, and 2mm from the orifice. Different lower case letters in the same row and within the same group denotes statistical difference (paired *t*-test, $P < .0001$).

<i>Level</i>	<i>Group</i>			
	Gates Glidden		X-Gates	
	Mean \pm SD		Mean \pm SD	
	Before	After	Before	After
<i>0mm</i>	1381.5 \pm 272.8 ^a	1058.3 \pm 343.2 ^b	1365.6 \pm 272.8 ^a	954 \pm 333.4 ^b
<i>1mm</i>	1149.6 \pm 205.9 ^a	775 \pm 309.7 ^b	1180.5 \pm 191.2 ^a	764.9 \pm 343.7 ^b
<i>2mm</i>	1107.7 \pm 240.4 ^a	827.7 \pm 381 ^b	1092.7 \pm 238.2 ^a	841.3 \pm 372.3 ^b
<i>Total</i>	1212.9 \pm 239.7 ^a	887 \pm 344.3 ^b	1212.9 \pm 234.1 ^a	853.4 \pm 349.8 ^b

Comparison in the difference of dentin thickness (before minus after) between the two groups did not demonstrate statistical difference ($P > 0.05$). When comparing the different levels (0, 1, and 2mm) within the same group, statistical difference were found only in the X-Gates group between 0 and 2mm and between 1 and 2mm ($P < .05$, Table 2).

Table 2. Comparisons of the mean values of difference in dentin thickness (before minus after preflaring in um) at 0, 1, and 2mm from the orifice after preflaring of the root canal with either Gates Glidden or X-Gates. A *t*-test between the groups ($P > .05$) and different lower case letters in the same row denote statistical difference (One-way ANOVA among the levels, $P < .05$).

<i>Level</i>	<i>Group</i>	
	Gate Glidden	X-Gates
	Mean of difference	
<i>0mm</i>	323.2 ^a	411.6 ^a
<i>1mm</i>	374.7 ^a	415.6 ^{ab}
<i>2mm</i>	280 ^a	251.4 ^c

Discussion

Previous research studies have evaluated the need for minimally invasive access.⁶ Excessive removal of the coronal third compromises a tooth's maximal resistance to flexure and ultimately results in failure. It has been suggested that maintenance of the peri-cervical dentin (PCD) is critical for the long term survivability and optimum function . For that reason, Gluskin et al. further recommends that the use of Gates Glidden and round burs be discouraged.⁵

The X-Gates has been promoted to replace Gates-Glidden #1-4 drills with an ability to create a safe straight line radicular access.¹⁵ As a result, it was selected for this study to determine whether it can produce a more conservative access than the traditional Gates-Glidden

The research model had an X-gates group and Gates Glidden group instrument mandibular first molars with separate canals in the mesial root (Weine type II or III). Due to the similar root canal morphology, this design allowed for the side by side comparison of the two . The method of image acquisition selected was micro-CT imaging. This image modality produces high resolution and quantifiable

data. Combined with custom fabricated jigs, direct comparison of the pre- and postinstrumentation slides were possible in a non-destructive manner.^{22, 23, 24}

Both X-Gates and Gates-Glidden groups showed a significant removal of dentin when comparing pre- and postinstrumentation. This is consistent with other studies which analyzed the magnitude of removal in preflaring instruments.^{19, 20} No significant differences were observed between X-Gates and Gates-Glidden in dentin removal. The remaining dentin thickness postinstrumentation was found to range from 1058.3µm to 775µm, which are consistent with other studies following a similar methodology.^{16, 17}

Analysis was done within each group to detect if there would be a significant difference in the amount of removal at each millimeter increment. There were no significant differences found in the Gates-Glidden group. A significant difference was seen in the X-gates group between the 0mm and 2mm. This suggests that the X-Gates cuts in a more tapered shape when compared to the parallel shape of the Gates-Glidden. This could be attributed to using a single bur when preflaring with the X-Gates whereas with the Gates-Glidden series, changing burs and repeated cutting results in a more parallel dentin removal.

While the results obtained in this study showed no significant difference observed between the X-gates group and Gates-Glidden group with regards to dentin removal towards the “danger zone”, the continued use of Gates-Glidden may be questioned. Studies on alternative instruments such as orifice modifiers have shown promising data^{25, 26} but more research on minimally invasive instruments is required.

Acknowledgements

The authors would like to thank the Canadian Academy of Endodontist for their gracious support of this study. The authours would also like to acknowledge Mike Jackson for his assistance in CT Imaging.

The authors deny any conflict of interest related to this study.

References

1. Goerig AC, Michelich RJ, Schultz HH. [Instrumentation of root canals in molar using the step-down technique](#). J Endod. 1982 Dec;8(12):550-4.
2. Leeb J. [Canal orifice enlargement as related to biomechanical preparation](#). J Endod. 1983 Nov;9(11):463-70.
3. Ram Z. [Effectiveness of root canal irrigation](#). Oral Surg Oral Med Oral Pathol. 1977 Aug;44(2):306-12.
4. Allison DA, Weber CR, Walton RE. [The influence of the method of canal preparation on the quality of apical and coronal obturation](#). J Endod. 1979 Oct;5(10):298-304.
5. Gluskin AH, Peters CI, Peters OA. [Minimally invasive endodontics: challenging prevailing paradigms](#). Br Dent J. 2014 Mar;216(6):347-53.
6. Krishan R, Paqué F, Ossareh A, Kishen A, Dao T, Friedman S. [Impacts of conservative endodontic cavity on root canal instrumentation efficacy and resistance to fracture assessed in incisors, premolars, and molars](#). J Endod. 2014 Aug;40(8):1160-6
7. Abou-Rass M, Jastrab RJ. [The use of rotary instruments as auxiliary aids to root canal preparation of molars](#). J Endod. 1982 Feb;8(2):78-82.
8. Abou-Rass M, Jann JM, Jobe D, Tsutsui F. [Preparation of space for posting: effect on thickness of canal walls and incidence of perforation in molars](#). J Am Dent Assoc. 1982 Jun;104(6):834-7.
9. Kessler JR, Peters DD, Lorton L. [Comparison of the relative risk of molar root perforations using various endodontic instrumentation techniques](#). J Endod. 1983 Oct;9(10):439-47.
10. Wu MK, van der Sluis LW, Wesselink PR. [The risk of furcal perforation in mandibular molars using Gates-Glidden drills with anticurvature pressure](#). Oral Surg Oral Med Oral Pathol Oral Radiol Endod. 2005 Mar;99(3):378-82.
11. Alhadainy HA. [Root perforations. A review of literature](#). Oral Surg Oral Med Oral Pathol. 1994 Sep;78(3):368-74.
12. Wilcox LR, Roskelley C, Sutton T. [The relationship of root canal enlargement to finger-spreader induced vertical root fracture](#). J Endod. 1997 Aug;23(8):533-4.
13. Barreto MS, Moraes Rdo A, Rosa RA, Moreira CH, Só MV, Bier CA. [Vertical root fractures and dentin defects: effects of root canal preparation, filling, and mechanical cycling](#). J Endod. 2012 Aug;38(8):1135-9.

14. Meister F Jr, Lommel TJ, Gerstein H. [Diagnosis and possible causes of vertical root fractures](#). Oral Surg Oral Med Oral Pathol. 1980 Mar;49(3):243-53.
15. Dentsply Tulsa. Access Kits[Internet]. Dentsply International Inc; 2007. Available from: http://www.tulsadentalspecialties.com/Libraries/Tab_Content__Endo_Access_Shaping/BREA_0308_Endo_Access_Kit_Broch_FINAL_0308.sflb.ashx
16. Mahran AH, AboEl-Fotouh MM. [Comparison of effects of ProTaper, HeroShaper, and Gates Glidden Burs on cervical dentin thickness and root canal volume by using multislice computed tomography](#). J Endod. 2008 Oct;34(10):1219-22.
17. Sanfelice CM, da Costa FB, Reis Só MV, Vier-Pelisser F, Souza Bier CA, Grecca FS. [Effects of four instruments on coronal pre-enlargement by using cone beam computed tomography](#). J Endod. 2010 May;36(5):858-61.
18. Duarte MA, Bernardes RA, Ordinola-Zapata R, Vasconcelos BC, Bramante CM, Moraes IG. [Effects of Gates-Glidden, LA Axxess and orifice shaper burs on the cervical dentin thickness and root canal area of mandibular molars](#). Braz Dent J. 2011;22(1):28-31.
19. Flores CB, Montagner F, Gomes BP, Dotto GN, da Silva Schmitz M. [Comparative assessment of the effects of Gates-Glidden, Largo, LA-Axxess, and New Brazilian Drill CPdrill on coronal pre-enlargement: cone-beam computed tomographic analysis](#). J Endod. 2014 Apr;40(4):571-4.
20. Sousa K, Andrade-Junior CV, da Silva JM, Duarte MA, De-Deus G, da Silva EJ. [Comparison of the effects of TripleGates and Gates-Glidden burs on cervical dentin thickness and root canal area by using cone beam computed tomography](#). J Appl Oral Sci. 2015 Mar-Apr;23(2):164-8.
21. Gergi R, Rjeily JA, Sader J, Naaman A. [Comparison of canal transportation and centering ability of twisted files, Pathfile-ProTaper system, and stainless steel hand K-files by using computed tomography](#). J Endod. 2010 May;36(5):904-7
22. Rhodes JS, Ford TR, Lynch JA, Liepins PJ, Curtis RV. [Micro-computed tomography: a new tool for experimental endodontology](#). Int Endod J. 1999 May;32(3):165-70.
23. Peters OA, Laib A, Göhring TN, Barbakow F. [Changes in root canal geometry after preparation assessed by high-resolution computed tomography](#). J Endod. 2001 Jan;27(1):1-6.
24. Bergmans L, Van Cleynenbreugel J, Wevers M, Lambrechts P. [A methodology for quantitative evaluation of root canal instrumentation using microcomputed tomography](#). Int Endod J. 2001 Jul;34(5):390-8.

25. Hervás A, Forner L, Llena C, Zaragoza E. [Evaluation of morphological changes produced by orifice opener systems using computerized tomography \(CT\)](#). Med Oral Patol Oral Cir Bucal. 2009 Dec 1;14(12):e674-9
26. Akhlaghi NM, Bajgiran LM, Naghdi A, Behrooz E, Khalilak Z. [The minimum residual root thickness after using ProTaper, RaCe and Gates-Glidden drills: A cone beam computerized tomography study](#). Eur J Dent. 2015 Apr-Jun;9(2):228-33.