

Ventrolateral partial dorsal root entry zone rhizotomy for occipital neuralgia

Serge Rasskazoff MD FICS, Anthony M Kaufmann MD MSc BSc (Med) FRCSC

S Rasskazoff, AM Kaufmann. Ventrolateral partial dorsal root entry zone rhizotomy for occipital neuralgia. *Pain Res Manage* 2005;10(1):43-45.

OBJECTIVE AND IMPORTANCE: Medically refractory occipital neuralgia (ON) has been treated with a variety of neuroablative procedures. The present case report supports the effectiveness of ventrolateral partial rhizotomy (pVL-DREZ) of the C1 to C3 cervical dorsal roots, a relatively unknown procedure.

CLINICAL PRESENTATION: A 46-year-old woman had a 14-month history of severe right-sided ON. Multiple trials of medical treatments, nerve blocks and local steroid injections had failed. Her daily opioid requirements had escalated to include frequent injections in addition to prescribed oral opiates.

INTERVENTION AND RESULTS: A pVL-DREZ at the right C1 to C3 level was performed through a C1 laminectomy and C2 right laminotomy. The ipsilateral upper cervical dorsal roots were exposed and a 1 mm deep incision was made at a 45° angle to the sagittal midline at the ventrolateral aspect of each dorsal rootlet entry. The patient experienced postoperative opioid withdrawal seizure and transient disequilibrium for two weeks. Touch sensation was preserved and complete abolition of ON over a four year follow-up was achieved.

CONCLUSION: The pVL-DREZ procedure provided complete pain relief for the patient and avoided the potential complications often encountered with other destructive interventions. pVL-DREZ should be considered among the available options for the treatment of refractory ON.

Key Words: DREZ; Occipital neuralgia

Occipital neuralgia (ON) is a radiculopathic condition characterized by paroxysmal lancinating pains in the distribution of the greater or lesser occipital nerves (1). The disease course may be self-limited or progressive. Treatment algorithms usually begin with analgesics and nonsteroidal anti-inflammatories. An advanced pharmaceutical treatment typically includes oral administration of carbamazepine and gabapentin in an escalating fashion until pain control is achieved or intolerable side effects develop. Some patients, however, become disabled by unrelenting and severe ON. Diagnostic anesthetic blocks of the peripheral occipital nerves are useful to confirm the diagnosis and provide temporary pain relief. Repeated steroid injections may provide long-term pain control (2-4). For patients with intractable ON pain, a variety of ablative procedures are often considered. These include peripheral neurectomy, C2 ganglionectomy by surgery or radiofrequency and intradural rhizotomy (5-9). In selected

Une zone d'entrée par la racine dorsale ventrolatérale partielle pour une névralgie occipitale

OBJECTIF ET IMPORTANCE : La névralgie occipitale (NO) réfractaire aux médicaments a été traitée à l'aide de diverses interventions neuroablatives. Le présent rapport de cas étaye l'efficacité de la rhizotomie ventrolatérale partielle (pVL-DREZ) des racines dorsales cervicales C1 à C3, une intervention relativement inconnue.

PRÉSENTATION CLINIQUE : Une femme de 46 ans souffrait d'une grave NO droite depuis 14 mois. De nombreux essais de traitements médicaux, d'anesthésie tronculaire et d'injections locales de stéroïdes avaient échoué. Les besoins quotidiens en opiacés de la femme avaient augmenté au point d'inclure de fréquentes injections en plus des opiacés prescrits par voie orale.

INTERVENTION ET RÉSULTATS : Une pVL-DREZ au niveau du C1 à C3 a été exécutée au moyen d'une laminectomie C1 et d'une laminotomie C2 droite. Les racines dorsales supérieures ipsilatérales ont été exposées, et une incision de 1 mm a été exécutée à un angle de 45° du plan médian sagittal à l'aspect ventrolatéral de chaque zone d'entrée de la racine dorsale. La patiente a souffert de convulsions de sevrage postopératoires et d'un déséquilibre transitoire pendant deux semaines. Elle a conservé la sensation du toucher et a bénéficié d'une disparition complète de la NO, observée dans le cadre d'un suivi de quatre ans.

CONCLUSION : La pVL-DREZ a assuré un soulagement complet de la douleur à la patiente et lui a permis d'éviter les complications potentielles souvent observées avec d'autres interventions destructrices. La pVL-DREZ devrait être envisagée parmi les possibilités de traitement d'une NO réfractaire.

cases caused by C1 to C2 arthrosis, foraminal decompression of the C2 nerve root and ganglion have been effective (4,9-11), while occipital nerve stimulator implants have been successful in others (12).

Sindou (13) first reported a microsurgical approach to the dorsal root entry zone (DREZ). The goal of this technique is the specific destruction of the small, unmyelinated fibres that enter the substantia gelatinosa of the spinal gray matter dorsal horn. Microsurgical DREZ has been successfully applied for treatment of localized pain associated with cancer (14), neuropathic pain from brachial plexus avulsion, cauda equine and spinal cord lesions, peripheral nerve injury, herpes zoster (15) and amputation stump pain (16). Dubuisson (17) described an application of DREZ for the surgical treatment of ON involving sectioning of the ventrolateral aspect of each posterior rootlet of C1 to C3 at the root entry zone. He provided a neuroanatomically sensible rationale and reported a high success rate in this single case series. As a follow-up

Section of Neurosurgery, Department of Surgery, University of Manitoba, Health Sciences Centre, Winnipeg, Manitoba

Correspondence and reprints: Dr Anthony M Kaufmann, GB 137 Section of Neurosurgery, Department of Surgery, University of Manitoba, Health Sciences Centre, 820 Sherbrook Street, Winnipeg, Manitoba R3A 1R9. Telephone 204-787-7263, fax 204-783-7356, e-mail akaufmann@hsc.mb.ca

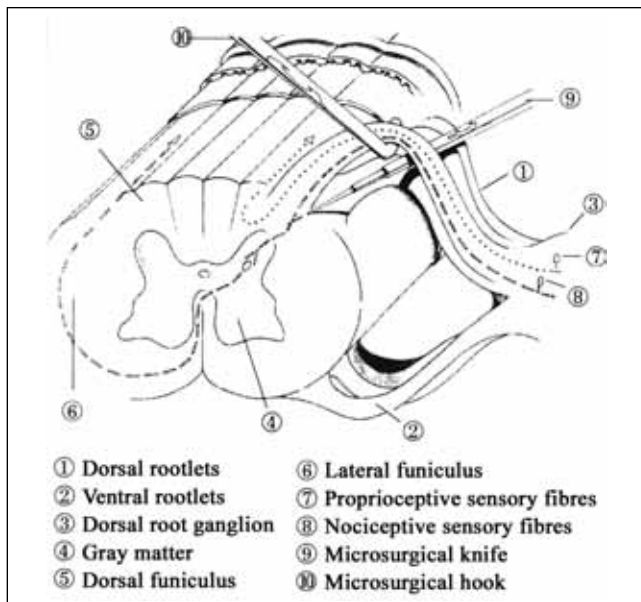


Figure 1) Cross-section of the spinal cord at the cervical level featuring the site of surgical ablation

to Dubuisson's promising findings, we present a case of medically refractory ON treated by ventrolateral partial rhizotomy (pVL-DREZ) of the ipsilateral C1 to C3 cervical dorsal roots. A 48-month, long-term outcome is included.

CLINICAL PRESENTATION

A 46-year-old woman presented with a progressive history of severe right-sided ON over 14 months. Her past medical history was remarkable for a whiplash injury at 18 years of age and right-sided migraine headaches, without recent episode. The onset of ON pain followed a viral type illness with nausea, vomiting and 'plugged ears'. The ON pain radiated along the greater occipital nerve territory and was associated with periorbital and right temporal pain. The pain had become virtually constant and the superimposed lancinating attacks continued. The pain could be triggered by pressure along the great occipital nerve course. She denied any subjective numbness or dysesthesia of the scalp, although examination revealed slightly reduced pinprick sensation of the great occipital nerve distribution of the right side. There were no other neurological complaints or deficits. Investigations were normal, including cervical X-rays, computed tomography of the head and magnetic resonance imaging (MRI) of the head and neck. She had tried various medical therapies, including anticonvulsants (Epival [Abbott, Canada] and Tegretol [Novartis Pharmaceuticals, USA]) and topical drugs (capsaicin and ketamine), with little benefit. Local injections of anesthetic agents and steroids provided very short-term relief for only few hours. Her prescribed oral opiates required supplementation with frequent medically administered opioid injections.

INTERVENTION

The authors' experience with the treatment of ON was limited, with no prior performance of open surgical procedures for patients with ON. Several treatment options were considered for the patient, and pVL-DREZ of the right C1 to C3 dorsal roots, as described by Dubuisson (17), was elected. The procedure also offered the possibility of avoiding potential complications of

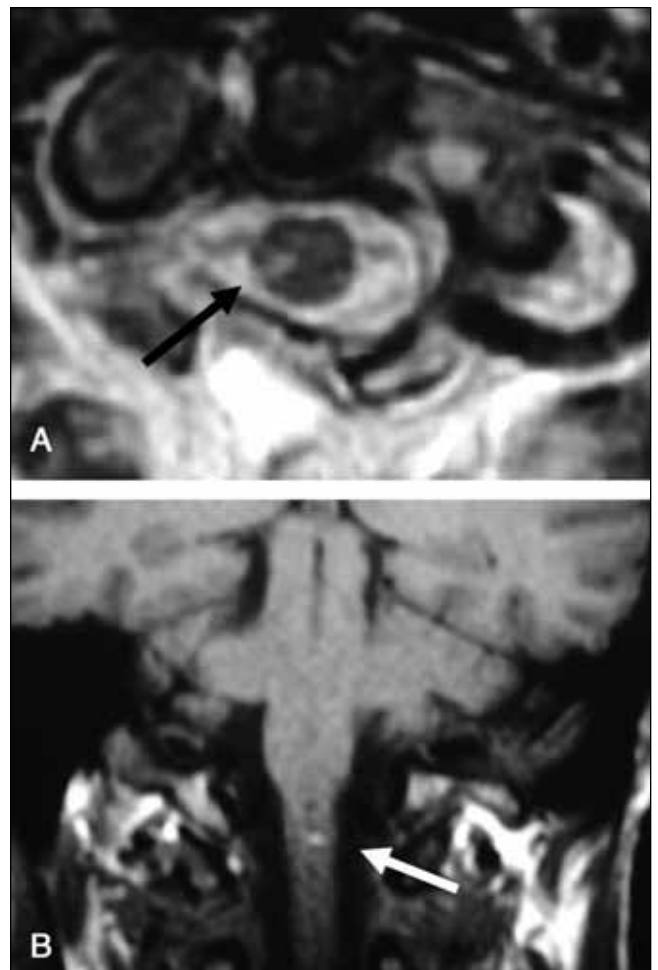


Figure 2) The T-2 weighted axial (A) and T-1 weighted coronal (B) magnetic resonance images showing the postoperative signal change in the cervical cord, representing edema and possible microhemorrhage at one of the ventrolateral partial rhizotomy lesion sites. The associated deficits were mild and the patient recovered

complete deafferentation. The option of occipital nerve stimulation was not available at the time of the patient's presentation, nor were the long-term outcome results of pVL-DREZ.

Through a C1 laminectomy and C2 right laminotomy, the ipsilateral upper cervical dorsal roots were exposed. A 1 mm deep incision was made at a 45° angle to the sagittal midline at the ventrolateral aspect of each dorsal rootlet entry: 3 at C1, 4 at C2, and 3 at C3 (Figure 1). A single C2 dorsal rootlet was sectioned due to the close proximity of a small artery intimately associated with the ventrolateral aspect of the root entry point.

OUTCOME

Postoperatively, there were no further episodes of ON and only a partial, mild numbness in the greater occipital nerve distribution. There was some new disequilibrium that resolved over two weeks, and some intermittent subjective mild right arm numbness and fatigability, yet, no objective indications were evident. An MRI of the cervical spine identified a small area of edema or injury, which was thought to account for these symptoms (Figure 2). Her incisional pain and generalized postoperative headache were treated with modest and tapering doses of intravenous morphine and Tylenol No 3 with Codeine

(Janssen-Ortho/McNeil Consumer Healthcare, Canada). Despite the fact that laboratory investigations and an MRI of her brain were normal, on postoperative day 6 the patient suffered a cluster of brief, generalized seizures. These seizures were attributed to withdrawal from high-dose opioids. The pain service prescribed a higher dose of opioids to be tapered over several weeks; in turn, anticonvulsants were not required.

At the time of her three month follow-up visit, the patient had not experienced any further seizures or symptoms of disequilibrium. She was free of ON pain and did not require analgesics. She reported mild subjective scalp numbness, yet still managed to identify light touch and hair movement sensations. Her intermittent arm symptoms had improved, although not completely, and she had resumed a full range of strenuous activities. A 48-month telephone follow-up revealed that she had remained free of ON pain and had not experienced any further arm symptoms or seizures. She no longer required pain medications.

DISCUSSION

Occipital nerves have a unique course, rendering them susceptible to compression or injury at the neural foramen or transmuscular course (18). Known causes of ON include acute or chronic trauma and entrapment or inflammation at any point along the course of the C2 or C3 nerves, although in the majority of cases, there are no identifiable causes (1). Medical treatment of ON includes trials of anticonvulsants, steroids, topical medications, and steroid or neurolytic injections of the occipital nerves or C2 root and ganglion. Common surgical treatment options for intractable ON include a variety of peripheral ablation procedures that have potential disadvantages, including the complete loss of scalp sensation, severe vertigo due to the loss of proprioceptive sensation of upper cervical facets and anesthesia dolorosa.

Dubuisson (17) described the treatment of 11 ON patients by partial posterior rhizotomy at the C1 to C3 level and applying the microsurgical technique of partial posterior rhizotomy first described by Sindou and colleagues (19). Organization of somatic sensory processing within the spinal segment allows for the relief of pain while preserving touch and proprioceptive sensation. Large-diameter axons that mediate touch and limb position enter dorsomedially to the more ventrolateral small-diameter nociceptive axons. Use of this anatomical nuance has allowed the development of selective partial posterior rhizotomy, dividing only the ventrolateral portion of each sensory rootlet at the dorsal root entry zone. Interruption of nociceptive fibre tracts of Lissauer is achieved by placing multiple lesions at the ventrolateral junction of the dorsal rootlet and the spinal cord (Figure 1). The pVL-DREZ is produced with a microsurgical blade advanced at a 45° angle from the sagittal plane to a depth of 1 mm. This provides an anatomically sensible approach for the treatment of ON by preserving proprioceptive sensory fibres coursing along the dorsal aspect of the nerve and minimizing risks of postoperative vertigo and scalp numbness.

Moreover, in Dubuisson's series of 11 patients (17), seven had excellent results (pain free with no medications) and three had good results (greater than 50% pain relief with medications) over follow-up periods ranging from three to 66 months. There are no other published reports of pVL-DREZ for ON treatment. The patient in our case report enjoyed complete and lasting pain relief following the pVL-DREZ over a four-year follow-up period (to date). The potential of cord injury was also highlighted by a

transient subjective deficit and MRI-defined injury, although the low risk associated with DREZ procedures has been quite well-established (20).

CONCLUSION

In summary, a case report of medically intractable ON successfully treated using a pVL-DREZ at the C1 to C3 level is presented. The patient reported complete long-term pain relief with preservation of gross sensation and without permanent neurological complications. This procedure may be considered as an alternative to other neuroablative interventions or occipital nerve stimulation for severe and medically refractory ON.

ACKNOWLEDGEMENTS: We thank Jon Stepaniuk for creating the illustration in Figure 1, and Ms Heather Long and Mrs CJ Byrnes for their assistance in the preparation of the manuscript.

REFERENCES

- Hagen N, Kaufmann AM. The Neuralgias. In: Joynt RJ, Griggs RC, eds. Baker's Clinical Neurology. Baltimore: Lippincott Williams & Wilkins, 2001.
- Choi YK, Liu J. The use of 5% lidocaine for prolonged analgesia in chronic pain patients: A new technique. *Reg Anesth Pain Med* 1998;23:96-100.
- Kuhn WF, Kuhn SC, Gilberstadt H. Occipital neuralgias: Clinical recognition of a complicated headache. A case series and literature review. *J Orofac Pain* 1997;11:158-65.
- Poletti CE, Sweet WH. Entrapment of the C2 root and ganglion by the atlanto-epistropheic ligament: Clinical syndrome and surgical anatomy. *Neurosurgery* 1990;27:288-91.
- Lozano AM, Vanderlinden G, Bachoo R, Rothbart P. Microsurgical C-2 ganglionectomy for chronic intractable occipital pain. *J Neurosurg* 1998;89:359-65.
- Uematsu S. Percutaneous electrothermocoagulation of spinal nerve trunk, ganglion, and rootlets. In: Schmidek HH and Sweet WH, eds. *Operative Neurosurgical Techniques*. New York: Grune & Stratton, 1982:1177-98.
- Horowitz MB, Yonas H. Occipital neuralgia treated by intradural dorsal nerve root sectioning. *Cephalalgia* 1993;13:354-60.
- Magnusson T, Ragnarsson T, Bjornsson A. Occipital nerve release in patients with whiplash trauma and occipital neuralgia. *Headache* 1996;36:32-6.
- Stechison MT, Mullin BB. Surgical treatment of greater occipital neuralgia: An appraisal of strategies. *Acta Neurochir* 1994;131:236-40.
- Poletti CE. Proposed operation for occipital neuralgia: C-2 and C-3 root decompression. Case report. *Neurosurgery* 1983;12:221-4.
- Lozano AM, Vanderlinden G, Bachoo R, Rothbart P. Microsurgical C-2 ganglionectomy for chronic intractable occipital pain. *J Neurosurg* 1998;89:359-65.
- Weiner RL, Reed KL. Peripheral neurostimulation for control of intractable occipital neuralgia. *Neuromodulation* 1999;2:217-21.
- Sindou M, Fischer G, Mansuy L. Posterior spinal rhizotomy and selective posterior rhizotomy. *Prog Neurol Surg* 1976;7:201-50.
- Tasker RR. Neurological concepts of pain management in head and neck cancer. *Can J Otolaryngol* 1975;4:480-4.
- Friedman AH, Bullitt E. Dorsal root entry zone lesions in the treatment of pain following brachial plexus avulsion, spinal cord injury, and herpes zoster. *Appl Neurophysiol* 1988;51:164-9.
- Saris SC, Iacono RP, Nashold BS Jr. Dorsal root entry zone lesions for post-amputation pain. *J Neurosurg* 1985;62:72-6.
- Dubuisson D. Treatment of occipital neuralgia by partial posterior rhizotomy at C1-3. *J Neurosurg* 1995;82:581-6.
- Abele H, Pieper KS, Herrmann M. Morphological investigations of connective tissue structures in the region of the nervus occipitalis major. *Funct Neurol* 1999;14:167-70.
- Sindou M, Mifsud JJ, Boisson D, Goutelle A. Selective posterior rhizotomy in the dorsal root entry zone for treatment of hyperspasticity and pain in the hemiplegic upper limb. *Neurosurgery* 1986;18:587-95.
- Saris SC, Iacono RP, Nashold BS Jr. Microsurgical DREZotomy in treatment of deafferentation pain. In: Schmidek HM, Sweet WH, eds. *Operative Neurosurgical Techniques: Indications, Methods, and Results*. 3rd edn, vol 2. Philadelphia: WB Saunders Company, 1995:1623-36.